AJNR

MR evaluation of laryngohypopharyngeal cancer: value of gadopentetate dimeglumine enhancement.

F Sakai, S Sone, K Kiyono, A Maruyama, T Kawai, M Oguchi, Naoto-Shikama, I Izuno, J Aoki and H Ueda

AJNR Am J Neuroradiol 1993, 14 (5) 1059-1069
http://www.ajnr.org/content/14/5/1059

MR Evaluation of Laryngohypopharyngeal Cancer: Value of Gadopentetate Dimeglumine Enhancement

Fumikazu Sakai,[1] Shusuke Sone,[1] Kunihiro Kiyono,[1] Atsunori Maruyama,[1] Takashi Kawai,[1] Masahiko Oguchi,[1] Naoto-Shikama,[1] Itaru Izuno,[1] Jun Aoki,[1] Hitoshi Ueda,[1] Keiko Ishii,[2] and Kiichirou Taguchi[3]

PURPOSE: To investigate the value of gadopentetate dimeglumine-enhanced MR imaging in determining the extent of laryngohypopharyngeal cancer. **METHODS:** Unenhanced and contrast-enhanced T1-weighted, proton-density–weighted, and T2-weighted images from 24 patients with laryngohypopharyngeal cancer were reviewed and compared with the pathologic findings of resected specimens. In 18 patients, ex vivo MR images of the resected specimens were also compared with pathologic findings. **RESULTS:** Laryngohypopharyngeal cancer showed intermediate intensity on T1-weighted and proton-density–weighted images, high intensity on T2-weighted images, and moderate enhancement on T1-weighted enhanced images. Cartilage-invaded tumor enhanced moderately, whereas unossified cartilage in contact with tumors but without tumor invasion showed no enhancement. Laryngohypopharyngeal mucosa enhanced intensely; endolaryngeal muscles enhanced less. **CONCLUSIONS:** Enhanced MR images were more useful in assessing the extent of tumors and the presence of laryngeal cartilage invasion than were proton-density–weighted and T2-weighted images.

Index terms: Larynx, neoplasms; Pharynx, neoplasms; Magnetic resonance, contrast enhancement

AJNR 14:1059–1069, Sep/Oct 1993

Magnetic resonance (MR) imaging is helpful in determining the extent of laryngohypopharyngeal cancer (1–10). Cartilage invasion can be more clearly evaluated with MR images than with computed tomographic (CT) images (3, 5). Castelijns and coworkers advocated the use of T1-weighted images in combination with proton-density–weighted images to show cartilage invasion; T2-weighted images were less useful because of their low contrast-to-noise ratio and image degradation caused by patients' movement during the long acquisition time (3, 5, 9). Although several articles have appeared in the literature regarding MR imaging of the normal larynx and laryngohypopharyngeal cancer (1–10), the value of Gd-DTPA enhancement in laryngohypopharyngeal imaging has not yet been reported.

The purpose of this study was to investigate the value of Gd-DTPA enhancement in determining the extent of tumor, particularly cartilage invasion. We compared MR images of 24 patients who had laryngohypopharyngeal cancer to laryngoscopic findings, surgical records, macroscopic and microscopic findings, and MR images of the resected specimens, when available.

Subjects and Methods

Subjects

We studied MR images of 35 consecutive patients who were managed in our institution from June 1989 to December 1991 for previously untreated, histopathologically proved laryngohypopharyngeal cancer. One patient could not complete the MR examination because of claustrophobia and was excluded from the study group. In each patient, the first MR examination was performed before the initiation of preoperative radiation therapy in order to determine the initial extent of tumor. The second MR examination was performed after the completion of preoperative radiation therapy, within a week of surgery. A detailed comparison of the final MR images with pathologic specimens was

Received May 20, 1992; accepted after revision November 18.

[1] Departments of Radiology, [2]Laboratory Medicine, and [3]Otorhinopharyngolaryngology School of Medicine, Shinshu University, Asahi, Matsumoto, 390, Japan.

Address reprint requests to: Fumikazu Sakai, MD, Department of Radiology, School of Medicine, Shinshu University, Asahi, Matsumoto, 390, Japan.

AJNR 14:1059–1069, Sep/Oct 1993 0195-6108/93/1405–1059

performed. The histopathologic diagnosis of all tumors was squamous cell carcinoma with varying degrees of cellular differentiation. There were five patients with supraglottic, 12 patients with transglottic, and eight patients with glottic or subglottic laryngeal cancer, and nine patients with hypopharyngeal cancer.

Of the 34 patients, 24 (four with supraglottic, 11 with transglottic, three with glottic or subglottic, and six with hypopharyngeal cancer) underwent surgery after the preoperative radiation therapy (30 to 40 Gy for 3 to 4 weeks). Two patients with supraglottic cancers underwent supraglottic laryngectomy. Two patients with supraglottic, 11 with transglottic, three with glottic or subglottic, and four with hypopharyngeal cancer underwent total laryngectomy. Two patients with hypopharyngeal cancer were treated with laryngopharyngoesophagectomy. The remaining 10 patients were treated with radical or palliative radiation therapy because of the advanced nature of their tumors, the presence of early cancer confined to the vocal cords, refusal to undergo laryngectomy, and/or poor physical condition.

Imaging Technique

MR images were obtained with a 1.5-T imaging unit (GE, Milwaukee, WI) with either a 3- or 5-inch circular surface coil placed on the anterior aspect of the patient's neck. MR images included an axial T1-weighted spin-echo imaging sequence (600/20/2 repetition time/echo time/excitations) and proton-density–weighted and T2-weighted multiecho imaging sequences (2000/30 and 80/1, respectively). Coronal or sagittal T1-weighted and/or proton-density/T2-weighted multiecho imaging sequences were added when necessary. After the intravenous injection of Gd-DTPA (0.1 mmol/kg), T1-weighted images were obtained in the axial and coronal or sagittal planes. Other imaging parameters included an 16- to 24-cm field of view, a 4- to 6-mm section thickness with a 0.5- to 2-mm intersection gap, and 256 × 192 or 256 × 256 acquisition matrices.

The quality of MR images was evaluated by the consensus of two diagnostic radiologists. The images were classified into three categories: satisfactory, fair but still diagnostic, and nondiagnostic. The signal intensity of the individual tissues on MR images was classified into four degrees: signal void (indicating no signal), low intensity (equal to or less intense than skeletal muscle), intermediate intensity, and high intensity (equal to or more intense than fat).

Pathologic Material

In 18 patients (two with supraglottic, eight with transglottic, two with glottic, and six with hypopharyngeal cancers), MR images of the resected specimens were obtained by the use of T1-weighted (400 to 600/20/2 to 4) and T2-weighted (2000 to 3000/80 to 120/1 to 2) imaging sequences in the axial and coronal or sagittal planes with a 3-inch circular surface coil using the 1.5 imaging unit and/or a 2.0-T unit (GE, Fremont, CA). Scan planes were marked with surgical threads on specimens. MR images of some resected larynges were obtained after fixation in 10% formalin solution for 2 to 48 hours. After formalin fixation and decalcification, the specimens were cut in axial, coronal, or sagittal planes into 5- to 10-mm-thick sections. Photography and histopathologic staining were performed (11).

Results

Image quality

Precontrast and postcontrast T1-weighted images from 30 of 34 patients (87%) were of satisfactory quality and those from the remaining four patients (13%) showed fair image quality. Proton-density–weighted and T2-weighted images from 26 of the 34 patients (75%) were of satisfactory quality, three (9%) were of fair quality, and five (16%) were nondiagnostic. The main cause of image degradation was motion artifacts caused by swallowing or respiratory movement.

Signal intensity of normal structures and tumors of the larynx

The signal intensities of normal laryngeal structures and laryngohypopharyngeal cancer are summarized in Tables 1 and 2. The vocal cords showed a slightly higher signal intensity than skeletal muscle on T1-, proton-density–, and T2-weighted images because of the averaging of the low intensity of the thyroarytenoid muscles and the increased intensity of the mucosa (Table 1). Laryngeal cartilages showed variable signal intensities depending on the degree of ossification and amount of fatty bone marrow (Table 2). After the intravenous injection of Gd-DTPA, the laryngohypopharyngeal mucosa enhanced prominently. The vocal cords enhanced slightly more than skeletal muscle, probably because of the averaging of the thyroarytenoid muscles and the highly enhanced laryngeal mucosa. Unossified cartilage did not enhance (Table 1).

On T1- and proton-density–weighted images, laryngohypopharyngeal cancer showed an intermediate intensity, higher than skeletal muscle but lower than fat (Figs 1A and B, 2A and B, 3A and B, and 4A and B). On T2-weighted images, tumors showed an increased intensity, approximately equal to or higher than fat and slightly lower than or equal to the mucosa of the laryngohypopharynx (Figs 1C, 2C, 3C, and 4C). After the intravenous injection of Gd-DTPA, tumors enhanced moderately showing a higher intensity

TABLE 1: Signal intensities of laryngeal soft tissues[a]

	T1 Weighted	Proton-Density Weighted	T2 Weighted	Enhancement
Laryngohypopharyngeal mucosa	Intermed.	High	High	(+++)
False vocal cords	High	High	High	(*)
True vocal cords	Low(#)	Low(#)	Low(#)	(+)
Paralaryngeal space	High	High	High	(*)
Preepiglottic space	High	High	High	(*)
Tumor	Intermed.	Intermed.	High	(++) – (+++)

[a] True vocal cord (#) shows a slightly higher signal intensity than do skeletal muscles. Low, low intensity: Intermed., intermediate intensity; High, high intensity; –, no contrast enhancement; +, slight contrast enhancement; ++, moderate contrast enhancement; +++, marked contrast enhancement; * enhancement of false focal cord, paralaryngeal space, and preepiglottic space is masked by high intensity of fatty tissue.

TABLE 2: Signal intensities of laryngeal cartilages[a]

	T1 Weighted	Proton-Density Weighted	T2 Weighted	Enhancement
Unossified hyaline cartilage	Intermed.	Low	Low	(–)
Ossified hyaline cartilage				
Ossified shell	Void	Void	Void	(–)
Fatty bone marrow	High	High	High	(*)
Elastic cartilage	Intermed.	Low	Low	(–)
Tumor-invaded cartilage	Intermed.	Intermed.	High	(++)

[a] Void, signal void; *, enhancement of fatty bone marrow is masked by high intensity of fatty bone marrow on T1-weighted images. All other abbreviations are as defined in footnote to Table 1.

than skeletal muscle and true vocal cords and equal to or slightly less than mucosa. This permitted clearer separation of tumors from less enhanced skeletal muscle (Figs 1D, 2D, 3D, and 4D).

On the MR images taken after the completion of preoperative radiation therapy, the size of the tumors decreased as compared with the initial MR images (Figs 1D and E, 2D and F, and 4D and F). Eighteen of 24 tumors showed moderate to marked reduction in size (Figs 2C, D, and F, and 4D and F) and the remaining six showed a little reduction (Fig 2D and E). Residual tumor was shown in all 24 tumors after preoperative radiation therapy. There were no changes in the signal intensities or the degree of contrast enhancement of the tumors on any imaging sequence between preradiation and postradiation MR images (Figs 1D and E, 2C through F, and 4C through F).

Evaluation of intralaryngeal tumor extention

In the supraglottic regions, tumor extension into the preepiglottic or paralaryngeal spaces, normally occupied by fatty tissue, was clearly shown on T1-weighted images with abnormal intermediate-intensity tissue seen among the normal fatty tissue of high intensity (Fig 1A). Proton-density– and T2-weighted images provided no additional information to that of the T1-weighted images in the diagnosis of preepiglottic or paralaryngeal space invasion (Fig 1B and C). The tumor borders were not distinctly shown on proton-density– and T2-weighted images because of limited contrast between tumors and the false cords.

In the glottic and subglottic regions, tumors were depicted as asymmetries of the vocal cords or subglottic tissues (Fig 2A). On T2-weighted images, tumors showed high-intensity signals that were slightly lower than or equal to those of the mucosa and that permitted a clearer discrimination from endolaryngeal or extralaryngeal muscle than did T1- and proton-density–weighted images (Fig 2B and C). Transglottic extension was clearly shown on the coronal images (Fig 2G). Tumor extension was more clearly shown on enhanced images than on precontrast T1-weighted images and was equivalent to T2-weighted images when the T2-weighted images were not seriously degraded by motion artifacts.

Evaluation of cartilage invasion (Tables 2, 3)

On T1-weighted images, ossified cartilages containing fatty marrow could be easily differentiated from tumor-invaded cartilages or unossified

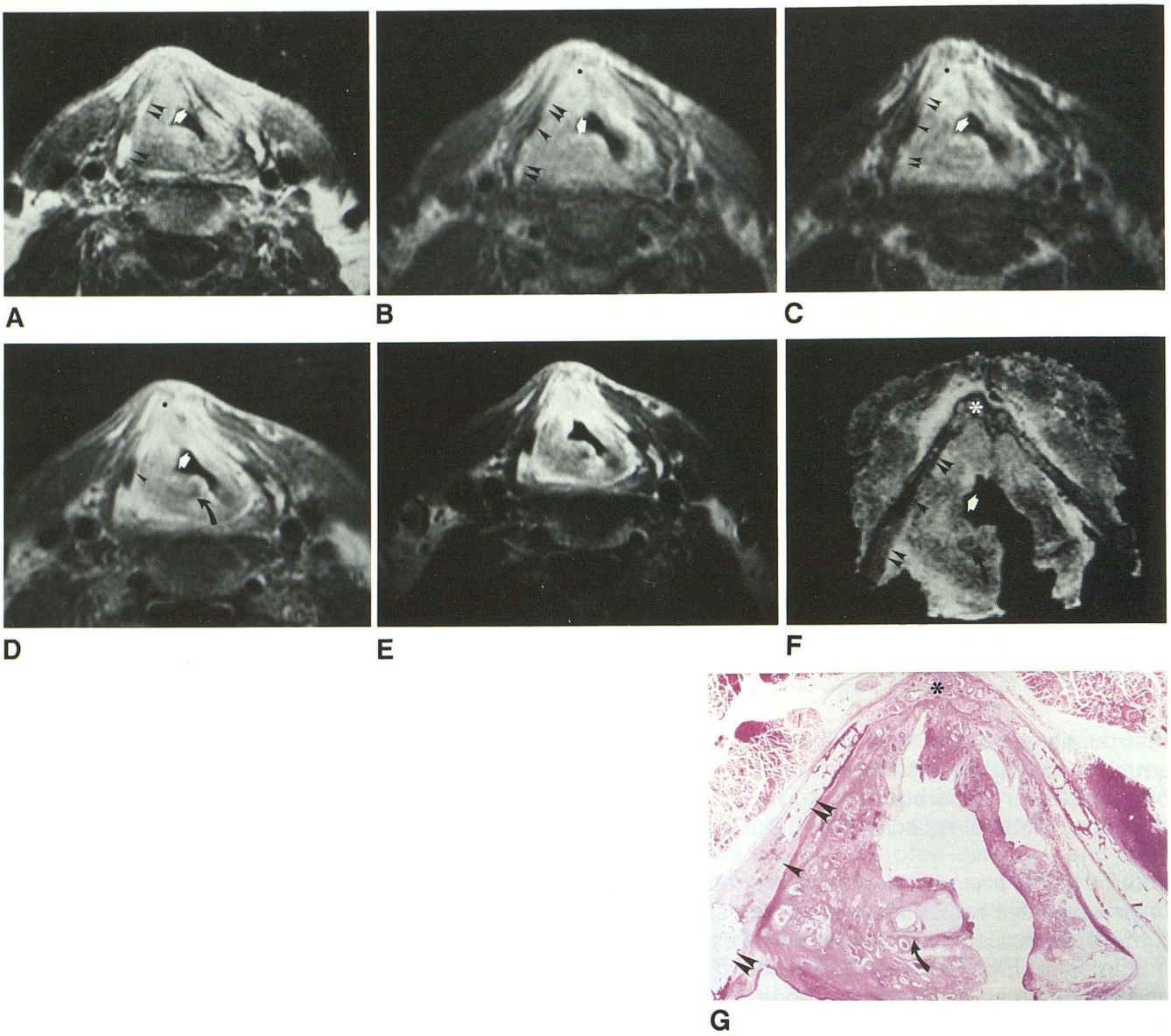

Fig. 1. A 59-year-old man with T4 laryngeal cancer showing thyroid and right arytenoid cartilage invasion. The patient underwent total laryngectomy after the preoperative radiation therapy (40 Gy for 4 weeks).

A, On T1-weighted (600/20) axial image at the level of the false cords before the initiation of preoperative radiation therapy, an intermediate-intensity mass occupies the right false cord (*arrow*). The mass extends to the right paralaryngeal space and the preepiglottic space. The contralateral paralaryngeal space shows normal fatty intensity. The midportion and posterior portion of the right thyroid lamina show a high intensity (*double arrowheads*). Other portions of the right thyroid lamina show an intermediate intensity. The right arytenoid cartilage cannot be identified as a distinct high-intensity area. Although motion artifacts degrade image quality, image quality is still diagnostic.

B, Proton-density–weighted (2000/30) axial image before the initiation of preoperative radiation therapy shows an intermediate-intensity mass occupying the right false cord (*arrow*). The anterior portion of the right thyroid lamina shows an intermediate intensity (*asterisk*). The midportion and posterior end of the right thyroid lamina show a high intensity (*double arrowheads*). Other portions of the right thyroid lamina are low in intensity (*arrowhead*). The right arytenoid cartilage cannot be identified, which suggests the tumor invasion to the right arytenoid cartilage. Motion artifacts degrade image quality, but the image quality is still diagnostic.

C, T2-weighted (2000/80) axial image before the initiation of preoperative radiation therapy shows a high-intensity mass occupying the right false cord (*arrow*). The anterior portion of the right thyroid lamina shows a high intensity (*asterisk*). The midportion and posterior end of the right thyroid lamina show a high intensity (*double arrowheads*). The other portions of the thyroid cartilage are low intensity (*arrowhead*). The right arytenoid cartilage cannot be identified, which suggests the tumor invasion to the right arytenoid cartilage. Image quality is only fair but is still diagnostic.

D, On an enhanced T1-weighted (600/20) axial image before the initiation of preoperative radiation therapy, the tumor shows moderate contrast enhancement (*arrow*). The anterior portion of the right thyroid lamina shows moderate contrast enhancement (*asterisk*). The portions of the right thyroid lamina showing low intensity on proton-density–weighted and T2-weighted images remains

cartilages, which had an intermediate intensity (Figs 1A and 2A). Tumor-invaded cartilages showed an intermediate intensity on proton-density–weighted images; high intensity on T2-weighted images could be separated from unossified cartilages, which showed a low intensity on proton-density– and T2-weighted images (Figs 1B and C, 2B and C, 3B and C, and 4B and C). On enhanced images, tumor-invaded cartilages showed moderate contrast enhancement, whereas unossified cartilages remained unenhanced (Figs 1D and F, 2D and F, 3D, and 4D and F) (Table 1).

With T1-weighted images, we were able to rule out cartilage invasion when a high-intensity fatty plane could be identified between the tumor and cartilage or when the high-intensity fatty marrow was preserved in the ossified cartilages. A combination of T1- and proton-density–weighted images, T1- and T2-weighted images, or enhanced and unenhanced T1-weighted images was required to make a definitive diagnosis of cartilage invasion.

In summary, the combination of T1-weighted images and enhanced images showed the presence or absence of cartilage invasion more clearly than the combination of T1- and proton-density– or T1- and T2-weighted images. On pathologic specimens, invasion of the cartilage was seen in eight thyroid cartilages, four cricoid cartilages, five arytenoid cartilages, and nine epiglottic cartilages. The combination of T1- and proton-density– or T1- and T2-weighted images showed five of eight thyroid cartilage invasions, all four cricoid cartilage invasions, three of five arytenoid cartilage invasions, and seven of nine epiglottic cartilage invasions. False-negative results were the result of poor image quality of proton-density– and T2-weighted images in two of three thyroid cartilage invasions and in one of two arytenoid cartilage invasions. The remaining two, each of thyroid cartilage and arytenoid cartilage invasion, were missed because of limited cartilage invasion confined to the ossified shell (Fig 2I). With the combination of T1- and proton-density–weighted images or T1- and T2-weighted images, three of 16 intact thyroid cartilages, two of 20 intact cricoid cartilages, four of 43 intact arytenoid cartilages, and four of 15 intact epiglottic cartilages could not be definitively evaluated as intact because of the poor image quality of the proton-density– and T2-weighted images.

On the other hand, the combination of enhanced and unenhanced T1-weighted images showed seven of eight thyroid cartilage invasions, all four cricoid cartilage invasions, four of five arytenoid cartilage invasions, and all nine epiglottic cartilage invasions. The combination of preenhanced and postenhanced T1-weighted images missed one of eight thyroid cartilage invasions and one of five arytenoid cartilage invasions because of limited cartilage invasion. The combination of T1-weighted images showed all 16 intact thyroid, 20 intact crocoid, 43 intact arytenoid, and 15 intact epiglottic cartilages as intact.

Evaluation of extralaryngeal and extrapharyngeal invasion

Extralaryngeal invasion was shown in five of 18 laryngeal cancers. One laryngeal cancer penetrated the thyrohyoid membrane, and one penetrated the cricothyroid membrane. One tumor showed extralaryngeal invasion through both the thyrohyoid membrane and the upper portion of the thyroid lamina. The remaining two tumors showed invasion beyond the thyroid cartilage: one showed invasion to the anterior aspect of the neck, and the other invaded the anterolateral aspect of the neck. Extrapharyngeal invasion was

unenhanced (*arrowhead*). In the posterior portion of the right false cord, a region without contrast enhancement surrounding moderate contrast enhancement is seen (*curved arrow*).

E, Enhanced T1-weighted (600/20) image after the completion of preoperative radiation therapy shows a slight decrease the size of the moderately enhancing tumor. Degree and extent of enhancement are not changed as compared with pretreatment scan (D).

F, T2-weighted (2000/80) axial image of the resected specimen shows a high-intensity mass occupying the right false cord (*arrow*). The anterior portion of the right thyroid lamina shows high intensity (*asterisk*). The midportion and posterior end of the right thyroid lamina show high intensity (*double arrowheads*). The other portions of the right thyroid lamina are low intensity (*arrowhead*). A high-intensity region is noted in the posterior portion of the right false vocal cord (*curved arrow*).

G, Histopathologic specimen shows cornified squamous cell carcinoma occupying the right false cord with extension to the right paralaryngeal and preepiglottic spaces (*arrow*). The anterior portion of the thyroid cartilage is invaded by the tumor (*asterisk*). The portion of the right thyroid lamina that shows low intensity on proton-density–weighted and T2-weighted images and lack of contrast enhancement on enhanced images corresponds to unossified cartilage (*arrowhead*). The portions of the thyroid lamina that show a high intensity on T1-weighted and T2-weighted images correspond to fatty marrow within ossified cartilage (*double arrowheads*). The region in the posterior portion of the right false cord, which shows moderate contrast enhancement surrounded by an unenhanced region on enhanced images, corresponds to the tumor-invaded arytenoid cartilage surrounded by unossified cartilage (*curved arrow*).

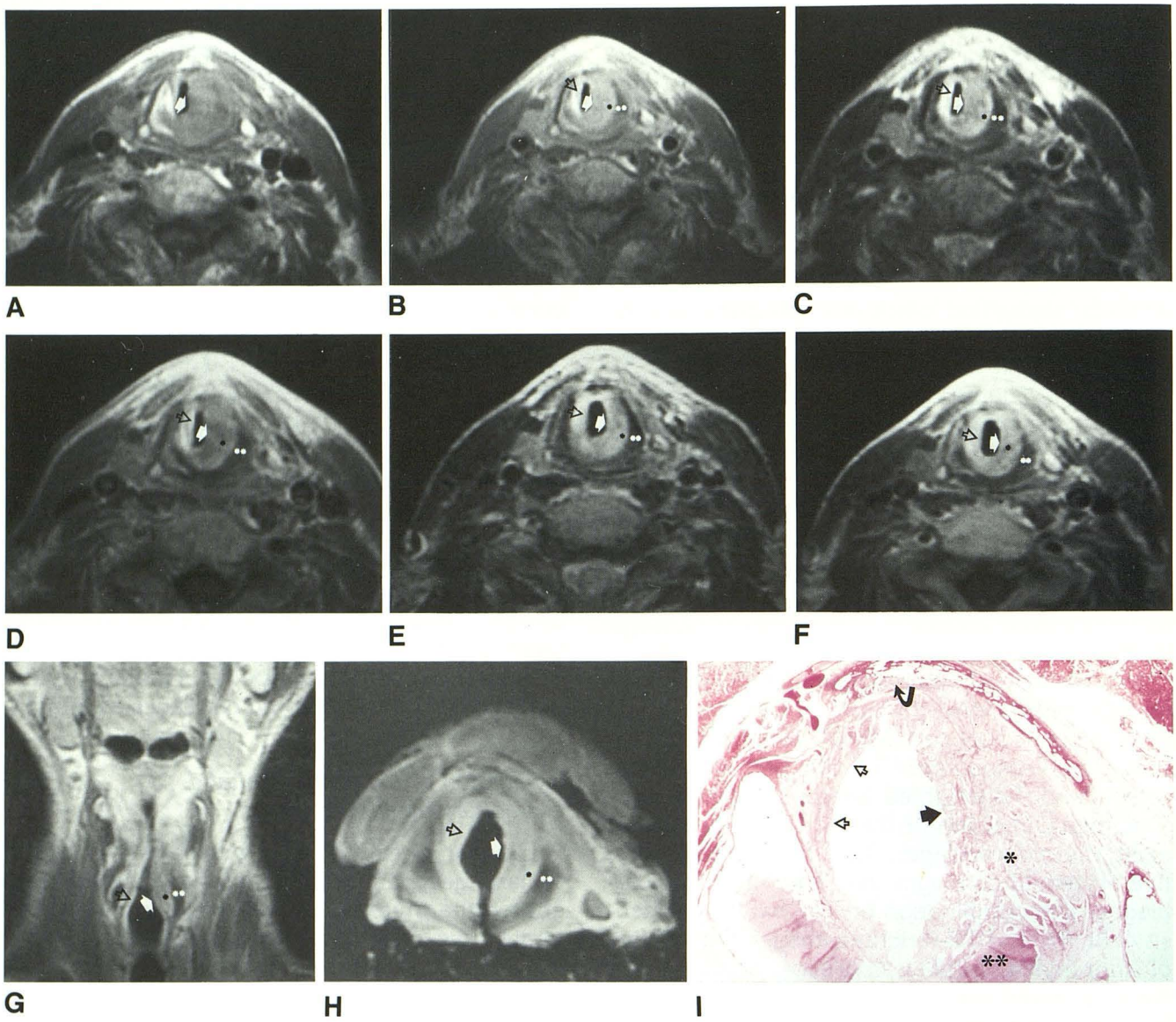

Fig. 2. A 56-year-old patient with T4 transglottic cancer showing apparent cricoid cartilage invasion and a limited invasion to the lower edge of the thyroid cartilage. The patient underwent total laryngectomy after the preoperative radiation therapy (32 Gy for 3 weeks).

A, T1-weighted (600/20) axial image at the level of the subglottic region before the initiation of preoperative radiation therapy shows an intermediate-intensity mass (*arrow*) in the left aspect of the subglottic region. Disappearance of high-intensity fatty marrow in the left aspect of the cricoid lamina suggests cricoid cartilage invasion of the tumor. However, the extent of cartilage invasion is unclear on the T1-weighted image.

B, Proton-density–weighted (2000/30) axial image at the level of the subglottic region before the initiation of preoperative radiation therapy shows an intermediate-intensity mass (*arrow*) located in the left aspect of the subglottic region. The remaining portion (*open arrow*) in the right aspect shows a higher intensity than that of the left aspect. The medial portion of the cricoid cartilage shows intermediate intensity (*asterisk*); however, the remaining portion shows low intensity (*double asterisks*).

C, T2-weighted (2000/80) axial image at the level of the subglottic region before the initiation of preoperative radiation therapy shows a high-intensity mass (*arrow*) located in the left aspect of the subglottic space. The remaining portion (*open arrow*) in the right aspect shows a higher intensity than the left aspect. The medial portion of the cricoid cartilage shows high intensity (*asterisk*), whereas the remaining portion shows low intensity (*double asterisks*).

D, Enhanced T1-weighted (600/20) axial image at the level of the subglottic region before the initiation of preoperative radiation therapy shows moderate contrast enhancement (*arrow*) in the left aspect of the subglottic space. The remaining portion (*open arrow*) in the right aspect shows more prominent contrast enhancement than the left aspect. The medial portion of the left cricoid lamina shows moderate contrast enhancement (*asterisk*), whereas the remaining portion shows lack of contrast enhancement (*double asterisks*).

E, T2-weighted (2000/80) axial image at the level of the subglottic region after the completion of preoperative radiation therapy shows moderately decreased size of the tumor. However, the signal intensity of the tumor is not changed as compared with the preradiation image (*C*).

shown in three of six hypopharyngeal cancers—two to the cervical esophagus and one through the thyrohyoid membrane and pharyngeal constrictor muscle to the soft tissues of the neck.

In six of eight tumors, extralaryngeal or extrapharyngeal invasion was shown as high intensity on T2-weighted images (Fig 3A through C). However, two extralaryngeal or extrapharyngeal invasions were not so clearly shown on T2-weighted images because of poor image quality. Enhanced images showed all eight extralaryngeal or extrapharyngeal invasions as moderately enhancing mass lesions (Fig 3*D* through *F*). Invasion of hypopharyngeal tumors into the cervical esophagus was clearly shown on enhanced sagittal images. In two laryngeal tumors with invasion penetrating the thyroid lamina and one hypopharyngeal tumor with invasion penetrating the thyrohyoid membrane and pharyngeal constrictor muscle, the extent of invasion was overestimated on T2-weighted and enhanced images. The extent of extralaryngeal or extrapharyngeal growth shown on enhanced images was nearly the same as that seen on T2-weighted images when the image quality of the T2-weighted images was diagnostic.

Discussion

Accurate determination of tumor extent is mandatory for treatment planning in laryngohypopharyngeal cancer. For supraglottic laryngectomy, the tumor must not cross the laryngeal ventricle. Vertical hemilaryngectomy for glottic cancers is contraindicated when there is significant subglottic extension, arytenoid cartilage involvement, deep growth at the anterior commissure, and/or false cord invasion. It is also important to identify the presence of hyaline cartilage invasion (thyroid, cricoid, and arytenoid cartilages), because cartilage invasion is usually thought to be an indication for total laryngectomy rather than for partial laryngectomy. Moreover, radiation therapy in cases with invasion of thyroid cartilage may cause serious complications such as chondronecrosis. High recurrence rates follow radiation therapy in cases with occult invasion to thyroid, cricoid, and arytenoid cartilages (3).

Castelijns and coworkers (5) advocate the use of T1-weighted images in conjunction with proton-density–weighted images to evaluate cartilage invasion because T1-weighted images are effective in differentiating fatty marrow in the ossified cartilage from tumor-involved cartilage and because proton-density–weighted images allow discrimination of normal unossified cartilage.

Castelijns and coworkers discarded T2-weighted images with a 0.6-T superconductive unit because of image degradation (5). Although T2-weighted images are more effective in delineating the extent of tumor than are T1- or proton-density–weighted images, T2-weighted images are limited in their effectiveness in the imaging of laryngohypopharyngeal cancer because of motion artifacts and a low contrast-to-noise ratio (5, 9). Fast spin-echo techniques, when available, might be a promising substitute for conventional spin-echo techniques by reducing acquisition time and motion artifacts (12, 13).

Gd-DTPA–enhanced MR imaging may be an important adjunct to or substitute for the proton-density– and T2-weighted images in the study of laryngohypopharyngeal cancers, as has been demonstrated in the study of sinonasal diseases (14). Gd-DTPA–enhanced T1-weighted images show many advantages over T2-weighted images. Enhanced T1-weighted images provide a better signal-to-noise ratio, fewer motion arti-

F, Enhanced T1-weighted (600/20) axial image at the level of the subglottic region after the completion of preoperative radiation therapy shows decreased size of the tumor. However, the degree and pattern of contrast enhancement are not changed as compared with the preradiation image (D).

G, Enhanced T1-weighted (600/20) coronal image after the completion of preoperative radiation therapy shows transglottic extension of a moderately enhanced mass (*arrow*). Normal laryngeal mucosa shows more prominent enhancement (*open arrow*) than the tumor. The cranial portion of the cricoid cartilage shows moderate contrast enhancement (*asterisk*).

H, T2-weighted (2000/80) axial image of the resected specimen shows a high-intensity mass occupying the left aspect of the subglottic space (*arrow*). The remaining portion shows higher intensity than the mass (*open arrow*). The medial portion of the cricoid cartilage shows high intensity (*asterisk*), whereas the remaining portion shows low intensity (*double asterisks*).

I, Histolopathologic specimen at the level of the subglottic region (axial plane) shows a squamous cell carcinoma occupying the left aspect of the subglottic space. The region showing a relatively high intensity on T2-weighted images and moderate contrast enhancement on enhanced T1-weighted images corresponds to cancer tissue (*arrow*). The region that shows higher intensity on T2-weighted images and more prominent contrast enhancement on enhanced T1-weighted images than the tumor corresponds to noncancerous laryngeal mucosa (*open arrow*). The medial portion of the cricoid cartilage with moderate contrast enhancement corresponds to tumor-involved cartilage (*asterisk*). The nonenhanced portion of the cricoid cartilage corresponds to the unossified portion (*double asterisks*). The tumor invades to the lower edge of the thyroid lamina (*curved arrow*), which cannot be identified on MR images.

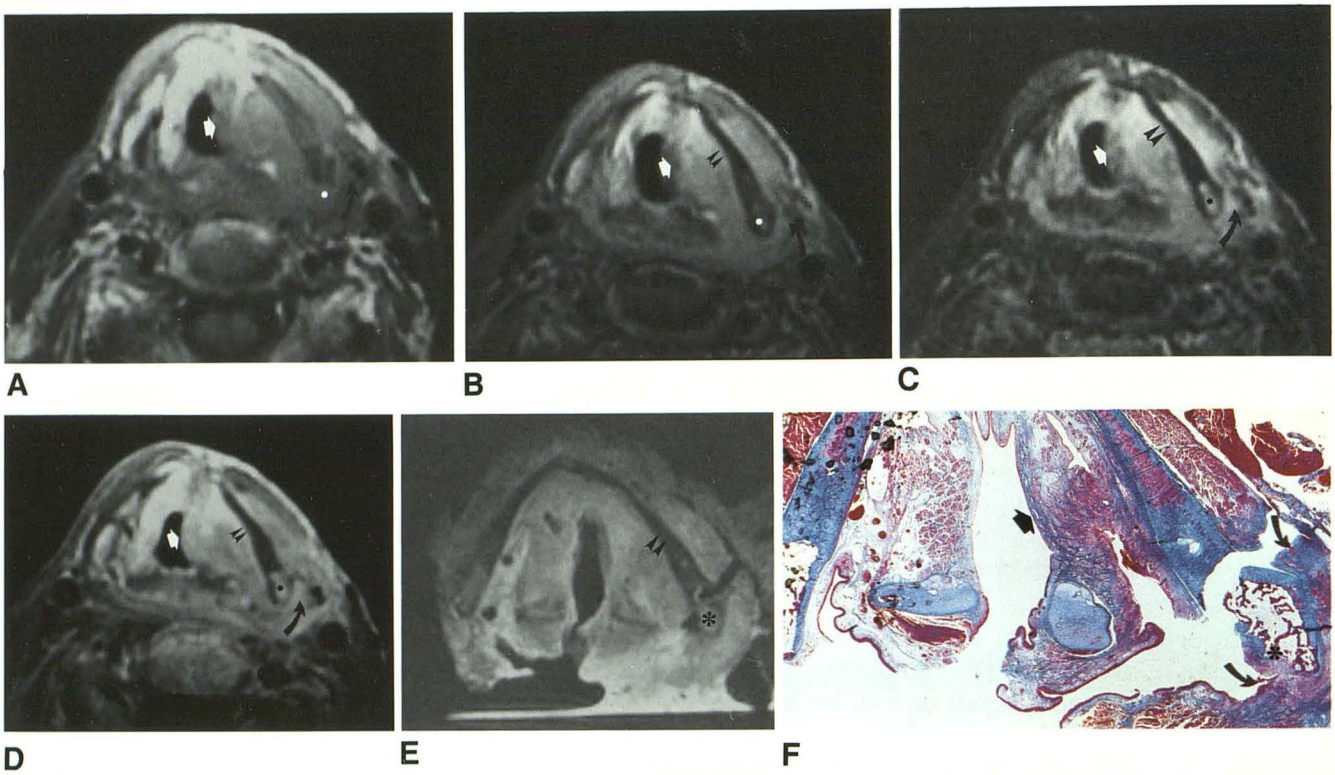

Fig. 3. A 75-year-old man with T4 hypopharyngeal cancer showing extrapharyngeal invasion and cartilage invasion to the posterior end of the left thyroid lamina. MR images taken after the completion of preoperative radiation therapy (32 Gy for 4 weeks) showed a little reduction of mass size (not shown). The signal intensity of the tumor and the degree of contrast enhancement of the tumor are not changed after the completion of preoperative radiation therapy.

A, T1-weighted (600/20) axial image at the level of the false cords before the initiation of preoperative radiation therapy shows that an intermediate-intensity mass of the left pyriform sinus invades the left paralaryngeal space (*arrow*). The intermediate-intensity mass extends into the soft tissues of the neck in the posterior and lateral aspects, compressing and penetrating pharyngeal constrictor muscles (*curved arrows*). The tumor surrounds the posterior end of the left thyroid lamina (*asterisk*). The signal intensity of the left thyroid lamina is intermediate.

B, Proton-density–weighted (2000/30) axial image at the level of the false cords before the initiation of preoperative radiation therapy shows an intermediate-intensity mass in the left pyriform sinus extending into the left paralaryngeal space (*arrow*). Soft tissues of the neck show an intermediate intensity in the posterior and lateral aspects of the hypopharynx (*curved arrow*). The posterior portion of the left thyroid lamina shows intermediate intensity (*asterisk*), whereas the remaining portion shows a low intensity (*double arrowheads*).

C, T2-weighted (2000/80) axial image at the level of the false cords before the initiation of preoperative radiation therapy shows a high-intensity mass in the left pyriform sinus extending into the left paralaryngeal space (*arrow*). The mass extends into the soft tissues of the neck, compressing and penetrating pharyngeal constrictor muscle (*curved arrow*). The posterior portion of the left thyroid lamina is of high intensity (*asterisk*), whereas the remaining portions are of low intensity (*double arrowheads*).

D, On enhanced T1-weighted (600/20) axial image at the level of the false cords before the initiation of preoperative radiation therapy, the tumor in the left pyrifrom sinus extending into the left paralaryngeal space has moderate contrast enhancement (*arrow*). The posterior portion of the left thyroid lamina has moderate contrast enhancement (*asterisk*), whereas the remaining portion does not contrast enhance (*double arrowhead*). Moderate contrast enhancement is seen in the neck soft tissue in the posterior and lateral aspects of the hypopharynx (*curved arrow*).

E, T2-weighted (2000/80) axial image of the resected specimen. The posterior portion of the left thyroid lamina has high signal intensity (*asterisk*), whereas the remaining portion is of low intensity (*arrowhead*). The mass is of high intensity (*arrow*).

F, Histopathologic specimen shows that squamous cell carcinoma of the left pyriform sinus extends into the paralaryngeal space (*arrow*). The posterior end of the left thyroid lamina is invaded with fibrotic changes of bone marrow (*asterisk*). Extrapharyngeal growth into the soft tissues of the neck is seen in the posterior and lateral portions (*curved arrow*). Extrapharyngeal invasion is compressing and penetrating pharyngeal constrictor muscle. Extrapharyngeal invasion into the neck soft tissue corresponds to high intensity on T2-weighted images and moderate contrast enhancement on enhanced images. Comparison of MR images with pathologic specimens shows that the extent of extrapharyngeal invasion is overdiagnosed with proton-density–weighted, T2-weighted, and enhanced MR images.

facts, and a shorter acquisition time than do T2-weighted images. Gd-DTPA–enhanced images show prominent contrast enhancement of the mucosa of the laryngohypopharynx and moderate enhancement of tumor with signal intensity higher than that of endolaryngeal muscle and

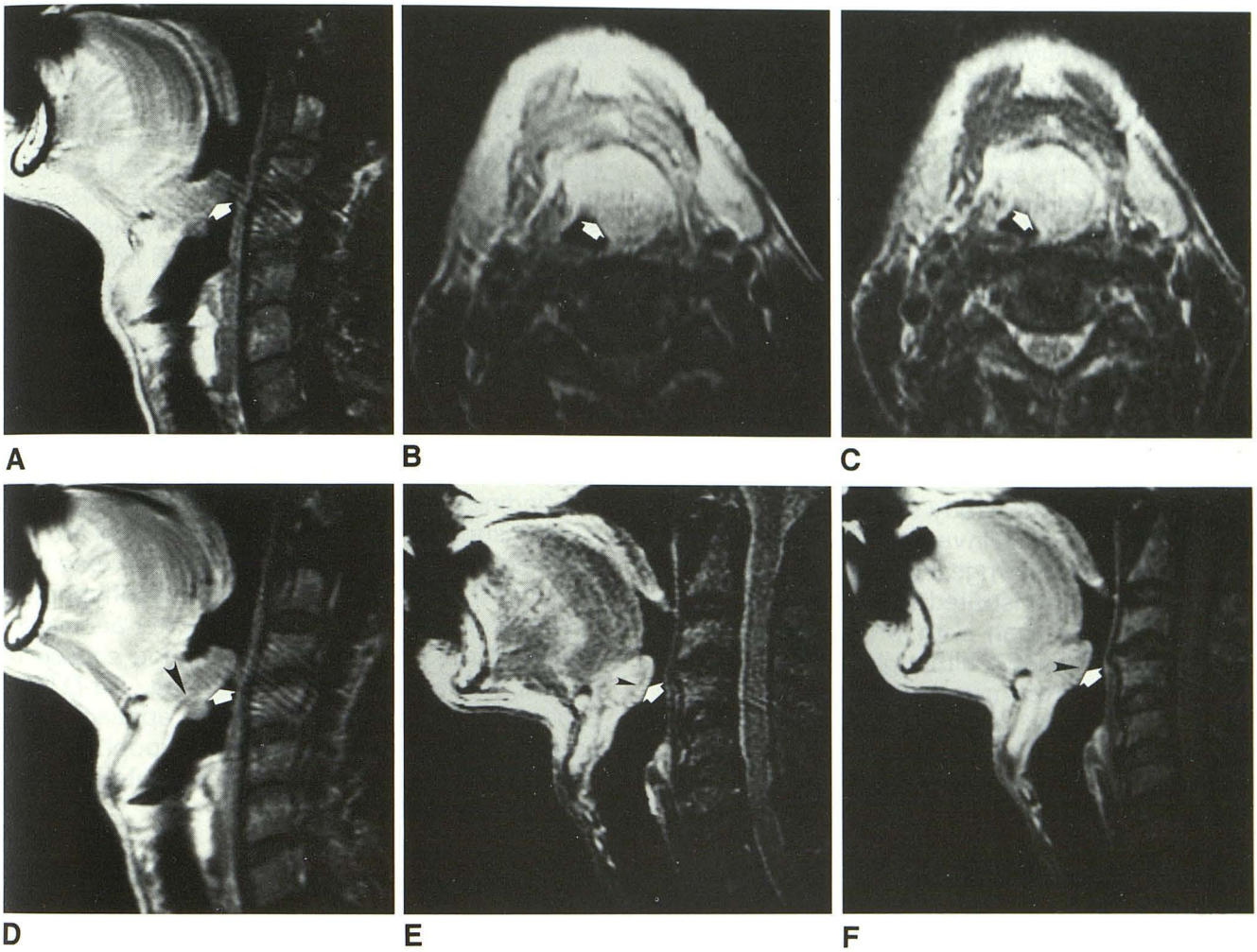

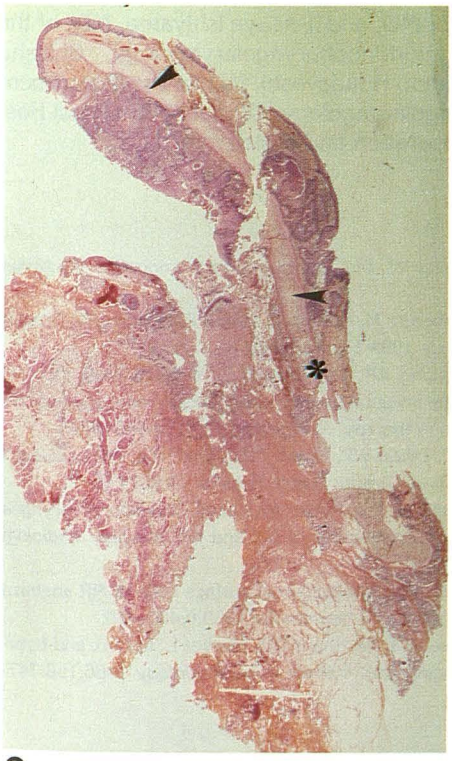

Fig. 4. A 56-year-old patient with T2 epiglottic cancer. The patient underwent supraglottic laryngectomy after the preoperative radiation therapy (36 Gy for 4 weeks).

A, T1-weighted (600/20) sagittal image before the initiation of preoperative radiation therapy shows an intermediate-intensity mass of the epiglottis (*arrow*). The mass invades to the tongue root and preepiglottic space.

B, Proton-density–weighted (2000/30) axial image at the level of the hyoid bone before the initiation of preoperative radiation therapy shows an intermediate-intensity mass (*arrow*) of the epiglottis. The epiglottic cartilage cannot be identified.

C, T2-weighted (2000/80) axial image at the level of the hyoid bone before the initiation of preoperative radiation therapy shows a high-intensity mass (*arrow*) of the epiglottis. The epiglottic cartilage cannot be identified.

D, Enhanced T1-weighted (600/20) sagittal image before the initiation of preoperative radiation therapy shows moderate contrast enhancement (*arrow*) of the mass. Although the proximal portion of the epiglottic cartilage remains unenhanced (*arrowhead*), the distal portion is involved by tumor and cannot be identified.

E, T2-weighted (2000/80) sagittal image after the completion of preoperative radiation therapy shows moderate reduction of tumor size. The signal intensity of the tumor is inhomogeneously high (*arrow*). The tumor surrounds a linear hypointensity (*arrowhead*).

F, Enhanced T1-weighted (600/20) sagittal image after the completion of preoperative radiation therapy shows moderate contrast enhancement of the tumor (*arrow*). The unenhanced linear structure is noted (*arrowhead*).

G, Histopathologic specimen shows a squamous cell carcinoma surrounding the epiglottic cartilage (*arrowheads*). Microscopic invasion to the epiglottic cartilage is seen. Linear structure showing a low intensity on T2-weighted images and lack of contrast enhancement corresponds to uninvolved epiglottic cartilage (*arrowheads*).

lower than or close to that of the mucosa of the laryngohypopharynx. Our results indicate that Gd-DTPA–enhanced imaging is effective and provides superior or nearly equivalent information to proton-density– and T2-weighted images in the evaluation of the extent of tumors. Cartilage invasion was clearly shown with the use of precontrast and postcontrast T1-weighted images, offering an alternative to time-consuming proton-density– or T2-weighted images. However, limited invasion confined to the shell of ossified cartilages was missed with all imaging sequences.

Laryngohypopharyngeal cancer may extend to extralaryngeal or extrapharyngeal soft tissue of the neck through the thyrohyoid membrane, cricothyroid membrane, or thyroid cartilage (11). Eight tumors in this study showed extralaryngeal or extrapharyngeal invasion. The presence or absence of extralaryngeal or extrapharyngeal invasion was demonstrated more clearly with enhanced images than with proton-density– and T2-weighted images, although the extent of invasion was overestimated with these MR images. This is because edematous and/or fibrotic changes around tumors showed the same signal intensity as did the tumor itself on T1- proton-density–, and T2-weighted images and moderate contrast enhancement on enhanced images.

We compared MR images taken after the preoperative radiation therapy with pathologic findings and MR images taken from resected specimens. Regions with a moderate intensity on T1-weighted images, a high intensity on T2-weighted images, and moderate contrast enhancement on enhanced images corresponded to tumor tissues intermingled with fibrotic changes, the latter probably caused by radiation therapy. By comparison study of MR images taken before and after the preoperative radiation therapy, we noted a reduction in the tumor size but not in the signal intensity of the tumor. This may be explained by the presumption that fresh fibrotic tissue has high intensity and can not be differentiated from tumor tissue on T2-weighted images, as has been proved in female pelvic cancers (15). Regions showing moderate intensity on T1-weighted images, high intensity on T2-weighted images, and moderate contrast enhancement probably correspond to tumor tissue on preradiation MR images. Limited invasion to cartilages or extralaryngeal soft tissues might be missed on preoperative MR images.

In conclusion, Gd-DTPA–enhanced T1-weighted images clearly demonstrated many of the findings shown on pathologic specimens and proved superior to proton-density–weighted and T2-weighted images in defining the extent of tumor and cartilage invasion in laryngohypopharyngeal cancer. Because of the shorter acquisition time and reduced image degradation caused by patient movement during scanning, Gd-DTPA–enhanced T1-weighted imaging appears more useful in the diagnosis of laryngohypopharyngeal cancer than do proton-density–weighted and T2-weighted images.

TABLE 3: Accuracy of diagnosis of laryngeal cartilage invasion

Pathologic Diagnosis	Imaging Sequences[a]	No. of Correct Diagnosis in Cartilage			
		Thyroid	Cricoid	Arytenoid	Epiglottic
Positive invasion	Pre-T1/PD	5/8	4/4	3/5	7/9
	Pre-T1/T2	5/8	4/4	3/5	7/9
	Pre-T1/Post-T1	7/8	4/4	4/5	9/9
Negative invasion	Pre-T1/PD	13/16	16/20	38/43	11/15
	Pre-T1/T2	13/16	16/20	38/43	11/15
	Pre-T1/Post-T1	16/16	20/20	40/43	15/15

[a] Pre-T1/PD, the combination of precontrast T1-weighted images and proton-density–weighted images; Pre-T1/T2, the combination of precontrast T1-weighted images and T2-weighted images; Pre-T1/Post-T1, the combination of precontrast T1-weighted images and postcontrast T1-weighted images.

Acknowledgments

We thank Kumiko Moriya, MD, of the Department of Radiology, National Matsumoto Hospital; Yasushi Nomura, MD, Akinobu Goto, MD, and Tetsuya Ishiyama, MD, of the Department of Otorhinopharyngolaryngology, Shinshu University; and Minato Hirabayashi, MD, of the Department of Otorhinopharyngolaryngology, Ohmachi Municipal Hospital, for their cooperation and assistance.

References

1. Curtin HD. Imaging of the larynx: current concepts. *Radiology* 1989;173:1–11
2. Kikinis R, Wolfensberger M, Boesch C, Martin E. Larynx: MR imaging at 2.35 T. *Radiology* 1989;171:165–169
3. Castelijns JA, Golding RP, van Schaik C, Valk J, Snow GB. MR findings of cartilage invasion by laryngeal cancer: value in predicting outcome of radiation therapy. *Radiology* 1990;174:669–674
4. Sakai F, Gamsu G, Dillon WP, Lynch DA, Gilbert TJ. MR imaging of the larynx at 1.5 T. *J Comput Assist Tomogr* 1990;14:60–71
5. Castelijns JA, Gerritsen GJ, Kaiser MC, et al. Invasion of laryngeal cartilage by cancer: comparison of CT and MR imaging. *Radiology* 1987;166:199–206
6. Lufkin RB, Hanafee WN. Application of surface coils to MR anatomy of the larynx. *AJNR: Am J Neuroradiol* 1985;6:491–497
7. Lufkin RB, Hanafee WN, Wortham DG, Hoover L. Larynx and hypopharynx: MR imaging with surface coils. *Radiology* 1986;158:747–754

8. Castelijns JA, Gerritsen GJ, Kaiser MC, et al. MRI of normal and cancerous laryngeal cartilage: histopathologic correlation. *Laryngoscope* 1987;97:1085–1093
9. Castelijns JA, Kaiser MC, Valk J, Gerritsen GJ, van Hattum AH, Snow GB. MR imaging of laryngeal cancer. *J Comput Assist Tomogr* 1987;11:134–140
10. McArdle CB, Bailey BJ, Amparo EG. Surface coil MR imaging of the normal larynx. *Arch Otolaryngol* 1986;112:616–622
11. Lam KH. Extralaryngeal spread of cancer of the larynx: a study with whole-organ section. *Head Neck Surg* 1983;5:410–424
12. Henning J, Nauerth A, Freidburg H. RARE imaging: a fast imaging method for clinical MR. *Magn Reson Med* 1986;3:823–833
13. Feinberg DA, Oshio K. GRASE (gradient- and spin-echo) MR imaging: a new fast clinical imaging technique. *Radiology* 1991;181:597–602
14. Robinson JD, Crawford SC, Teresi LM, et al. Extracranial lesions of the head and neck: preliminary experience with Gd-DTPA enhanced MR imaging. *Radiology* 1989;172:165–170
15. Ebner F, Kressel HY, Mintz MC, et al. Tumor recurrence versus fibrosis in the female pelvis: differentiation with MR imaging at 1.5 T. *Radiology* 1988;166:333–340