AJNR

Cerebellar arteries originating from the internal carotid artery.

M Siqueira, R Piske, M Ono and R Marino Júnior

AJNR Am J Neuroradiol 1993, 14 (5) 1229-1235
http://www.ajnr.org/content/14/5/1229

This information is current as of October 11, 2024.

Cerebellar Arteries Originating from the Internal Carotid Artery

Mario Siqueira,[1] Ronie Piske,[2] Michio Ono,[3] and Raul Marino, Jr.[1,3]

PURPOSE: To study the incidence of cerebellar arteries originating directly from the internal carotid artery, and to discuss the probable embryological origin and clinical implications of this anatomical anomaly. **METHODS:** We reviewed 5500 angiographic studies done at our institution in the last 4 years, searching for these anomalous vessels as well as for other anatomical variants. **RESULTS:** Eleven cerebellar arteries originating directly from the internal carotid artery and nine embryonic cerebral arteries were found. **CONCLUSION:** These arteries are considered persistent trigeminal artery variants and seem to occur as the result of the persistence of a primitive trigeminal artery associated with an incomplete fusion of the longitudinal neural arteries. These anomalous vessels are clinically significant particularly becuase of their role in endovascular therapeutic and surgical complications and the paradoxical lesions in the cerebellum that occur as a result of carotid disease.

Index terms: Arteries cerebellar; Arteries, trigeminal; Arteries, abnormalities and anomalies; Arteries, anatomy; Arteries, carotid (internal); Cerebral angiography

AJNR 14:1229–1235,Sep/Oct 1993

There are four embryonic cerebral arteries that directly connect the carotid and basilar arterial systems: the trigeminal, the otic, the hypoglossal, and the proatlantal. The one that persists most frequently in adults is the primitive trigeminal artery, occurring with an incidence of 0.2% in cerebral angiograms (1).

Unlike those arteries that have a direct communication with the basilar artery, there are case reports in the literature of direct anastomosis between the intracranial internal carotid artery and the cerebellar arteries, without the interposition of the basilar artery. These arteries are considered persistent trigeminal artery variants (2).

In this study we present a series of 10 patients bearing 11 of these anomalous arteries, discuss their probable embryological origin, and emphasize clinical implications.

Materials and Methods

We reviewed cerebral angiographic studies, searching for examples of cerebellar artery arising from the intracranial internal carotid artery and other anatomic variations. Five thousand five hundred consecutive angiographic studies done in a period of more than 4 years (from September 1986 to January 1991) were analyzed.

The clinical indications for the angiographic studies varied, most having been done for the investigation of intracranial hemorrhage, ischemic cerebrovascular disease, vascular lesions (arteriovenous malformation), and tumors.

The examinations were performed through percutaneous transfemoral catheterization by a vascular neuroradiologist (R.P.) on high resolution digital angiographic equipment. Except in the presence of severe atheromatous disease, the injections of contrast material in the carotid system were performed via the internal carotid artery. Using local anesthesia and nonionic contrast material, the internal and external carotid selective studies were done with a 4F catheter; the common carotid artery injections were performed through a 5F catheter.

Results

In 10 patients we found 11 anomalous origins of cerebellar arteries directly from the intracranial internal carotid artery (0.18% of the angiographic

Received July 7, 1992; revision requested September 3, received October 27, and accepted November 6.

[1] Division of Neurosurgery, Sao Paulo University Medical School, Sao Paulo, Brazil.

[2] Section of Vascular Neuroradiology, Med Imagem/Hospital Beneficencia Portuguesa de Sao Paulo, Sao Paulo, Brazil.

[3] Sao Paulo Neurological Institute/Hospital Beneficencia, Portuguesa de Sao Paulo, Sao Paulo, Brazil.

[4] Address correspondence and reprint requests to Dr Mario Siqueira, Rua Virgilio de Carvalho Pinto, 381/apartment 42, 05415 Sao Paulo—SP, Brazil.

AJNR 14:1229–1235, Sep/Oct 1993 0195-6108/93/1405–1229
© American Society of Neuroradiology

studies). These arteries presented a course and distribution similar to the normal cerebellar arteries: three (two of the same patient) were similar to superior cerebellar arteries (Fig 1); three were identical to anterior-inferior cerebellar arteries (Fig 2); and five were similar to posterior-inferior cerebellar arteries (Fig 3).

There were nine embryonic cerebral arteries found in this series (0.16% of the angiographic studies) distributed in the following way: six primitive trigeminal arteries; two hypoglossal arteries, and one proatlantal artery.

Discussion

Internal carotid origin of cerebellar arteries was reported by Teal et al in 1972 (2). The level of the internal carotid artery from which these vessels took origin led to the conclusion that they were primitive trigeminal artery variants. In a

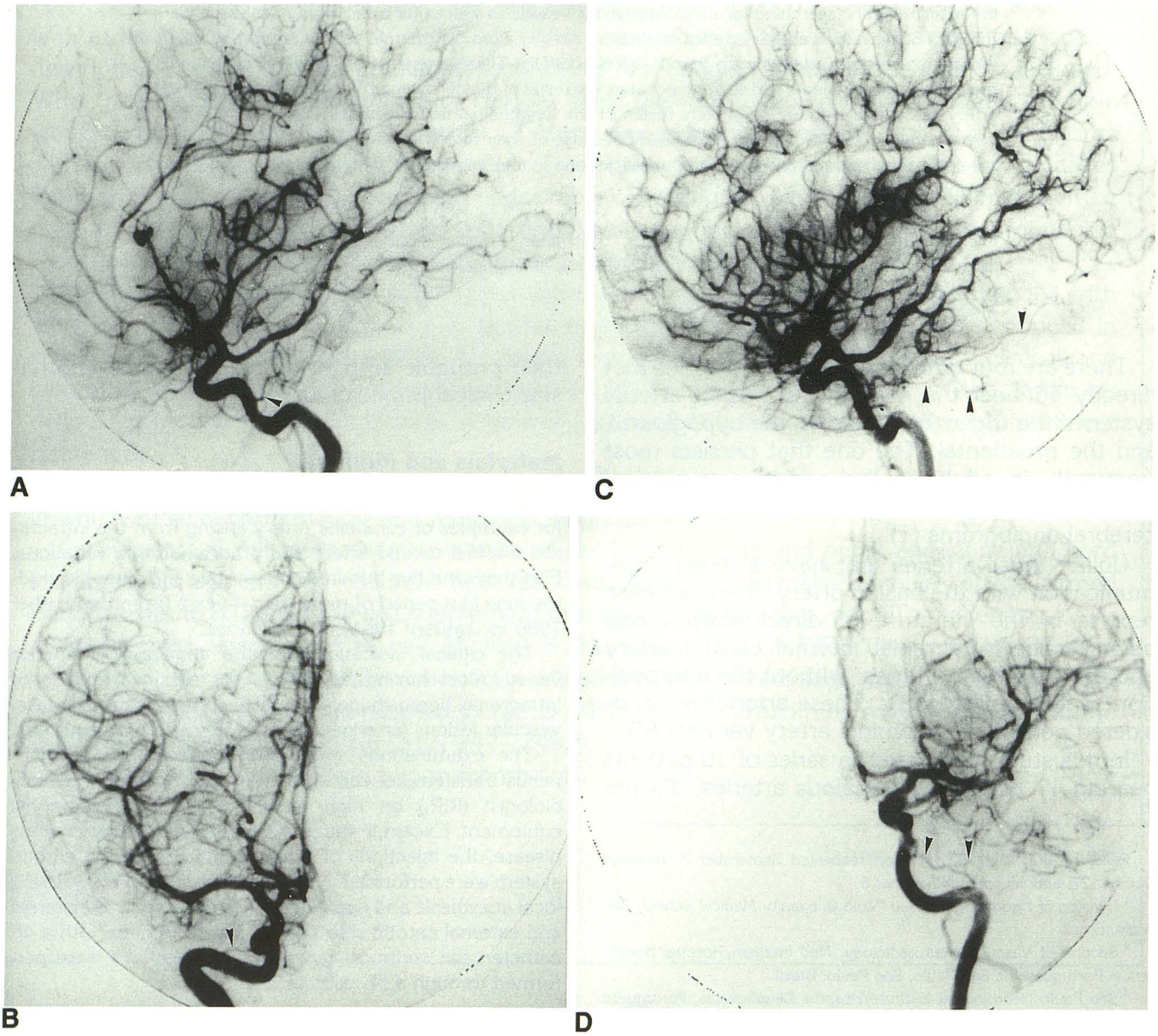

Fig. 1. Bilateral origin of the superior cerebellar arteries from the internal carotid arteries in the same patient.

A and *B*, Right carotid angiograms, lateral arterial phase (*A*) and anteroposterior arterial phase (*B*) views. Anomalous artery (*arrowheads*) supplies cerebellar territory of the superior cerebellar artery.

C and *D*, Left carotid angiograms, lateral arterial phase (*C*) and anteroposterior arterial phase (*D*) views. Anomalous artery (*arrowheads*), bigger than the right one, supplies the territory of the superior cerebellar artery.

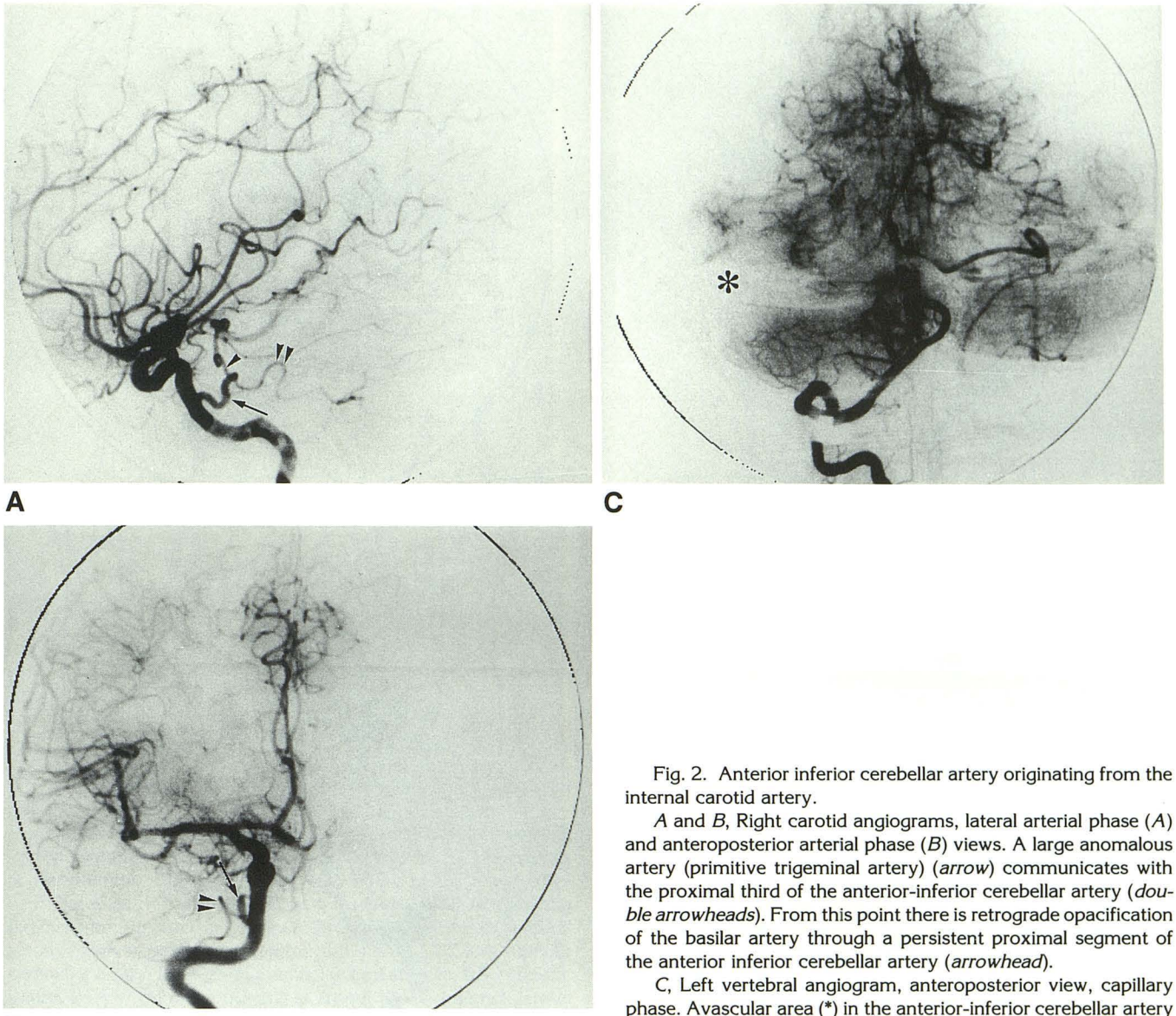

Fig. 2. Anterior inferior cerebellar artery originating from the internal carotid artery.

A and *B*, Right carotid angiograms, lateral arterial phase (*A*) and anteroposterior arterial phase (*B*) views. A large anomalous artery (primitive trigeminal artery) (*arrow*) communicates with the proximal third of the anterior-inferior cerebellar artery (*double arrowheads*). From this point there is retrograde opacification of the basilar artery through a persistent proximal segment of the anterior inferior cerebellar artery (*arrowhead*).

C, Left vertebral angiogram, anteroposterior view, capillary phase. Avascular area (*) in the anterior-inferior cerebellar artery territory.

review of the literature we found 44 cases (2–17) (Nakagawara J. et al presented at the 11th Annual Meeting of the Japanese Neuroradiological Society, 1982) (Okada Y. et al presented at the 12th Annual Meeting of the Japanese Neuroradiological Society, 1983). Twenty-seven of these cases were quite similar to the anterior-inferior cerebellar arteries (5, 7–9, 11, 12–15, 17, Nakagawara J. et al), 13 corresponded to the superior cerebellar arteries (2, 6, 10, 16, 17) (Nakagawara J. et al, Okada Y, et al) and only four resembled the posterior-inferior cerebellar arteries (3, 4, 13, 17).

As described by Quain in 1844, the primitive trigeminal artery originates from the internal carotid artery at the point where this vessel leaves the carotid canal and penetrates the cavernous sinus (C4 segment of the cavernous internal carotid artery) (18). From this point the artery takes a posterior course, sometimes slightly inclined rostrally, through the cavernous sinus, where it occupies a position medial to the ophthalmic branch of the trigeminal nerve. Perforating the dorsum sellae or passing adjacent to its lateral margin, coming from Meckel's cave or through an isolated dural foramen (12), the trigeminal artery reaches the posterior fossa and with a dorsal course near the entry zone of the trigeminal nerve root at the pons, communicates with the basilar artery, usually between the origins of the superior cerebellar arteries and of the anterior-inferior cerebellar arteries. Below the point of entrance of the trigeminal artery, the basilar ar-

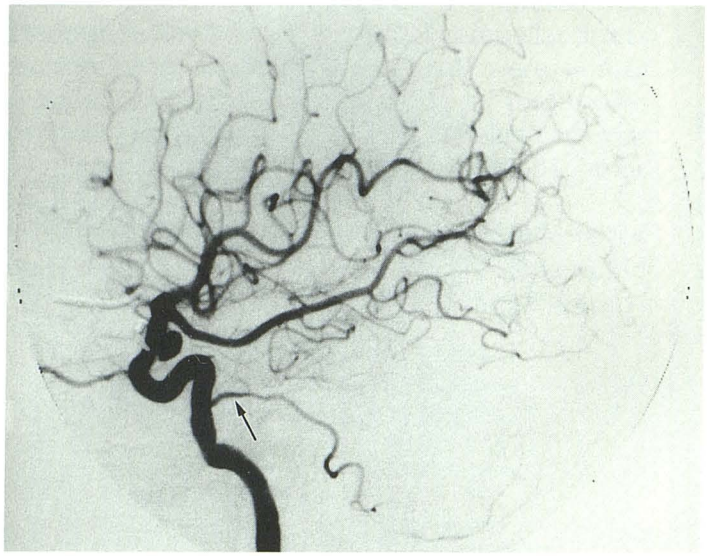

A

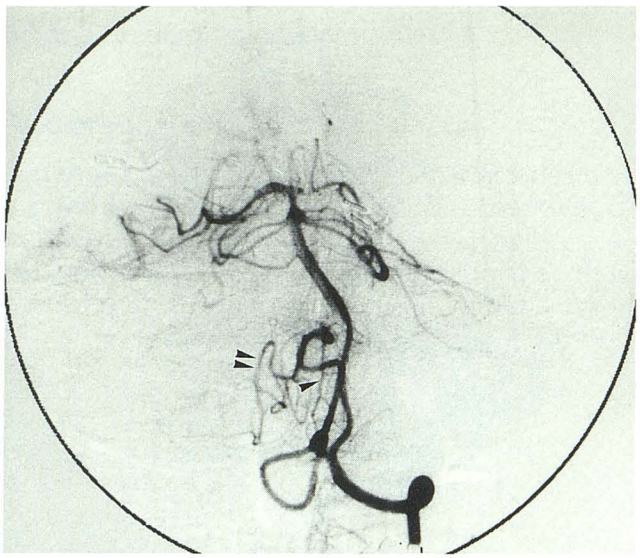

D

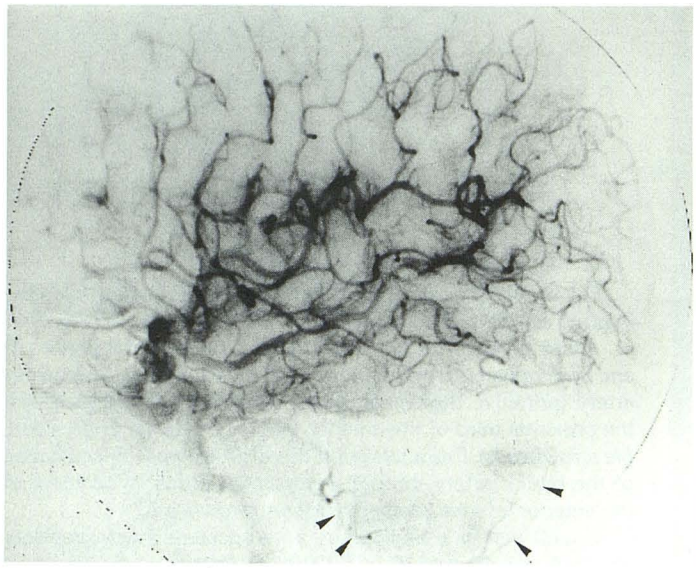

B

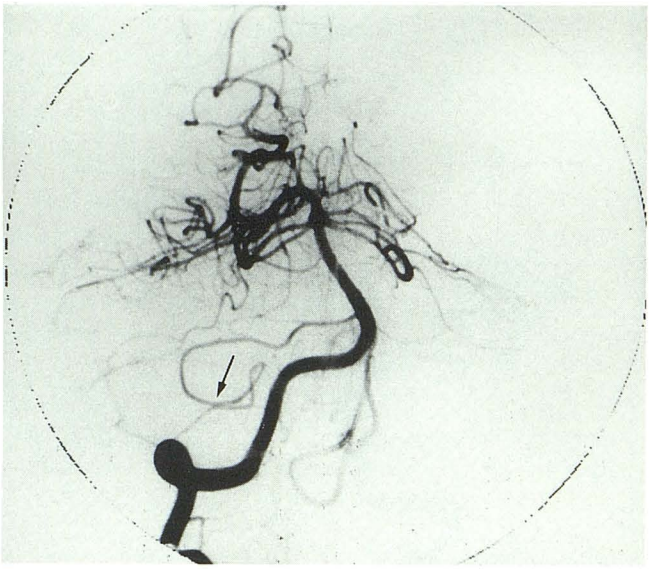

E

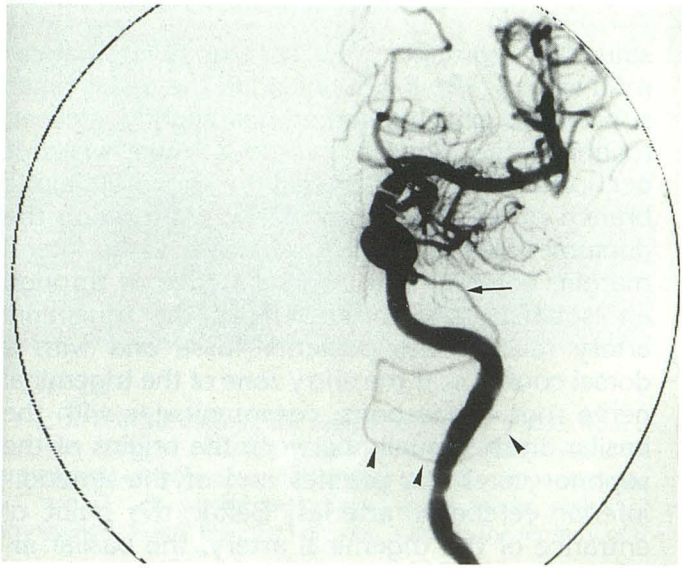

C

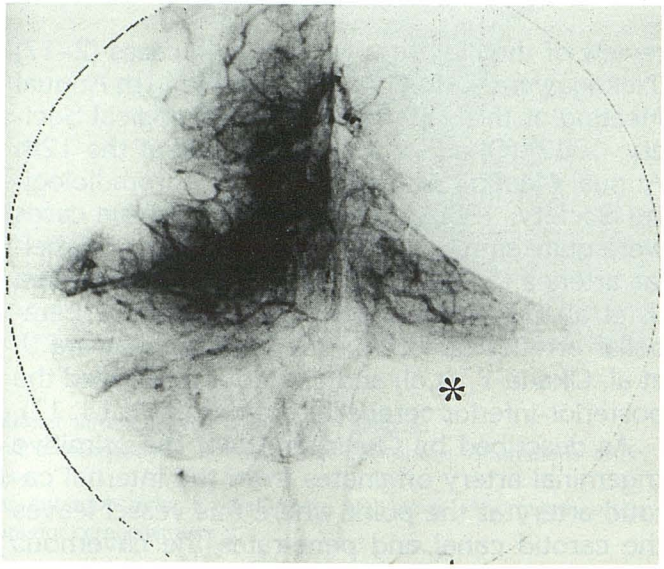

F

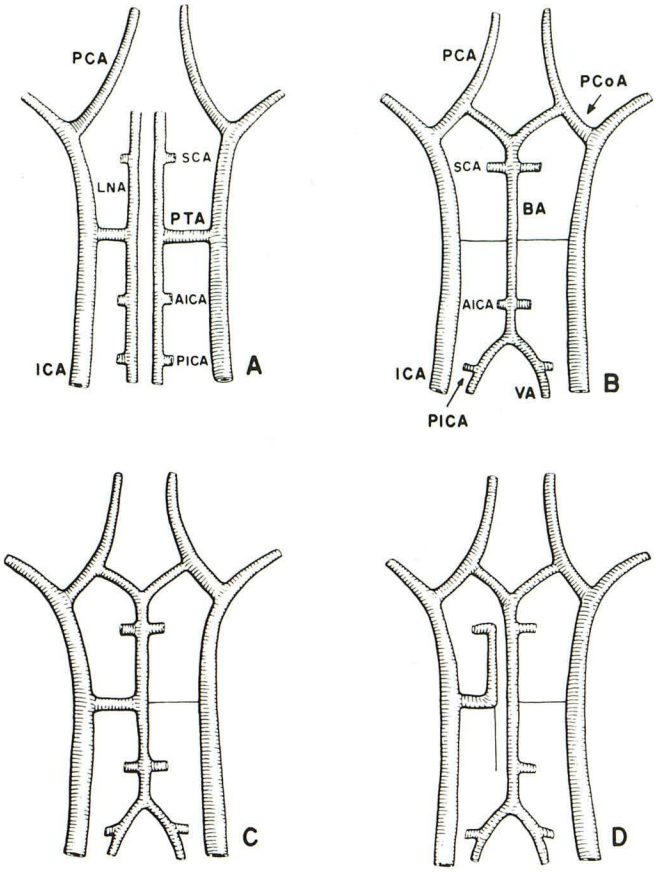

Fig. 4. Development of the basilar artery (modified from Haughton et al (9)).

A, 4-mm human embryo stage; *B*, Normal development; *C*, Persistence of the primitive trigeminal artery; and *D*, persistence of the primitive trigeminal artery and failure of the longitudinal neural arteries to fuse resulting on a cerebellar artery originating directly from the internal carotid artery. PCA = posterior cerebral artery, PCoA = posterior communicating artery, SCA = superior cerebellar artery, LNA = longitudinal neural arteries, BA = basilar artery, PTA = primitive trigeminal artery, ICA = internal carotid artery, AICA = anterior inferior cerebellar artery, PICA = posterior inferior cerebellar artery, VA = vertebral artery.

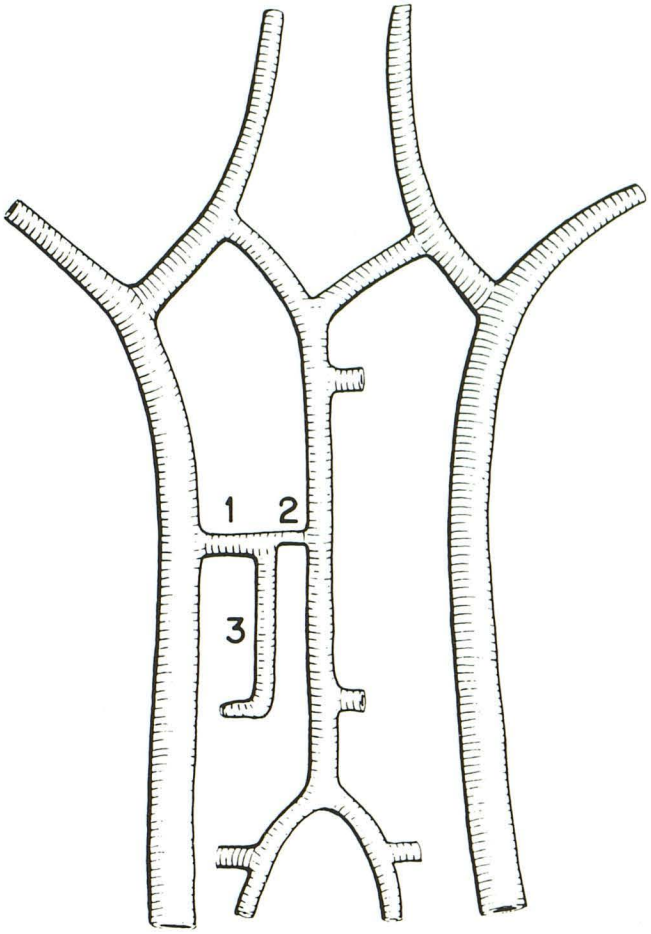

Fig. 5. Abnormal basilar artery development consequent to a complete persistence of the proximal part of the primitive trigeminal artery associated with a partial involution of its distal part and an incomplete fusion of the longitudinal neural arteries. 1 = primitive trigeminal artery, 2 = communication of the primitive trigeminal artery with the basilar artery, 3= anterior inferior cerebellar artery.

tery usually is hypoplastic and the posterior communicating artery could be absent.

The work of Padget (18) constitutes the basis for the understanding of the development and involution of the trigeminal artery. This artery is first seen in the 3-mm embryo. During the 4-mm stage it communicates with fragments of the longitudinal neural arteries, which are formed on the basal surface of the hindbrain. The basilar artery becomes apparent in the 7- to 12-mm stage through the union of the longitudinal neural arteries and it is during its formation that the trigeminal artery starts the involution, disappearing in the 14-mm stage (Fig 4).

Fig. 3. Posterior-inferior cerebellar artery arising directly from the internal carotid artery.

A, *B*, and *C*, Left carotid angiograms, lateral arterial phase (*A*), lateral capillary phase (*B*), and anteroposterior arterial phase (*C*). Large artery (*arrow*) originating directly from the internal carotid artery and supplying the posterior-inferior cerebellar artery territory (*arrowheads*).

D, *E*, and *F*, Right and left vertebral angiograms, left anteroposterior arterial phase (*D*), right anteroposterior arterial phase (*E*), and right anteroposterior capillary phase (*F*). A posterior inferior cerebellar artery arises from the left vertebral artery and irrigates the vermis (*arrowhead*) and adjacent parenchyma from the right cerebellar hemispheric (*double arrowhead*). There is no opacification of the hemispheric territory of the posterior inferior cerebellar artery on the left side. On the right side there is no opacification of the posterior inferior cerebellar artery. Its territory is supplied by a branch from the right anterior inferior cerebellar artery (*arrow*). Note the avascular area corresponding to the posterior inferior cerebellar artery territory on the left side (*).

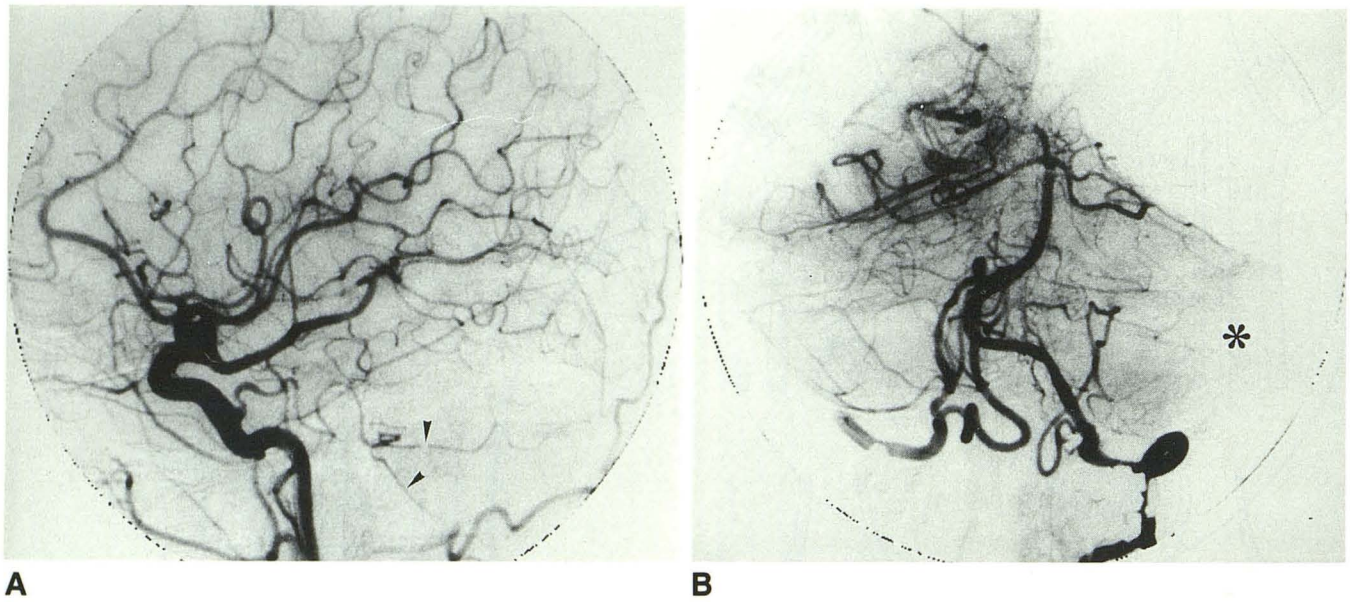

Fig. 6. Anomalous cerebellar artery of small caliber.

A, Left carotid angiogram, lateral arterial phase. Anomalous cerebellar artery arising from the internal carotid artery and sending branches to the anterior inferior cerebellar artery and posterior inferior cerebellar artery territories (*arrowheads*).

B, Left vertebral angiogram, anteroposterior arterial phase. Despite the filling of the left cerebellar arteries, a distal hemispheric avascular area (*) persists which is supplied by the branch originating directly from the internal carotid artery.

The embryological sequence of events that results in the persistence of a direct anastomosis between the internal carotid artery and a cerebellar artery, without interposition of the basilar artery, is not well known. However, Haughton et al (9) have suggested that these anomalous vessels occur as the result of the persistence of a primitive trigeminal artery associated with an incomplete fusion of the longitudinal neural arteries (Fig 4). Consequently, these vessels do not have a direct connection with the basilar artery, as occurs with the primitive trigeminal artery. However, in two of our cases, despite the fact that the main blood flow was to the cerebellar artery, there was a small communication with the basilar artery originating from the point where the trigeminal artery was apparently ending (Fig 2). This finding probably is the result of a complete persistence of the proximal part of the trigeminal artery, associated with a partial involution of its distal part and an incomplete fusion of the longitudinal neural arteries (Fig 5).

The volume of tissue irrigated by the cerebellar arteries is variable and the hemodynamic balance that exists among them makes it difficult to delimit each territory precisely. It is the same with cerebellar arteries originating directly from the internal carotid artery. When of great caliber they are usually associated with a complete absence of the corresponding artery of vertebrobasilar origin and are responsible for the irrigation of the entire area of nervous tissue related to the specific artery (Fig 3). On the other hand, when the artery is of small caliber it irrigates only part of the territory, the rest being irrigated by a corresponding usually hypoplastic, artery, originating from the vertebral or basilar artery (Fig 6).

Although the clinical significance of these anomalous vessels is not yet completely defined, the areas they supply are important. One must be aware of their existence, especially in five situations. The first situation is related to the increasing use of therapeutic embolization in which there exists the risk of deviation of emboli to these anomalous vessels. Because the blood flow in these anastomosis is from the carotid to the vertebrobasilar system, the second situation is related to the potential risk of brain stem and/or cerebellar ischemia by emboli coming from an ulcerated plaque in the common carotid artery bifurcation, or by the therapeutic occlusion of the cervical internal carotid artery. The third situation is related to the risk of hemorrhagic complications in percutaneous gasserian ganglion procedures for the treatment of trigeminal neuralgia becuase of the possible position of these arteries inside Meckel's cave (17). The fourth situation concerns the risk of hemorrhage/ischemia by surgical manipulation of these vessels in approaches to the posterior fossa. Finally, when analyzed by some-

one not acquainted with this type of anomaly, the cerebellar capillary blush seen in carotid angiograms, or the avascular cerebellar area seen in vertebral angiograms, could be misinterpreted as tumor or ischemia, respectively.

Acknowledgment

We thank Mr. Edgard Benassi for his assistance in the preparation of the illustrations.

References

1. Lie TA. Congenital malformations of the carotid and vertebral arterial systems, including the persistent anastomoses. In: Vinken PF, Bruyn GW, eds. *Handbook of Clinical Neurology*. Vol 12. Amsterdam: North-Holland, 1972:289–339
2. Teal JS, Rumbaugh CL, Bergeron RT, Scanlan RL, Segall HD. Persistent carotid-superior cerebellar artery anastomosis: a variant of persistent trigeminal artery. *Radiology* 1972;103:335–341
3. Dilenge D, Heon M. The internal carotid artery. In: Newton TH, Potts DG, eds. *Radiology of the Skull and Brain—Angiography*. St. Louis: Mosby, 1974:1202–1245
4. Chambers AA, Lukin R. Trigeminal artery connection to the posterior inferior cerebellar arteries. *Neuroradiology* 1975;9:121–123
5. Scotti G. Anterior inferior cerebellar artery originating from the cavernous portion of the internal carotid artery. *Radiology* 1975;116:93–94
6. Anderson PA, Sondheimer FK. Rare carotid-vertebrobasilar anastomoses with notes on the differentiation between proatlantal and hypoglossal arteries. *Neuroradiology* 1976;11:113–118
7. Harwood-Nash DC, Fitz CR. *Neuroradiology in infant and children*. St. Louis: Mosby, 1976:356–357
8. Nutik S, Dilenge D. Carotid-anterior cerebral artery anastomosis. *J Neurosurg* 1976;44:378–382
9. Haughton VM, Rosenbaum AE, Pearce J. Internal carotid artery origins of the inferior cerebellar arteries. *AJR: Am J Roentgenol* 1978;130:1191–1192
10. Matsuda I, Handa J, Handa H, Yonekawa Y. Carotid-superior cerebellar anastomosis associated with cerebral aneurysms and angiomatous malformation. *Nippon Geka Hokan* 1979;48:535–541
11. Tomsick TA, Lukin RR, Chambers AA. Persistent trigeminal artery: unusual associated abnormalities. *Neuroradiology* 1979;17:253–257
12. Ito J, Takeda N, Suzuki Y, Takeuchi S, Osugi S, Yoshida Y. Anomalous origin of the anterior inferior cerebellar arteries from the internal carotid artery. *Neuroradiology* 1980;19:105–108
13. Katsuragi M, Inoue Y, Ueda J, et al. An anomalous branch of the internal carotid artery supplying vessels of the posterior fossa directly. *No To Shinkei* 1980;32:515–521
14. Cobb SR, Hieshima GB, Mehringer CM, Grinnell VS, Primbram HW. Persistent trigeminal artery variant: carotid-anterior inferior cerebellar artery anastomosis. *Surg Neurol* 1983;19:263–266
15. Higano S, Uemura K, Ogawa T, et al. Persistent trigeminal artery variant—a case report of five cases and some embryological considerations. *Rhinsho Hoshasen* 1987;32:263–268
16. Lasjaunias P, Berenstein A. *Surgical neuroangiography*. Vol 1. Berlin: Springer-Verlag, 1987:65–66
17. Morita A, Fukushima T, Miyazaki S, Shimizu T, Atsuchi M. Tic douloureux caused by primitive trigeminal artery or its variant. *J Neurosurg* 1989;70:415–419
18. Padget DH. The development of the cranial arteries in the human embryo. *Contrib Embryol* 1948;32:205–262