The next generation GBCA from Guerbet is here
Explore new possibilities
Guerbet
© Guerbet 2024 GUOB220151-A

AJNR

MR of cis-platinum-induced optic neuritis.

S H Mansfield and M Castillo

AJNR Am J Neuroradiol 1994, 15 (6) 1178-1180
http://www.ajnr.org/content/15/6/1178

This information is current as of September 18, 2024.

MR of *cis*-Platinum–Induced Optic Neuritis

Stuart H. Mansfield and Mauricio Castillo

Summary: Right-sided blindness developed in a patient after three intraarterial treatments with *cis*-platinum for a right temporal glioblastoma multiforme. MR showed an enlarged and enhancing optic chiasm. Because of the history of remote radiation therapy and the fact that the tumor was located distal to the optic chiasm, we postulate that the clinical and imaging findings were related to the chemotoxicity.

Index terms: Vision; Glioblastoma multiforme; Chemotherapy; Optic chiasm; Drugs, toxicity; Brain, magnetic resonance

Case Report

The patient was a 45-year-old woman with a 3.5-year history of right temporal lobe anaplastic astrocytoma. The tumor had been debulked twice and treated with external beam radiation therapy (4500 cGy) using a right and left lateral field followed by a three-field booster treatment (1440 cGy) delivered in 54 days. Three months before this admission, a gadopentetate dimeglumine–enhanced magnetic resonance (MR) study was performed and suggested recurrent tumor. A biopsy revealed glioblastoma multiforme, but the patient was otherwise healthy.

She started receiving intraarterial cisplatin. The drug was delivered via a 5-F Berenstein catheter (Meditech, Watertown, Me) placed in the right internal carotid artery at the level of the base of the skull. Cisplatin was given at a dose of 60 mg/m^2 body surface area and was dissolved in sterile water at a concentration of 1 mg/mL. Continuous infusion using the angiographic injector gun at a rate of 2 mL/min was used. Immediately after her third course of intraarterial chemotherapy, the patient experienced a sudden and complete loss of vision in her right eye. MR performed with gadolinium showed intense enhancement of the right lateral region and midregion of the optic chiasm (Fig 1) After completion of the chemotherapy regimen (total of four doses), a follow-up MR study showed minimal residual enhancement of the optic chiasm. At the time of this report the patient still has a left homonymous hemianopsia.

Discussion

Vision loss related to treatment of brain tumors can be secondary to radiation therapy, chemotherapy, and/or tumor progression. If a history of radiation therapy with concomitant or consecutive chemotherapy exists, retrobulbar optic neuritis should be strongly considered (1). Less common causes that also should be included in the differential diagnosis include: radiation/chemotherapy retinopathy and radiation-induced neoplasms affecting the visual apparatus (2).

In a patient with vision loss and a normal fundoscopic examination, retrobulbar neuritis should be considered. Common underlying causes for retrobulbar neuritis include demyelination, inflammation, or infection (3). Involvement of the visual pathways secondary to radiation therapy–associated vasculopathy is rare but may occur if daily doses greater than 250 cGy or total doses exceeding 4500 to 6000 cGy are administered (4, 5). Visual symptoms generally occur between 4 months and 3 years after completion of therapy, with the majority of cases reported 1 year after treatment. Patients younger than 12 years of age and those in whom overlapping fields are used are at greater risk for radiation-induced optic neuritis (6). Pathologically, reactive gliosis, demyelination, fibrinoid necrosis, and endothelial hyperplasia leading to infarction are present (1).

Cis-dichlorodiaminoplatinum (cisplatin) is a chemotherapeutic agent that is being increasingly used in the treatment of brain tumors (7). The spectrum of neurotoxic side effects associated with this drug encompass retrobulbar neuritis, retinitis pigmentosa–like changes, and selective effects of uncertain cause on the occipital cortex, which may result in blindness (8, 9). The most

Received October 30, 1992; accepted after revision February 23, 1993.

From the Department of Radiology, University of North Carolina School of Medicine, Chapel Hill.

Address reprint requests to M. Castillo, MD, Radiology, CB 7510,University of North Carolina at Chapel Hill, Chapel Hill, NC 27599-7510.

AJNR 15:1178–1180, Jun 1994 0195-6108/94/1506–1178 © American Society of Neuroradiology

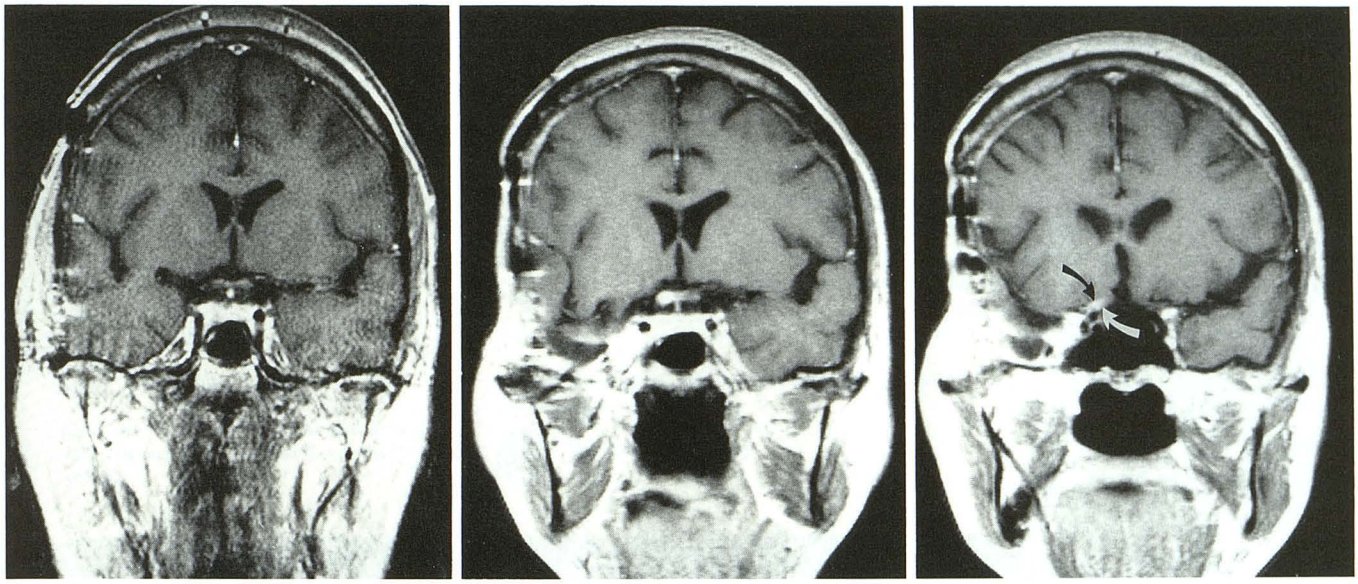

Fig. 1. *A,* Coronal postgadolinium T1-weighted MR image obtained after the second chemotherapy infusion shows a normal optic chiasm. The areas of abnormal enhancement in the right temporal lobe represent recurrent glioblastoma multiforme. Dural enhancement is probably the sequela of surgery.

B, Coronal postgadolinium T1-weighted MR image at a comparable level to *A* obtained 24 hours after the third cisplatin infusion was performed via the right internal carotid artery. Right-sided blindness developed immediately after the medication. There is intense enhancement of the optic chiasm predominantly in its right lateral and middle aspects. The overall size of the optic chiasm has also increased since the previous study, suggesting edema. Precontrast MR study (not shown) showed the chiasm to have normal signal intensity. Postsurgical changes are again noted in the right temporal lobe and meninges.

C, Coronal postcontrast MR T1-weighted image slightly anterior to *B* shows an enhancing and mildly enlarged right prechiasmatic optic nerve *(arrows).*

common side effect is that of retinal toxicity, seen in 5 of 35 patients in one series (10). The optic neurotoxicity of cisplatin also has been demonstrated experimentally (11). The mechanisms responsible for the toxicity are not known. Synergistic effects between chemotherapeutic agents, particularly methotrexate and radiation, are known to occur. Although the most common sequela is leukoencephalopathy, optic atrophy also has been reported after combined radiation/chemotherapy treatments (12, 13).

In our case there was a close temporal relationship between the sudden loss of vision and chemotherapy. Because radiation therapy had been administered 3.5 years previously, radiation-induced neuritis is not a likely cause for the symptoms and the MR abnormalities found in our patient. The remote possibility of delayed reaction to radiation augmented by the intraarterial infusion of *cis*-platinum cannot, however, be totally excluded. MR features similar to the ones seen in this case recently have been reported after only radiation therapy (2). Also, because the residual tumor was distant from the optic chiasm, tumor extension along the optic pathway is unlikely. Because blood is supplied to the optic chiasm by small performating arteries arising mainly from the high internal carotid, A-1 segment of the anterior cerebral, anterior communicating, and the posterior communicating arteries, perhaps the complication presented here could have been avoided by infusing the drug through a microcatheter placed in the right middle cerebral artery.

References

1. Kline LB, Kim JY, Ceballos R. Radiation optic neuropathy. *Ophthalmology* 1985;92:1118–1126
2. Hudgins PA, Newman NJ, Dillon WP, Hoffman JC. Radiation induced optic neuropathy: characteristic appearances on gadolinium enhanced MR. *AJNR Am J Neuroradiol* 1992;13:235–238
3. Guy J, Mancuso A, Quisling RG, et al. Gadolinium-DTPA enhanced magnetic resonance imaging in optic neuropathies. *Ophthalmology* 1990;97:592–598
4. Parsons JT, Fitzgerald CR, Hood CL, et al. The effects of irradiation on the eye and optic nerve. *Int J Radiat Oncol Biol Phys* 1983;9:609–622
5. Roden D, Bosley TM, Fowble B, et al. Delayed radiation injury to retrobulbar optic nerves and chiasm. *Ophthalmology* 1990;97:346–351
6. Zimmerman CF, Scatz NJ, Glaser JS. Magnetic resonance imaging of radiation optic neuropathy. *Am J Ophthal* 1990;110:389–394

7. Kattah JC, Potolicchio J, Kotz HL, et al. Cortical blindness and occipital lobe seizures induced by cis-platinum. *Neuro-Ophthalmology* 1986;7:99–104
8. Ostro S, Hahn D, Wiernek PH, Richards RD. Ophthalmologic toxicity after cis-dichlorodiaminoplatinum (II) therapy. *Cancer Treat Rep* 1978;10:1591–1593
9. Berman BA, Mann MP. Seizures and transient cortical blindness associated with cis-platinum (II) dichlorodiaminoplatinum (PDD) therapy in a thirty-year-old man. *Cancer* 1980;45:764–766
10. Feun LG, Wallace S, Stewart DJ, et al. Intracarotid infusion of cis-diamminedichloroplatinum in the treatment of recurrent malignant brain tumors. *Cancer* 1984;54:794–799
11. Clark AW, Parhad IM, Griffin JW, et al. (Abst.) Neurotoxicity of cis-platinum: pathology of the central and peripheral nervous systems (Abst.). *Neurology* 1980;30:429
12. Glass JP, Lee YY, Bruner J, Fields WS. Treatment related leukoencephalopathy. A study of three cases and literature review. *Medicine (Baltimore)* 1986;65:154–162
13. Fishman ML, Bean SC, Cogan DG. Optic atrophy following prophylactic chemotherapy and cranial radiation for acute lymphocytic leukemia. *Am J Ophthalmol* 1976;82:571–576