

Are your **MRI contrast agents** cost-effective?

Learn more about generic **Gadolinium-Based Contrast Agents**.



FRESENIUS
KABI

caring for life

AJNR

Subcortical low intensity in early cortical ischemia.

M Ida, K Mizunuma, Y Hata and S Tada

AJNR Am J Neuroradiol 1994, 15 (7) 1387-1393

<http://www.ajnr.org/content/15/7/1387>

This information is current as
of May 7, 2024.

Subcortical Low Intensity in Early Cortical Ischemia

Masahiro Ida, Kimiyoshi Mizunuma, Yuichi Hata, and Shimpei Tada

PURPOSE: To describe subcortical low intensity on T2- and proton density-weighted MR images in early cortical ischemia and to discuss a cause of these findings. **METHODS:** Nine patients with early cortical ischemia were studied with proton density- and T2-weighted images, and T1-weighted images at 1.5 T. Gadolinium enhancement was added in six cases. **RESULTS:** In all cases there was high to intermediate intensity in the cortex and low intensity in the subcortical white matter (subcortex) on the proton density- and T2-weighted images. No significant signal abnormalities were shown on T1-weighted images in the subcortex; gyriform enhancement was seen in the affected cortex in all of the six patients studied with gadolinium. Of the four patients with follow-up MRs, the subcortical low intensity changed to high intensity in two and remained low in two patients in the chronic stage. Neither hemorrhage nor calcification was seen on CT. **CONCLUSION:** Iron accumulation in the subcortex caused by disruption of the axonal transportation and continuous production of free radicals caused by the hypoxic-ischemic state most likely reduces the signal intensity of the subcortex on the proton density- and T2-weighted images. The subcortical low intensity on the proton density- and T2-weighted images is an important diagnostic sign of early cortical ischemia.

Index terms: Brain, ischemia; Brain, magnetic resonance; Iron; Moyamoya disease

AJNR Am J Neuroradiol 15:1387-1393, Aug 1994

It has been established that magnetic resonance (MR) is valuable in detecting cerebral infarction (1, 2). The T2-weighted images usually show an increase in signal intensity in the focus of infarction because of an increase in mobile protons from cytotoxic and vasogenic edema or gliosis. On the other hand, a reduction of signal intensity on the T2-weighted images can occur because of deoxyhemoglobin when hemorrhage complicates the infarction.

We recently encountered nine patients with early cortical ischemia in which the proton density-weighted and T2-weighted images showed low intensity in the subcortical white matter (subcortex). Previous authors have reported a

decreased signal intensity on the T2-weighted images in the putamen, thalamus, caudate nucleus, or deep white matter in patients with severe ischemic-anoxic insults and with degenerative disorders of the brain (3-13). We report hypointense signal on T2-weighted images in the subcortical white matter in patients with ischemic-anoxic events and correlate these findings with the clinical course and hypothesize a cause of these findings.

Patients and Methods

We studied two patients with moyamoya disease (cases 1 and 2) and seven with cortical infarction (cases 3 to 9). The clinical features of the nine patients with low intensity in subcortical white matter on the proton density- and T2-weighted images are summarized in the Table. There were six male and three female patients, 2 to 85 years old (mean, 50.6 years). The clinical diagnosis and the ictus were determined by neurologists based on the history and physical examination. Moyamoya disease in cases 1 and 2 was diagnosed by means of cerebral angiography (bilateral internal carotid and vertebral arteriography), which was done after the MR studies. In these two patients there was no phakomatosis, and serum antilupus coagulant was negative. Initial MR was performed at the acute stage (dur-

Received June 11, 1993; accepted after revision November 5.

Presented at the Annual Meeting of the American Society of Neuroradiology, Vancouver, Canada, May 1993.

From the Department of Radiology, The Jikei University School of Medicine, Tokyo, Japan.

Address reprint requests to Masahiro Ida, MD, Department of Radiology, The Jikei University School of Medicine, 3-25-8 Nishi-shinbashi, Minato-ku, Tokyo 104, Japan.

AJNR 15:1387-1393, Aug 1994 0195-6108/94/1507-1387

© American Society of Neuroradiology

MR findings in nine cases with subcortical low intensity on proton density- and T2-weighted images

Case/Age, y/Sex (Disease)	Clinical Stage	PDWI and T2WI		T1WI		Enhanced T1WI	
		Cortex	Subcortex	Cortex	Subcortex	Cortex	Subcortex
1/3/F (moyamoya disease)	A	High	Low	Iso	Iso	+	-
	S	High	Low	...		+	-
	C (1 m)	High	Iso-high	Iso	Iso-low	...	
	C (3 m)	High	High	...		-	-
2/4/M (moyamoya disease)	S	High	Low	Iso	Iso	...	
	C (14 m)	High	Iso-high	
3/66/M	S	High	Low	...		+	-
4/85/F	S	High	Low	Iso	Iso	+	-
5/84/M	S	High	Low	Iso	Iso	+	-
	C (1 m)	High	Low	Iso-high	Iso	+	-
6/62/M	S	High-iso	Low	Iso	Iso	+	-
7/65/M	S	High	Low	Low	Low	+	-
	C (2 m)	High	High-low	Iso	Iso	...	
8/39/M	S	High	Low	Iso	Iso	...	
9/47/F	A	High	Low	Low	Low	...	

Note.—PDWI indicates proton density-weighted image; T2WI, T2-weighted image; T1WI, T1-weighted image; A, acute phase (1 to 3 days); S, subacute phase (4 to 21 days); C, chronic phase (22 days-); high (iso, low), high (iso, low) intensity to normal cortex or subcortex; +, enhancement with gadopentetate dimeglumine; and -, no enhancement.

ing the 3 days after onset) in two cases and at the subacute stage (4 to 21 days) in seven cases. Four patients (cases 1, 2, 5, and 7) underwent six follow-up MR examinations (one at subacute stage, five at chronic).

MR imaging was performed at 1.5 T. Multisection, spin-echo proton density- and T2-weighted images were obtained in all cases with the following parameters: repetition time of 3000, echo time of 25 (proton density-weighted) and 80 or 120 (T2-weighted); 1 excitation; section thickness of 5 or 7 mm; field of view of 20 cm; and matrix number of 224 × 256. T1-weighted images were obtained with 600/20 (repetition time/echo time). All cases except one (case 3) had precontrast T1-weighted images, and six cases (cases 1, 3, 4, 5, 6, and 7) had postcontrast T1-weighted images within 15 minutes after intravenous administration of gadopentetate dimeglumine at a dose of 0.2 mmol/kg. The proton density- and T2-weighted images were obtained before the administration of contrast medium. Computed tomographic (CT) scans of the brain were available in five cases (cases 1, 2, 5, 8, and 9) 1 to 18 days before or after the MR.

Results

The results of MR studies in the nine cases are summarized in the Table. In all cases there was high intensity to isointensity in the cortex and

low intensity in the adjacent subcortex on the proton density- and T2-weighted images. We performed a retrospective review of the medical records and MR images (proton density- and T2-weighted images) of 184 patients (64 in acute and subacute stage, and 120 in the chronic stage) with cerebral infarction in an area fed by hemispheric branches of cerebral arteries, and we found these 9 cases with early cortical infarction (14.1% in the acute and subacute stage, 4.9% in all of the group).

On the subsequent follow-up MR images (cases 1, 2, 5, and 7), the subcortical low intensity persisted at the chronic stage in two cases (cases 5 and 7), with partial high signal intensity in one case (case 7). In case 1, although the subcortical low intensity continued until the subacute stage, there was mild high intensity spread diffusely in the subcortex in the chronic stage (Fig 1). In case 2, the low intensity in the subcortex became high to intermediate at the chronic stage (14 months later) (Fig 2). No patient improved clinically in hemiparesis or sensory deficit at the time of follow-up MR examination in any of these four cases (cases 1, 2,

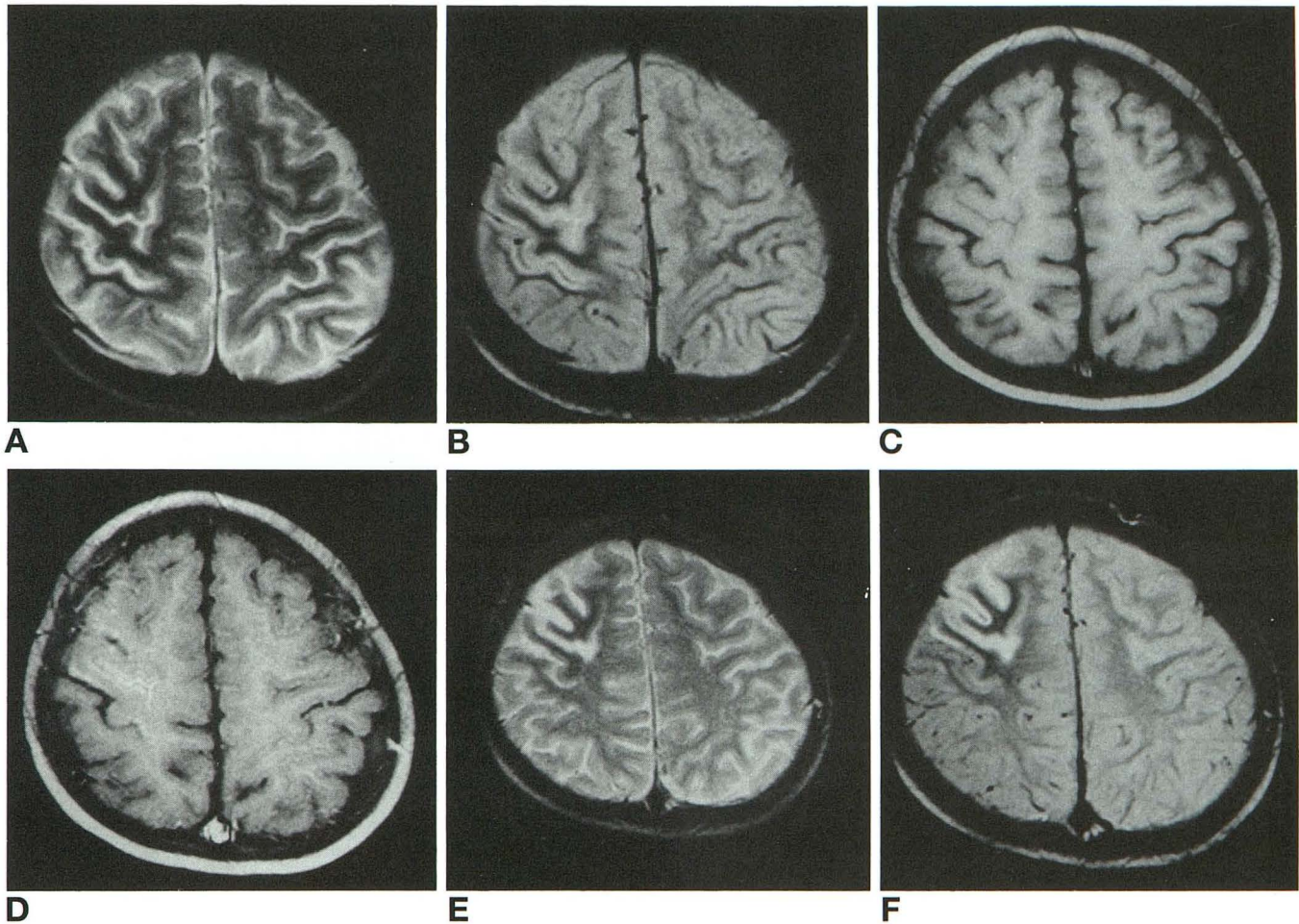


Fig 1. Case 1, 3-year-old girl with cortical infarction caused by moyamoya disease.

A-D, MR images obtained at acute stage. A, T2-weighted and B, proton density-weighted images show gyrforn high intensity in cortex and markedly low intensity in subcortex of right frontal lobe. C, T1-weighted image shows no signal abnormality in either the cortex or subcortex. D, Gadopentetate dimeglumine-enhanced T1-weighted image represents thin enhancement in the cortex.

E-F, MR images obtained at subacute stage. E, T2-weighted and F, proton density-weighted images still display prominent high intensity in the cortex and low intensity in the subcortex.

5, and 7). In two (cases 2 and 7) of the four cases the symptoms were progressive.

There was no significant signal abnormality in the subcortex in seven of eight cases and a slight reduction of intensity in one case (case 7) on the T1-weighted images (Fig 3). The T1-weighted images showed no high signal intensity in the subcortex at the subacute to chronic stage. Gyrforn enhancement after contrast was detected in the affected cortex of all six cases. No loss of signal intensity was observed in the putamen or thalamus on the proton density- and T2-weighted images in any case in the acute or subacute stage. In case 7, no signal abnormality was detected in the basal ganglia or thalamus on the initial MR images in the subacute stage, but a reduction of intensity was

recognized in the right putamen and along the right pyramidal tract (the corona radiata to the cerebral peduncle) on the T2-weighted images in the chronic stage (Fig 3). There was neither calcification nor hemorrhage on CT scans in the affected cortex or subcortex in any of the five cases (cases 1, 2, 5, 8, and 9).

Discussion

MR is efficient in showing early infarction within the first 24 hours of ictus, when no or only subtle abnormality is seen on CT scans (2). Even small infarction can be clearly seen because of increased signal intensity on T2-weighted images. Proton density-weighted images are more valuable than T2-weighted

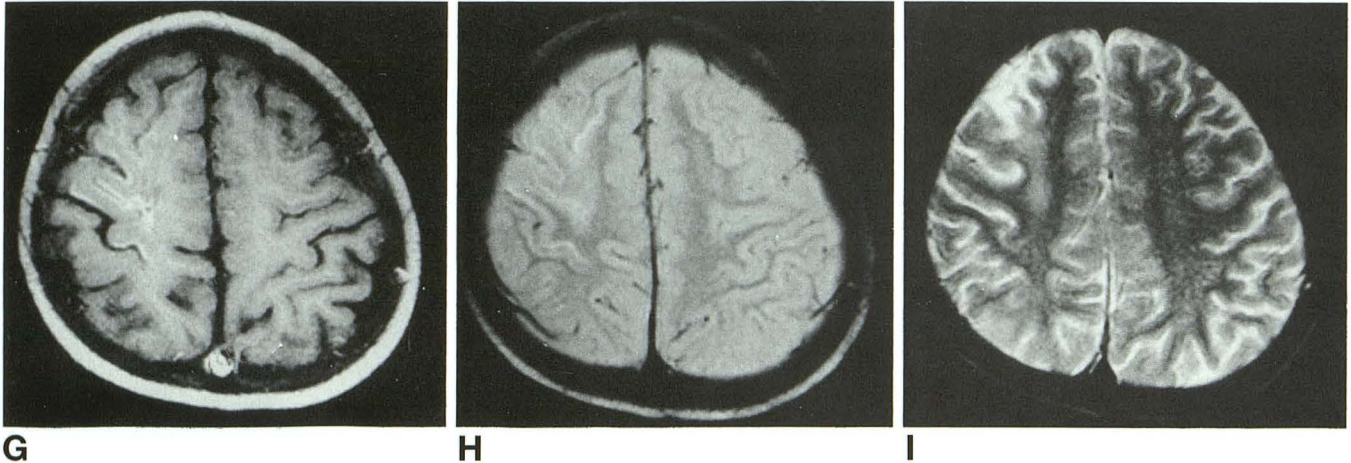
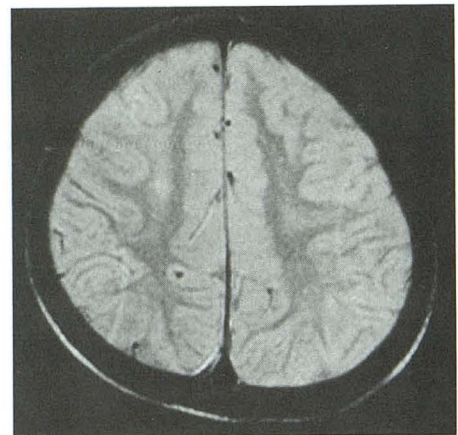
**G****H****I**

Fig 1, *cont'd.*

G, MR image obtained at subacute stage. T1-weighted image with contrast demonstrates cortical enhancement. CT scans (not shown) were normal.

H, On proton density-weighted image, the low intensity in the subcortex is no longer present, and an area of mild high intensity is seen in the subcortical white matter. The T1-weighted image (not shown) was normal.

I and J, MR images obtained at the chronic stage (3 months later). **I**, T2-weighted and **J**, proton density-weighted images demonstrate an area of mildly high intensity in the subcortex. There was no contrast enhancement (not shown).

**J**

images in detecting peripheral cortical infarcts, because the cerebrospinal fluid may mask the high signal in the cortex on T2-weighted images. In case 1 in an acute stage of cortical infarction, high intensity in the affected cortex was hardly discernible because of the adjacent cerebrospinal fluid space on the T2-weighted

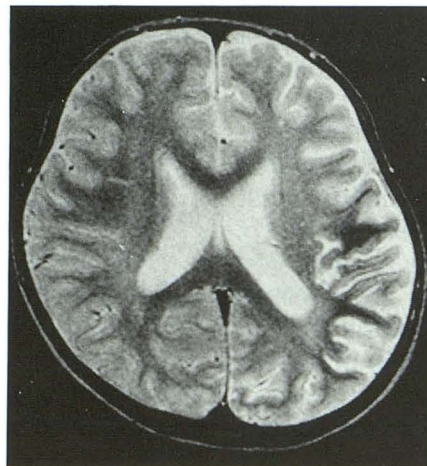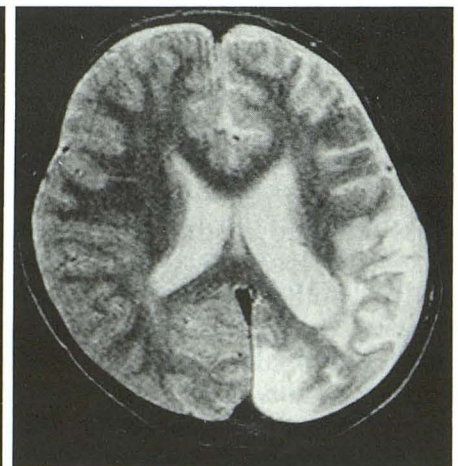
image. The subcortical low-intensity area was more prominently visible than the cortical high intensity on the T2-weighted image.

The shortening of the T2 relaxation time as seen in the subcortical white matter in our patients is caused by reduction of mobile proton or loss of uniformity of local magnetization. Calci-

Fig 2. Case 2, 4-year-old girl with cortical infarction caused by moyamoya disease.

A, T2-weighted image obtained at the subacute stage shows high intensity in the cortex and low intensity in the subcortex of a perfusion area fed by the left middle cerebral artery.

B, On T2-weighted image obtained at the chronic stage (14 months later), the subcortical low intensity has already disappeared, and an area of high to isointensity is present in the subcortex.

**A****B**

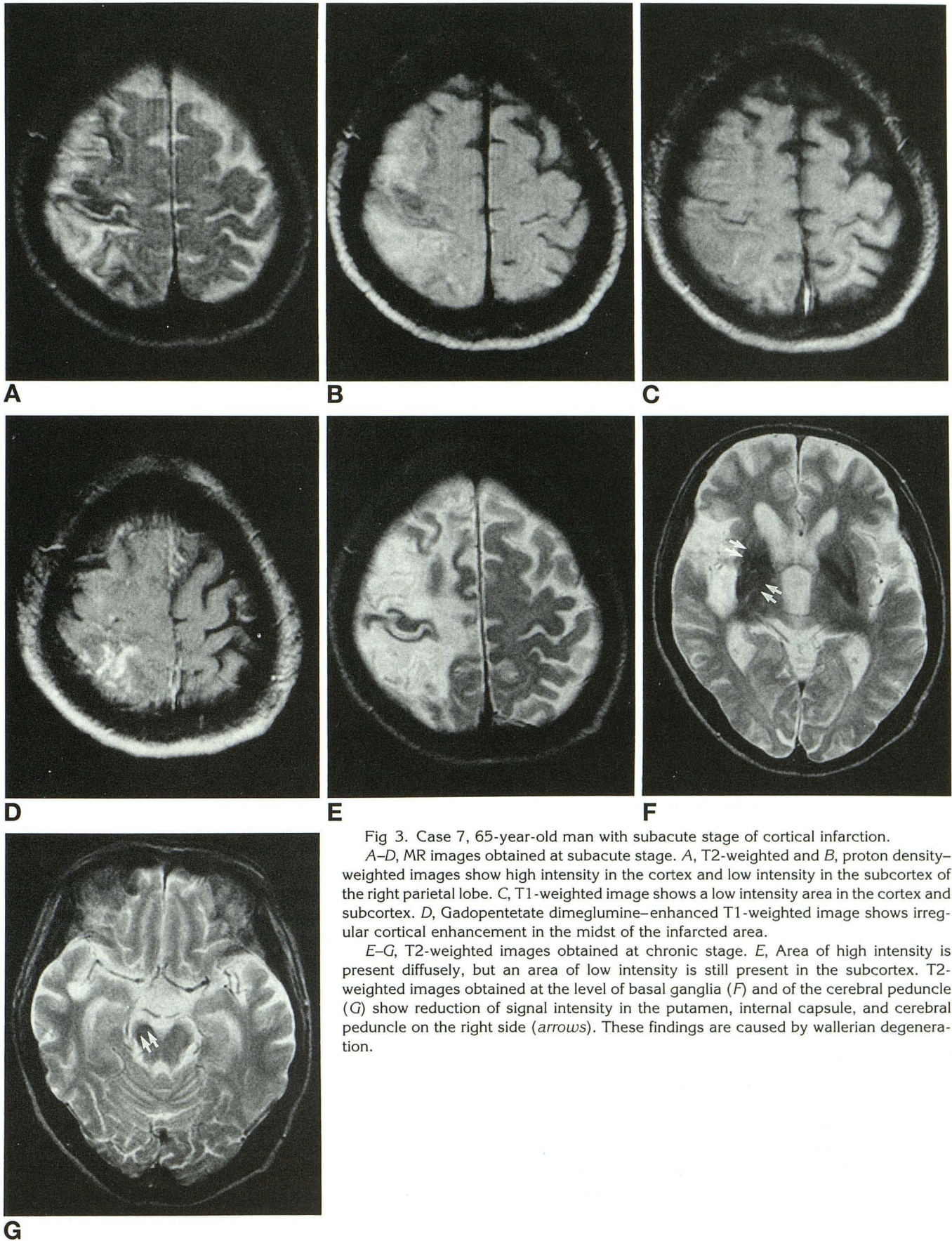


Fig 3. Case 7, 65-year-old man with subacute stage of cortical infarction. A-D, MR images obtained at subacute stage. A, T2-weighted and B, proton density-weighted images show high intensity in the cortex and low intensity in the subcortex of the right parietal lobe. C, T1-weighted image shows a low intensity area in the cortex and subcortex. D, Gadopentetate dimeglumine-enhanced T1-weighted image shows irregular cortical enhancement in the midst of the infarcted area. E-G, T2-weighted images obtained at chronic stage. E, Area of high intensity is present diffusely, but an area of low intensity is still present in the subcortex. T2-weighted images obtained at the level of basal ganglia (F) and of the cerebral peduncle (G) show reduction of signal intensity in the putamen, internal capsule, and cerebral peduncle on the right side (arrows). These findings are caused by wallerian degeneration.

fication, deoxyhemoglobin, hemosiderin, and ferritin are well known to have a strong shortening effect on the T2 relaxation time in the brain tissue. Iron may be the cause of the low signal intensity on T2-weighted images in the subcortex. The iron metabolic pathway in the normal brain tissue is not clearly understood. Iron is absorbed from the small intestine into the bloodstream, and thereafter immediately incorporated into transferrin (iron-carrying protein) for transportation in the plasma. Transferrin is taken up and bound to a specific receptor on endothelial cells of capillaries in the thalamus and basal ganglia (14). The iron concentration in the brain is independent of hemoglobin metabolism and of iron storage in other organs. There may be an axonal transport of iron from sites of uptake in the basal ganglia to sites of use in the cortex (12). The iron is assumed to be internalized by dendrites, and transported along the axon and then it may be subsequently released and stored in oligodendrocytes or glial cells of the cortex. Iron deposition has been reported at autopsy (12, 13) and on MR (10, 11) in ferruginated neurons of the thalamus after a cortical ischemic-anoxic episode. In the cases of this series, that iron accumulates proximally in the subcortex with cortical diseases as a result of interruption of axonal iron transportation from the basal ganglia and thalamus remains speculative. Unlike most previously described cases in the chronic stage (10, 11), all our cases were examined at an acute to subacute stage of cerebral infarction. It is uncertain whether iron accumulates in the early phase in a sufficient amount to be seen as a reduced intensity on proton density- and T2-weighted images.

Iron is a constituent of some enzymes that play an important role in oxidative reactions, particularly in conditions of hypometabolism (16, 17). Hypoxic or ischemic states initiate deoxidation of molecular oxygen in mitochondria to superoxide (a low-activity free radical). The superoxide is converted to hydrogen peroxide and then to hydroxyl radical, which is a free radical with strong activity. Low-molecular-weight iron complexes (eg, iron-adenosine triphosphate) catalyze these reactions to produce reactive oxygen intermediates. The hydroxyl radicals are known to have a strong cellular toxicity that alternates permeability of cellular membrane, although these free radicals are unstable and short-lived. There are also

other free radical-producing pathways that are mediated by arachidonic acid in the hypoxic-ischemic state (18). These free radicals have a paramagnetic effect. We hypothesize that continuous production of a large number of free radicals, though extremely unstable, in the hypoxic or ischemic tissue is responsible for reducing the signal intensity on the proton density- and T2-weighted images (19).

The subcortical low intensity was irreversible in some cases (cases 5 and 7) until the chronic stage. In three cases (cases 1, 2, and 7), on the other hand, the low intensity was no longer present, and high intensity spread in the subcortex. It seemed that irreversible infarction most likely expanded into the subcortex, and an increase of mobile protons caused by glial proliferation results in high intensity on T2-weighted images. Only iron deposition in the brain tissue caused by the axonal injury is a less likely explanation of the low signal, because this phenomenon would not occur in a short period and would not be reversible. Free radicals produced in the area of hypoxia are, on the other hand, extremely unstable and short-lived. We think both iron deposition and production of free radicals are necessary to account for reduction of the T2 relaxation in our cases. The free radicals are thought to cause the subcortical low signal at the acute to early subacute stage, and iron deposition caused by interruption of axonal transport may follow at the late subacute to chronic stage.

It is well accepted that calcium increases with age in the globus pallidus and the dentate nucleus of the cerebellum. Because calcification does not include mobile proton, there is no signal shown on MR images. In diseases such as pseudohypoparathyroidism, abscess, and old hematoma, abnormal calcium deposit occurs in the brain tissue, but not at acute to subacute stages of the diseases. No such high density representing calcification was detected in the subcortex on CT scans in our cases. Decrease of the T2 relaxation time in subcortical white matter could not be attributed to calcium deposit in our cases.

Deoxyhemoglobin in extravasated blood displays a marked reduction of signal intensity on the T2-weighted images. It has a strong magnetic susceptibility because of unpaired electron of iron. But the blood is not a cause of the subcortical low signal in our cases, because

follow-up MR showed no high intensities on T1-weighted images.

Wallerian degeneration is anterograde degeneration of projection fibers and their myelin sheaths. It results from a variety of injury to the proximal portion of the neuron. Low signal can be seen on T2-weighted images in the degenerated axons during approximately 4 to 14 weeks of the ictus (20). It is theorized that myelin protein degradation occurs first, and lipid structures remain chemically unaltered and relatively highly concentrated in the degenerated axon. The high lipid-to-protein ratio results in low signal on T2-weighted images (20). In our cases, the subcortical low intensity at the acute to subacute stage seems to exclude Wallerian degeneration, because the phenomenon has been detected no sooner than 4 weeks after clinical symptoms. In case 7, the low intensity in the corona radiata to the cerebral peduncle at the chronic stage could be caused by such Wallerian degeneration (Fig 2).

There was no clinical improvement in the hemiparesis and sensory deficit at the time of follow-up MR (cases 1, 2, 5, and 7). In cases 2 and 7, in which there were high intensities in the subcortex at the chronic stage, irreversible infarction might expand into the subcortex, and the patients' symptoms took a turn for the worse. It is considered that clearing of the subcortical low intensity does not portend a better clinical prognosis.

In our study, the subcortical low intensity is found in 14.1% of acute or subacute infarction. We speculate that the phenomenon is not rare in the acute to subacute stage of cortical infarction. But the incidence may vary with imaging sequence and field strength of MR, because sensitivity to magnetic susceptibility is more intense at high tesla or with gradient-echo sequences than at low strength or with fast spin-echo sequences.

In summary, the subcortical low intensity on the proton density- and T2-weighted images is an important diagnostic sign for early cortical ischemia. Localized high intensity in the affected cortex is sometimes difficult to discern from the adjacent cerebrospinal fluid on T2-weighted images. It is conceivable that production of free radicals caused by hypoxia or ischemia and iron accumulation in the subcortex caused by disruption of the axonal transportation reduce the signal intensity on the proton

density- and T2-weighted images in the subcortical white matter.

References

1. Bryan RN, Willcott MR, Schneiders NJ, et al. Nuclear magnetic resonance evaluation of stroke. *Radiology* 1983;149:189-192
2. Brant-Zawadzki M, Pereira B, Weinstein P, et al. MR imaging of acute experimental ischemia in cats. *AJNR Am J Neuroradiol* 1986;7:7-11
3. Vakili S, Drew AL, Von Schucking S, et al. Hallervorden-Spatz syndrome. *Arch Neurol* 1977;34:729-738
4. Littrup PJ, Gebarski SS. MR imaging of Hallervorden-Spatz disease. *J Comput Assist Tomogr* 1985;9:491
5. Klintworth GK. Huntington's chorea: morphologic contributions of a century. In: Barbeau A, Chase TN, Paulson GW, eds. *Advances in neurology*. New York: Raven, 1973:353-368
6. Drayer BP, Olanow W, Burger P. Parkinson plus syndrome: diagnosis using high field MR imaging of brain iron. *Radiology* 1986;159:493-498
7. Earle KM. Studies on Parkinson's disease including X-ray, fluorescent spectroscopy of formalin-fixed brain tissue. *J Neuropathol Exp Neurol* 1968;27:1-14
8. Drayer B, Burger P, Hurwitz B, et al. Reduced signal intensity on MR images of thalamus and putamen in multiple sclerosis: increased iron content? *AJNR Am J Neuroradiol* 1987;8:413-419
9. Araki T, Ohba H, Monzawa S, et al. Membranous lipodystrophy: MR imaging appearance of the brain. *Radiology* 1991;180:793-797
10. Dietrich RB, Bradley WG Jr. Iron accumulation in the basal ganglia following severe ischemic-anoxic insults in children. *Radiology* 1988;168:203-206
11. Cross PA, Atlas SW, Grossman RI. MR evaluation of brain iron in children with cerebral infarction. *AJNR Am J Neuroradiol* 1990;11:341-348
12. Urich H. Malformations of the nervous system, perinatal damage and related conditions in early life. In: Blackwood W, Corsellis JAN, eds. *Greenfield's pathology*. London: Edward Arnold, 1976; 434
13. Kim RC, Ramachandran T, Parisi JE, Collins GH. Pallidonigral pigmentation and spheroid formation with multiple striatal lacunar infarcts. *Neurology* 1981;31:774-777
14. Hill JM, Ruff MR, Weber RJ, et al. Transferrin receptors in rat brain: neuropeptide-like pattern and relationship to iron distribution. *Proc Natl Acad Sci USA* 1985;82:4553-4557
15. Hill JM. Iron concentration reduced in ventral pallidum, globus pallidus, and substantia nigra by GABA-transaminase inhibitor, gamma-vinyl GABA. *Brain Res* 1985;342:18-25
16. Willmore LJ, Hiramatsu M, Kochi H, et al. Formation of superoxide radicals after FeCl₃ injection into rat isocortex. *Brain Res* 1983;277:393-396
17. Kogure K, Arai H, Abe K, Nakano M. Free radical damage of the brain following ischemia. In: Kogure K, Hossmann KA, Siesjo BK, et al., eds. *Progress in brain research*. vol 63. Amsterdam: Elsevier, 1985:237-263
18. Kontos HA, Povlishock JT. Oxygen radicals in brain injury. *CNS Trauma* 1986;3:257-263
19. Haimes AB, Zimmerman RD, Morgello S, et al. MR imaging of brain abscesses. *AJNR Am J Neuroradiol* 1989;10:279-291
20. Kuhn MJ, Mikulis DJ, Ayoub DM, et al. Wallerian degeneration after cerebral infarction: evaluation with sequential MR imaging. *Radiology* 1989;172:179-182