

Are your **MRI contrast agents** cost-effective?

Learn more about generic **Gadolinium-Based Contrast Agents**.



FRESENIUS  
KABI

caring for life

# AJNR

## **The use of stents in endovascular intervention.**

C A Jungreis

*AJNR Am J Neuroradiol* 1995, 16 (10) 1974-1976

<http://www.ajnr.org/content/16/10/1974.citation>

This information is current as  
of May 6, 2024.

### The Use of Stents in Endovascular Intervention

Charles A. Jungreis, *Chief, Division of Neuroradiology, Associate Professor of Radiology and Neurological Surgery, University of Pittsburgh (Pa) Medical Center*

The preceding two articles, by Massoud and colleagues (1) and by Geremia and colleagues (2), are important for several reasons. Taken on a very practical level, they point out some of the ongoing technical developments and technical difficulties that are mainstream to the practice of interventional neuroradiology. Decisions regarding the endovascular treatment of arteriovenous malformations and fistulas and the treatment of intracranial aneurysms confront the interventionalist daily. For example, debates continue regarding the “best” treatment for giant internal carotid artery aneurysms (3–9). Treatments have included common carotid artery sacrifice, internal carotid artery sacrifice, microneurosurgical clippings, and resection of the aneurysm, to name a few. Whether or not bypass grafting is necessary in a given case is equally disputed, and methods for making such a determination including clinical test occlusions, cerebral blood flow measurements, and angiographic criteria are not accepted universally (10, 11). Thus, the interventionalist would welcome a safe, proven, direct solution.

Taken on a different level, however, the preceding articles are good examples of how our practices must be established in the future. Investigations with scientific method must be mainstream to neuroradiology and to medicine in general. The era of simply reporting some experiences with a particular device or of treatment of a particular entity can no longer be accepted as evidence or proof of a successful practice. Many physicians, including those in our own field, have been guilty of failing to approach the issues with scientific method. For example, despite enormous amounts of clinical data, the Food and Drug Administration will not approve the use of detachable silicone balloons. The challenge has been to prove in a scientific fashion with controls, the effectiveness, the

long-term outcomes, and the complications. Similarly, despite many observations that acute revascularization of occluded middle cerebral arteries results in a better outcome in the stroke patient, well-thought-out controlled studies are required before the federal regulators, the insurance companies, and the medical community as a whole will approve of such intervention. We should not be surprised at such requirements, because our field has evolved into a legitimate subspecialty with specialty board examinations.

Returning to the preceding two papers, perhaps their most important contribution is their methodology, although some flaws are present. A summary of the paper by Massoud and colleagues includes the fact that a swine model for a fusiform aneurysm was developed. Ingeniously, the authors transplanted a short segment of the external jugular vein into the common carotid artery and then anastomosed the nearby ascending cervical artery to the side of the newly formed aneurysm (vein graft) via an end-to-side anastomosis. This model simulates a fusiform aneurysm with a side branch coming off the fusiformly dilated portion of the vessel. The authors then placed endovascular stents across the aneurysm. They tried to decrease the free lumen between the outside of the stent and the inside of the aneurysm lumen by adding endovascular coils in a pattern designed to obliterate the aneurysm lumen but to maintain the patency of the side branch. The authors admit encountering numerous difficulties including massive enlargement of one aneurysm and occlusion of the side branch in another. They also had difficulty fluoroscopically determining when coils had been correctly positioned, particularly after several already had been deposited. The authors recognize that no long-term follow-up was included. Other issues not addressed by the data include the likelihood

---

Address reprint requests to Charles A. Jungreis, MD, Department of Radiology, University of Pittsburgh Medical Center, 200 Lothrop St, Pittsburgh, PA 15213.

**Index terms:** Interventional instruments, stents; Interventional neuroradiology, standards; Commentaries

in vivo of encountering intraluminal thrombi of various ages with the usual concern for potential embolic complications. Still, the model is a fine attempt to simulate the giant aneurysms with side branches that occur in the cerebral vasculature.

In the report by Geremia and colleagues, a canine model was developed in which the common carotid and external jugular vein were anastomosed side to side thereby creating an arteriovenous fistula. Endovascular stents were placed within the artery across the fistula and observed for as long as 2 months both with angiography and with histologic analysis. The histologic findings included development of fibrous connective tissue and collagen within the fistula and a thin layer of endothelium that developed over the stent and the underlying connective tissue, an important observation. However, no controls were used; that is, no fistulas were created in which only observation occurred. Therefore, one cannot conclude unequivocally that the stents were the factor causing the majority of the fistulas to close. Nevertheless, experimentation on a nicely constructed model is admirable.

A clinical problem has been addressed in each paper. In the first paper by Massoud and colleagues, the authors have considered the current frustrations of treating a giant fusiform aneurysm of the craniocervical circulation. They have developed an animal model in which a technique can be evaluated that could obliterate the aneurysm with maintenance of both the parent vessel lumen and a side branch. In the paper by Geremia and colleagues, arteriovenous fistulas were developed in an animal model and then were treated with stents. Never mind that the treatment was not perfect in either case. Never mind that controls were not included in these initial feasibility studies. The point is that as a first step in evaluation, some thoughtful "bench-top" data are being accumulated. The actual devices being tested will no doubt be changed and improved and will probably be obsolete in short order (Fig 1). Yet such data will be essential before the next phase of investigation can begin.

The next phase will require a different design with different goals. Modifications of the devices no doubt will be considered. Perhaps additional animal studies will be required. Finally, controlled human studies will be appropriate. Still, these early investigations are necessary to be-

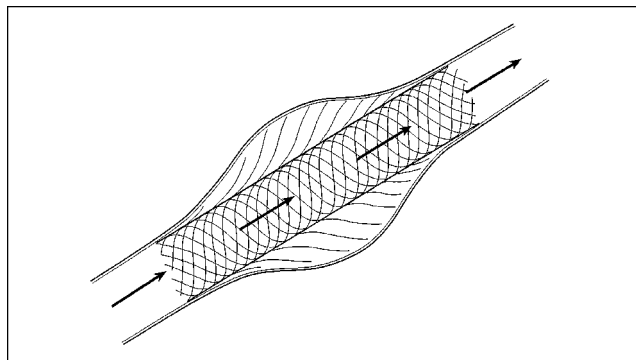


Fig 1. Artists' conception of a future endovascular stent. Radially directed fibers and/or coils are supposed to thrombose the portion of the lumen of the fusiform aneurysm that is outside the stent while preserving the patency of the lumen inside the stent.

gin the process and should be strongly encouraged and supported.

Significant obstacles remain for both the authors and the neuroradiology community as a whole. Although stent technology has become a commonly applied method in peripheral vascular procedures and in the coronary arteries, the application of these endovascular techniques to the cerebral circulation lags behind. There are several good reasons for this, including the great tortuosity of the vessels leading intracranially and the morbidity and mortality of thromboembolic complications, a less devastating consequence in the nonneurological circulations.

I applaud the authors on their determination to provide hard data on which to build. The interventional neuroradiologist no longer can afford to maintain an anecdotal forum. Investigations might begin with a single case or a short series but should evolve into bench-top or animal investigations when appropriate. These in turn should evolve into clearly defined controlled clinical investigations. Only then can new treatments and devices be endorsed. These two reports are a good start. Much work remains.

## References

1. Massoud TF, Turjman F, Ji C, et al. Endovascular treatment of fusiform aneurysms with stents and coils: technical feasibility in a swine model. *AJNR Am J Neuroradiol* 1995;16:1953-1963
2. Geremia G, Bakon M, Brennecke L, Haklin M. Experimental arteriovenous fistulas: treatment with porous metallic stents. *AJNR Am J Neuroradiol* 1995;16:1965-1973

3. Debrun G, Fox A, Drake C, Peerless S, Girvin J, Ferguson G. Giant unclippable aneurysms: treatment with detachable balloons. *AJNR Am J Neuroradiol* 1981;2:167-173
4. Berenstein A, Ransohoff J, Kupersmith M, Flamm E, Graeb D. Transvascular treatment of giant aneurysms of the cavernous carotid and vertebral arteries. *Surg Neurol* 1984;21:3-12
5. Fox AJ, Vinuela F, Pelz DM, et al. Use of detachable balloon for proximal artery occlusion in the treatment of unclippable cerebral aneurysms. *J Neurosurg* 1987;66:40-46
6. Swearingen B, Heros RC. Common carotid occlusion for unclippable carotid aneurysms: an old but still effective operation. *Neurosurgery* 1987;21(3):288-294
7. Weil SM, van Loveren HR, Tomsick TA, Quallen BL, Tew JM. Management of inoperable cerebral aneurysms by the navigational balloon technique. *Neurosurgery* 1987;21:296-302
8. Higashida RT, Halbach VV, Dowd C, et al. Endovascular detachable balloon embolization therapy of cavernous carotid artery aneurysms: results in 87 cases. *J Neurosurg* 1990;72:857-863
9. Linskey ME, Sekhar LN, Horton JA, Hirsh WL, Yonas H. Aneurysms of the intracavernous carotid artery: a multidisciplinary approach to treatment. *J Neurosurg* 1991;75:525-534
10. Serbinenko FA, Filatov JM, Spallone A, Tchurilov MV, Lazerev VA. Management of giant intracranial ICA aneurysms with combined extracranial-intracranial anastomosis and endovascular occlusion. *J Neurosurg* 1990;73:57-63
11. Linskey ME, Jungreis CA, Yonas H, et al. Stroke risk after abrupt internal carotid artery sacrifice: accuracy of preoperative assessment with balloon test occlusion and stable xenon-enhanced CT. *AJNR Am J Neuroradiol* 1994;15:829-843