

Are your **MRI contrast agents** cost-effective?

Learn more about generic **Gadolinium-Based Contrast Agents**.



FRESENIUS
KABI

caring for life

AJNR

The temporal bone.

J D Swartz, D L Daniels, H R Harnsberger, K A Shaffer and L Mark

AJNR Am J Neuroradiol 1995, 16 (10) 2081-2084

<http://www.ajnr.org/content/16/10/2081.citation>

This information is current as
of May 4, 2024.

The Temporal Bone

Joel D. Swartz, David L. Daniels, H. Ric Harnsberger, Katherine A. Shaffer, and Leighton Mark

Despite the advent of thin-section high-resolution computed tomography and, more recently, unique magnetic resonance imaging sequences with thin sections, T2 weighting, and maximum-intensity projection techniques, three-dimensional neuroanatomy of the temporal bone and related structures remains somewhat of an enigma to many medical specialists, neuroradiologists included. Therefore, we are undertaking a series of anatomic moments in the hope of solidifying the most important anatomic concepts as they relate to this region. Our approach will be organized so as to consider the temporal bone to represent the complex interrelationship of three systems: hearing, balance, and related neuroanatomic and neurovascular structures.

The ear originated in fish as a water motion detection system (1). The vestibular (balance) mechanism becomes more complex as we scale the embryologic ladder and endolymph replaces sea water as the essential fluid. The semicircular canals and utricle are phylogenetically older than the saccule and cochlear duct. As such, hearing developed as we evolved from aquatic to terrestrial organisms. Considering these basic facts, it is not surprising that developmental malformations are substantially more common in the neolabyrinth (cochlear duct and saccule) than in the paleolabyrinth (semicircular canals and utricle).

When considering evolutionary mechanisms, one also should appreciate that the tympanomastoid compartment represents the functional adaptation of the aquatic gill and that the ossicular chain probably developed because sea water was no longer available to serve as a conductive medium (1). Thus, the tympanomastoid compartment essentially represents a reestablishment of a continuity between

the inner ear structures and the external environment.

Virtually all textbooks define the inner ear as a membranous labyrinth housed within an osseous labyrinth. The membranous labyrinth contains endolymph, a fluid rich in potassium and low in sodium, similar to intracellular fluid. Interposed between the membranous labyrinth and the osseous labyrinth resides a supportive perilymphatic labyrinth. Perilymph is similar to cerebrospinal fluid and other extracellular tissue fluid.

The osseous labyrinth consists of the bony edifice for the vestibule, semicircular canals, cochlea, and vestibular aqueduct. The membranous labyrinth consists of the utricle and saccule (located within the vestibule), the semicircular ducts, the cochlear duct, and the endolymphatic duct. The latter is a channel within the vestibular aqueduct with communications to the utricle and saccule. The endolymphatic duct terminates in the endolymphatic sac, which resides within a bony fovea on the posterior surface of the petrous bone. Perilymph is interposed between the inner surface of the semicircular canals and ducts, between the inner lining of the bony vestibule and the utricle and saccule, and between the endolymphatic duct and the vestibular aqueduct.

The cochlea has been described countless times in the literature as containing between $2\frac{1}{2}$ and $2\frac{3}{4}$ turns, with the apex directed anteriorlaterally. The uncoiled cochlea is 30 to 32 mm in length and consists of three parallel fluid-containing channels. The central channel is the membranous cochlear duct (scala media), which is filled with endolymph and contains the primary sense organ for hearing, the organ of Corti, firmly embedded within the basilar membrane (1, 3). The cochlear duct is separated

From the Department of Radiology, Germantown Hospital and Medical Center, Philadelphia, Pa (J.D.S.); the Section of Neuroradiology, Medical College of Wisconsin, Milwaukee (D.L.D., K.A.S., L.M.); and the Department of Radiology, the University of Utah, Salt Lake City (H.R.H.).

Address reprint requests to David L. Daniels, MD, Neuroradiology Section, Department of Radiology/DH151, Doyne Clinic, Medical College of Wisconsin, 8700 W Wisconsin Ave, Milwaukee, WI 53226.

Index terms: Temporal bone, anatomy; Anatomic moments

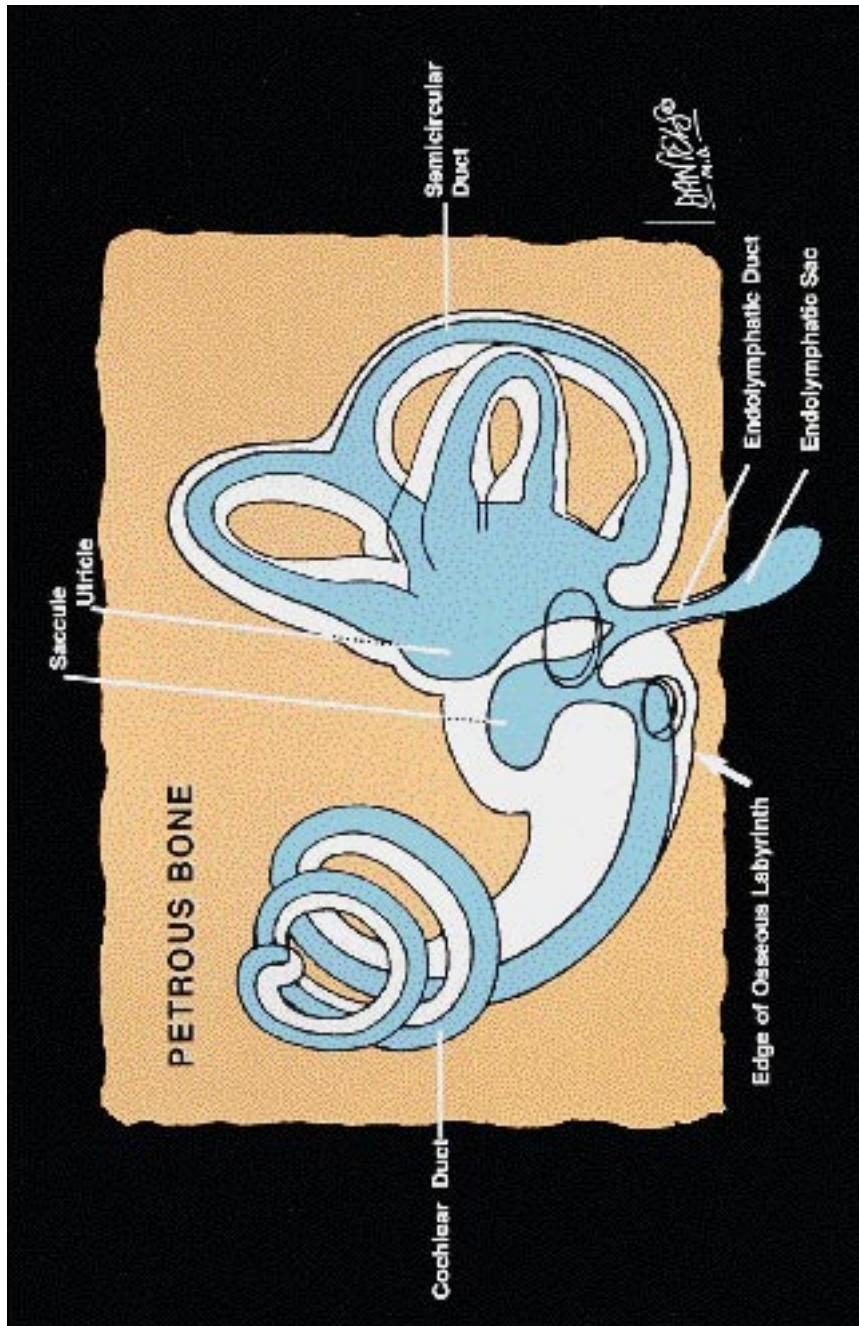


Fig 1. Schematic diagram of the endolymph-containing membranous labyrinth (blue) within the osseous labyrinth. The space (white) surrounding the membranous labyrinth contains perilymph. Modified from Williams et al (4) and Fomer (5).

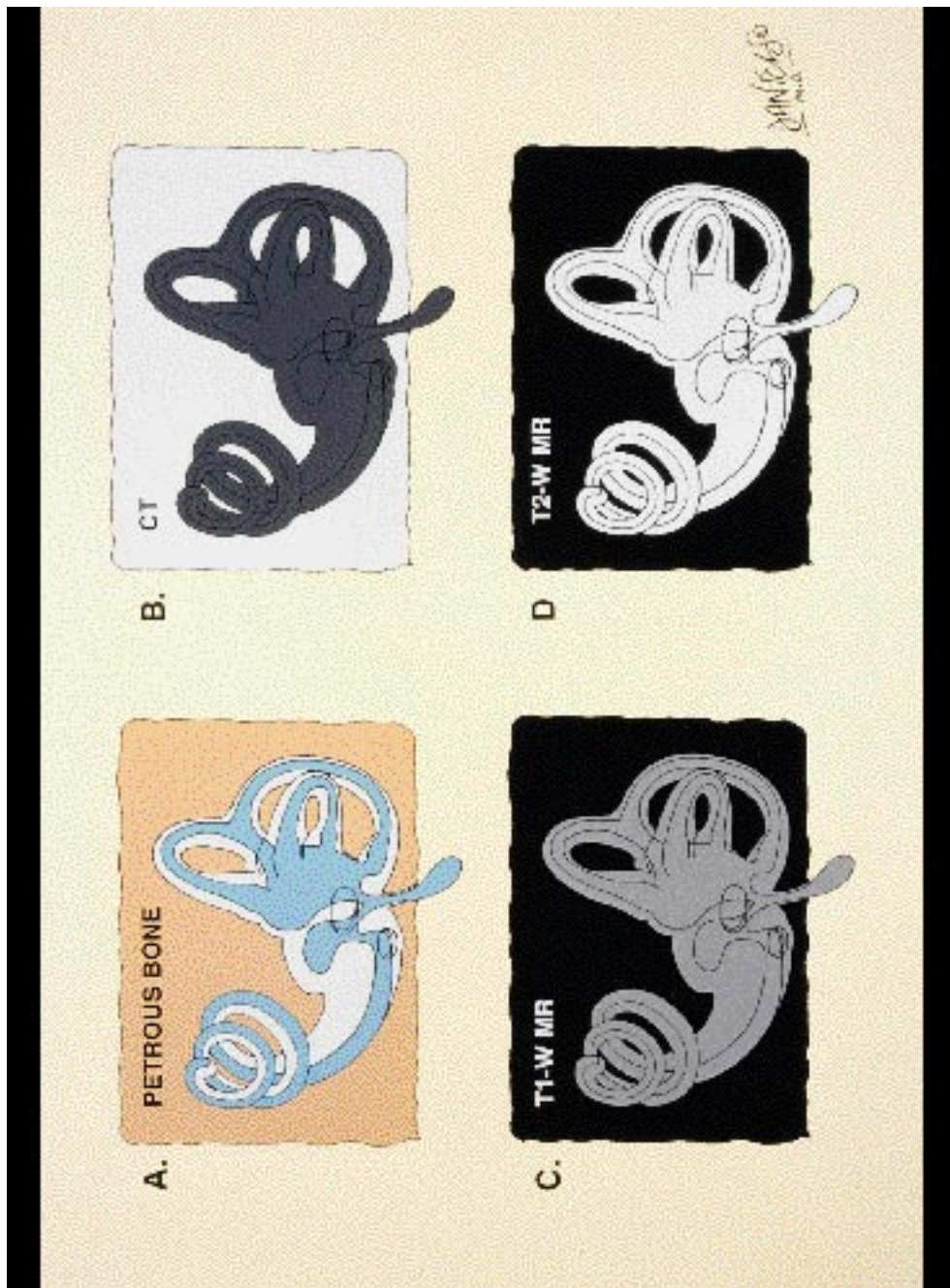


Fig 2. A-D, Schematic diagrams of the petrous bone and osseous labyrinth. Endolymph and perilymph are differentiated from the petrous bone, which has a high density on computed tomography (B) and negligible signal on T1-weighted (T1-W) (C) and T2-weighted (T2-W) (D) MR. In D, endolymph and perilymph have high signal intensity.

from the perilymph-containing scala tympani by this membrane and from the perilymph-containing scala vestibuli by Reissner's membrane.

With computed tomography, the bony labyrinth is differentiated from the membranous labyrinth and labyrinthine fluid by its bone density. The bony labyrinth perhaps has the highest attenuation numbers of any area of the body. With magnetic resonance, endolymph and perilymph fluid signal allows differentiation from the surrounding low signal of the bony labyrinth.

The initial contributions to this series of anatomic moments will focus primarily on anatomic and physiologic issues as they pertain specifically to hearing or balance.

References

1. Bergeron RT. In: Bergeron RT, Som PM, eds. *Head and Neck Imaging, III*. St Louis: Mosby; 1992
2. Schuknecht HF, Gulya AJ. *Anatomy of the Temporal Bone with Surgical Implications*. Philadelphia: Lea and Febiger; 1986
3. Daube JR, Reagan TJ, Sandok BA, Westmoreland BF. *Medical Neurosciences: An Approach to Anatomy, Pathology and Physiology by Systems and Levels*. New York, NY: Little Brown and Co, 1986; 357-365
4. Williams PL, Warwick R, Dyson M, Bannister LH, eds. *Gray's Anatomy, 37th ed*. London: Churchill Livingstone; 1989
5. Ferner H, ed. *Pernkopf Atlas of Topographical and Applied Human Anatomy*. Baltimore, Md: Urban and Schwarzenberg; 1980