

Are your **MRI contrast agents** cost-effective?

Learn more about generic **Gadolinium-Based Contrast Agents**.



FRESENIUS
KABI

caring for life

AJNR

MR in neurofibromatosis of the larynx.

D S Martin, J Stith, E E Awwad and S Handler

AJNR Am J Neuroradiol 1995, 16 (3) 503-506

<http://www.ajnr.org/content/16/3/503>

This information is current as
of May 4, 2024.

MR in Neurofibromatosis of the Larynx

David S. Martin, John Stith, Eric E. Awwad, and Steven Handler

Summary: We report the MR results of four patients with plexiform neurofibromas of the larynx. Three had irregular margins and were circumferential around the airway. The distinction between regularly and irregularly shaped neurofibromas may have implications for symptom onset.

Index terms: Neurofibromatosis; Larynx, magnetic resonance; Larynx, neoplasms

A recent review of the literature (Stith JA, "Neurofibroma of the Larynx," presented at the 8th Annual Meeting of the American Society of Pediatric Otolaryngology, April 19–22, 1993, Los Angeles, Calif) indicated 45 published cases of neurofibromas involving the larynx. In one of the previous cases, the magnetic resonance (MR) imaging findings have been described (1). We have obtained MR studies of four patients with known neurofibromatosis type 1 with involvement of the larynx. The purpose of this report is to review the MR features of these tumors and to add an additional clinically relevant observation.

Case Reports

Case 1

A 3½-year-old boy presented with inspiratory stridor. He was known to have neurofibromatosis type 1 with multiple café au lait spots greater than 1 cm and axillary freckling. Laryngoscopy demonstrated a laryngeal mass. MR imaging demonstrated a supraglottic mass with indistinct peripheral margins narrowing the airway (Fig 1). The T1 relaxation time of the lesion was isointense to adjacent muscle. Its T2 relaxation time was prolonged and it enhanced brightly. This was a biopsy-proved plexiform neurofibroma.

Case 2

A 4-year-old girl presented with stridor and obstructive sleep apnea. She had multiple café au lait spots. MR imaging was performed at 0.35 T (Fig 2). There was an indistinctly margined circumferential laryngeal mass. The T2 relaxation time of the mass was prolonged and the T1 was isointense or slightly shortened relative to adjacent muscle. Subsequent biopsy showed this to be a plexiform neurofibroma.

Case 3

A 6½-year-old boy presented with worsening stridor. He was known to have neurofibromatosis type 1 with axillary freckling, a café au lait spot, and multiple cutaneous neurofibromata. MR imaging at 1.5 T was performed to evaluate the larynx (Fig 3). A supraglottic mass with a prolonged T2 relaxation time and an isointense T1 relaxation time was demonstrated, which proved on subsequent biopsy to be a plexiform neurofibroma.

Case 4

A 7-year-old boy was undergoing preoperative evaluation before excision of a peripheral neurofibroma, when an asymptomatic laryngeal mass was discovered. His manifestation of neurofibromatosis was multiple café au lait spots greater than 1 cm and a peripheral neurofibroma. An MR scan was obtained at 0.35 T (Fig 4). The mass was nearly isointense to skeletal muscle on short-repetition-time/short-echo-time images and was hyperintense on long-repetition-time/long-echo-time images. He did well clinically for approximately 1½ years. He subsequently began to have some nocturnal stridor. The lesion was excised and found to be a plexiform neurofibroma.

Discussion

Previously, the MR signal characteristics of plexiform neurofibromas of the spine have been described (2). All four of the present laryngeal tumors exhibited the same marked T2 prolon-

Received February 12, 1993; accepted after revision April 28.

From the Departments of Radiology (D.S.M., E.E.A.) and Otolaryngology Head and Neck Surgery (J.S.), St Louis (Mo) University Medical Center; and the Department of Otolaryngology Head and Neck Surgery, University of Pittsburgh, Pa (S.H.).

Address reprint requests to David S. Martin, MD, Department of Radiology, St Louis University Medical Center, 3635 Vista at Grand, PO Box 15250, St Louis, MO 63110-0250.

AJNR 16:503–506, Mar 1995 0195-6108/95/1603-0503 © American Society of Neuroradiology




Fig 1. Case 1.

A, Precontrast axial T1-weighted image at 1.5 T (800/45/1 [repetition time/echo time/excitations]). The thyroid lamina (*curved arrow*) is seen anteriorly. The mass (*arrows*) circumferentially narrows the airway (*arrowhead*). A second neurofibroma is seen in the posterior cervical muscles on the right.

B, Proton-density axial scan (3000/30/1).

C, Axial T1-weighted post-gadopentetate dimeglumine image (801/22/1).




Fig 2. Case 2. Axial T1-weighted noncontrast MR imaging at 0.35 T (650/20/3). There is an ill-defined mass (*arrowheads*) isointense to muscle narrowing the airway. The thyroid lamina is marked with the *curved arrow*.




Fig 3. Case 3. Axial proton-density image post-gadopentetate dimeglumine (2500/30/1) demonstrates a poorly margined supraglottic mass narrowing the airway (*X*). An adjacent neurofibroma is also visible on the left in the carotid space.




Fig 4. Case 4.

A, Axial T1-weighted noncontrast MR image at 0.35 T (500/20/4) demonstrates a well-circumscribed lesion (*M*) protruding into the airway at the level of the aryepiglottic fold (*arrow*).

B, Axial T2-weighted image (1800/75/2) shows marked T2 prolongation.

gation and variable T1 shortening as neurofibromas elsewhere. However, the prominent central areas of T2 shortening reported as areas of fibrous tissue in spinal plexiform neurofibromas were not visible in our laryngeal lesions.

Three of the biopsy-proved plexiform lesions had margins that blended imperceptibly into adjacent normal tissue. The lesions surrounded the airway even when the bulk of the tumor was asymmetric. These three patients had early airway compromise.

The nodular-shaped neurofibroma deformed the airway by protruding into it. Its margins were sharp. The mass appeared to arise from one edge of the larynx.

The unique appearance and clinical behavior of three of the four lesions suggests that shape may correlate with early onset of symptoms. However, as case 4 shows, it is not a predictor of histologic findings.

All our cases of laryngeal neurofibroma associated with neurofibromatosis type 1 were plexiform. The plexiform neurofibroma is histologically identical but architecturally dissimilar to the solitary nodular type (3). By its infiltrating nature, a plexiform lesion is more demanding surgically, is more likely to be incompletely removed, and has a higher rate of recurrence. The histologic similarity of the plexiform and nodular type neurofibromas explains their equivalent signal patterns. However, the propensity of the plexiform type to insinuate itself into adjacent tissue accounts for the indistinctness of the margins and the annular appearance surrounding and constricting the airway in three of our four cases. The deceptively visible margin in case 4 may exist because it was silhouetted against air.

In our patients, the axial images provided a cross-section through the tumor margin. In the axial plane, we were able to make the distinction between smooth and infiltrating margins as well as to demonstrate the circumferential or nodular appearance of the lesions. MR images in the axial plane displayed the circumferential or nodular appearance of the lesions to greatest advantage. The coronal plane could assist in demonstrating transglottic infiltration. Inasmuch as the signal pattern does not differentiate plexiform and nodular neurofibromas and T2-weighted images are time-inefficient, T1-weighted axial and coronal images may be sufficient to display the abnormalities. In the single instance (case 2) in which both computed tomography and MR were done, the tumor margin was more apparent on MR.

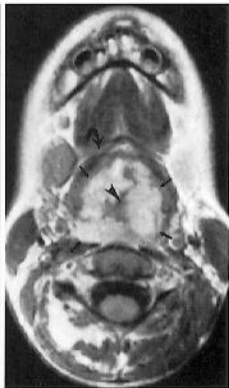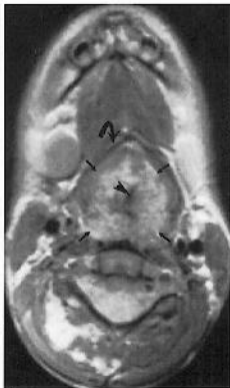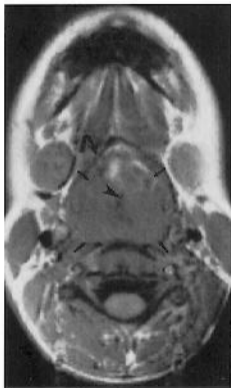Conclusion

There is an association between neurofibromatosis type 1 and plexiform neurofibromas of the larynx. Analysis of the margins of neurofi-

bromas of the larynx associated with neurofibromatosis type 1 may help predict clinical behavior.

References

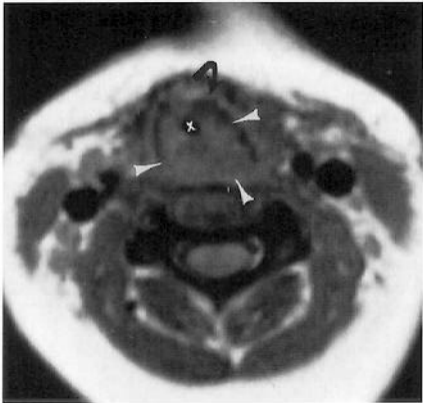
1. Yousem DM, Oberholtzer C. Neurofibroma of the aryepiglottic fold. *AJNR Am J Neuroradiol* 1991;12:1176-1178
2. Burk DL, Burnberg JA, Kanal E, Latchaw RE, Wolf GL. Spinal and paraspinal neurofibromatosis: surface coil MR imaging at 1.5 T. *Radiology* 1987;162:797-801
3. Burger PC, Scheithauer BW, Vogel FS. *Surgical Pathology of the Nervous System and Its Coverings*. 3rd ed. New York: Churchill Livingstone Inc, 1991:685-695

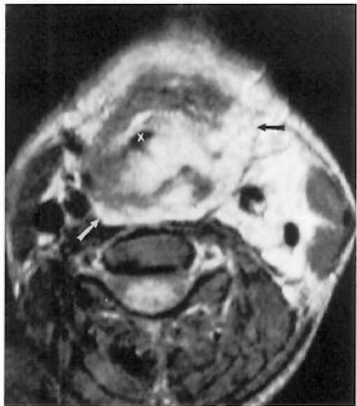


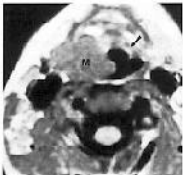A

B

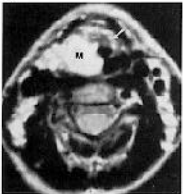
C







A



B