

Are your **MRI contrast agents** cost-effective?

Learn more about generic **Gadolinium-Based Contrast Agents**.



FRESENIUS  
KABI

caring for life

# AJNR

## **Clinical significance of asymmetry of the fornix and mamillary body on MR in hippocampal sclerosis.**

J H Kim, R D Tien, G J Felsberg, A K Osumi and N Lee

*AJNR Am J Neuroradiol* 1995, 16 (3) 509-515

<http://www.ajnr.org/content/16/3/509>

This information is current as of May 10, 2024.

# Clinical Significance of Asymmetry of the Fornix and Mamillary Body on MR in Hippocampal Sclerosis

Jae Hyoung Kim, Robert D. Tien, Gary J. Felsberg, Alan K. Osumi, and Namsoo Lee

**PURPOSE:** To investigate the clinical significance of MR-defined asymmetry of the fornix and mamillary body for presurgical determination of the side of hippocampal sclerosis in patients with temporal lobe epilepsy. **METHODS:** Fast spin-echo MR images were evaluated for evidence of an asymmetrically small fornix and mamillary body in 33 patients with pathologically proved hippocampal sclerosis (presurgical hippocampal sclerosis group), 7 patients who had undergone anterior temporal lobectomy (mean, 3 years from surgery) because of hippocampal sclerosis (postsurgical hippocampal sclerosis group), and 34 healthy subjects (control group). Fast spin-echo hippocampal volumetry was performed in each patient. **RESULTS:** In the control group, 6% (2 of 34) of subjects had MR evidence of asymmetrically small fornix and none (0 of 34) of the subjects had asymmetrically small mamillary body. In the patient population, an asymmetrically small fornix was seen in 42% of presurgical hippocampal sclerosis group, 39% (13 of 33) ipsilateral, and 3% (1 of 33) contralateral, and in 71% of the postsurgical hippocampal sclerosis group (5 of 7), all ipsilateral. In the presurgical hippocampal sclerosis group, hippocampal atrophy measured with MR was more severe in patients with an ipsilaterally small fornix than in patients without. An asymmetrically small mamillary body was found ipsilaterally in 3% (1 of 33) of the presurgical hippocampal sclerosis group and in 57% (4 of 7) of the postsurgical hippocampal sclerosis group; all patients with an asymmetrically small mamillary body in the postsurgical hippocampal sclerosis group also had an asymmetrically small fornix on the same side. **CONCLUSION:** In presurgical hippocampal sclerosis patients, an asymmetrically small fornix can be seen ipsilaterally on the side of the hippocampal sclerosis; however, its low frequency, its association with severe hippocampal atrophy only, and the possibility of false-positive results limit its clinical usefulness in determining the side of the seizure focus. An asymmetrically small mamillary body is too rare to be used for presurgical location of hippocampal sclerosis. However, an asymmetrically small fornix and mamillary body are frequently seen on MR images after temporal lobectomy.

**Index terms:** Seizures; Sclerosis, hippocampal; Brain, asymmetry/dissymmetry; Brain, magnetic resonance

*AJNR Am J Neuroradiol* 16:509–515, March 1995

Hippocampal sclerosis is an entity of neuronal loss with gliosis involving the hippocampus and is the most common disease associated with intractable temporal lobe epilepsy. Temporal lobectomy is a widely accepted surgical treatment for patients with hippocampal sclero-

sis; before surgery, it is essential to determine the side of (“lateralize”) the abnormal hippocampus. Magnetic resonance (MR) imaging has been shown to be a useful diagnostic tool in depicting the hippocampal abnormalities (atrophy and/or increased T2 signal of the hippocampus) associated with hippocampal sclerosis and therefore, in lateralizing the seizure focus (1–4).

The hippocampus, fornix, and mamillary body are components of a single limbic circuit; the hippocampal fibers project to the mamillary body via the fornix. It has been previously suggested that neuronal damage of the hippocampus including the subiculum may cause atrophy

---

Received April 19, 1994; accepted after revision August 15.

From the Departments of Radiology (J.H.K., R.D.T., G.J.F., A.K.O.) and Neurology (N.L.), Duke University Medical Center, Durham, NC.

Address reprint requests to Robert D. Tien, MD, Section Head, Neuro-radiology, Department of Radiology, Box 3808, Duke University Medical Center, Erwin Road, Durham, NC 27710.

*AJNR* 16:509–515, Mar 1995 0195-6108/95/1603-0509  
© American Society of Neuroradiology

of the ipsilateral fornix and mamillary body as a result of neuronal degeneration (5–7). Recently, MR detection of the asymmetrically small fornix (8) or mamillary body (9) has been suggested as a useful presurgical lateralizing sign of hippocampal sclerosis in patients with temporal lobe epilepsy.

The purpose of this study is to investigate the frequency and clinical significance of the asymmetrically small fornix and mamillary body in patients with hippocampal sclerosis by using fast spin-echo MR imaging in order to determine whether these findings may be used as a presurgical lateralizing MR sign in clinical practice.

## Materials and Methods

Two patient groups and one control group were included in this study. One patient group (presurgical hippocampal sclerosis group) consisted of 33 patients with pathologically proved hippocampal sclerosis; all had MR evidence of hippocampal sclerosis (hippocampal atrophy and/or increased T2 signal) and intractable temporal lobe epilepsy. There were 19 men and 14 women with a mean age of 31.5 years (range, 13 to 57). The other patient group (postsurgical hippocampal sclerosis group) included 7 patients who underwent anterior temporal lobectomy for the treatment of hippocampal sclerosis and then postoperative follow-up MR examinations. Time intervals between surgery and follow-up MR examination ranged from 5 days to 8 years (mean, 3 years). There were 3 men and 4 women with a mean age of 27 years (range, 17 to 40). The control group consisted of both volunteers and patients without clinical history of seizure or memory disturbance. There were 17 men and 17 women with a mean age of 33.8 years (range, 14 to 56).

All patients and control subjects were examined with conventional spin-echo MR imaging consisting of T1- and T2-weighted images in the axial plane and T1-weighted images in the oblique coronal planes. T1-weighted oblique coronal images were obtained with 500/16/1 (repetition time/echo time/excitations), 3-mm section thickness with interleaving, and 256 × 256 matrix. Additionally, T2-weighted fast spin-echo MR imaging designed for hippocampal evaluation was obtained in the oblique coronal plane with 4000/100/4, 2- to 3-mm thickness with interleaving, 256 × 256 matrix, and 16 echo train as previously reported (10).

In a blinded fashion, with exclusion of the hippocampal regions on the MR images, the fornix and mamillary body were visually evaluated by three neuroradiologists independently; final decisions were made by consensus. When evaluating the fornix, the size was evaluated on fast spin-echo coronal MR images by comparing the cross-sectional areas of both fornices at the levels of the rostral crus just posterior to the body of the fornix. At the level of the rostral crus, the fornix runs approximately perpendicular to the

scan plane of fast spin-echo MR imaging and both fornices can be well outlined separately. Therefore, the cross-sectional areas of both fornices can be accurately compared at this level with minimization of the partial volume effect. Results of the fornix evaluation were classified into equal size (both fornices being equal in size) (Fig 1) and asymmetrically small (one fornix being asymmetrically smaller than the other fornix) types. When evaluating the mamillary body, the size and position were evaluated on T1-weighted axial and coronal images and fast spin-echo coronal images by comparing both mamillary bodies. Results of the mamillary body evaluation were first classified into equal-size (both mamillary bodies being equal in size) and asymmetrically small (one mamillary body being asymmetrically smaller than the other mamillary body) types. Symmetric mamillary body was further classified into same-position (both mamillary bodies being same in position) and high-position (one mamillary body being higher than the other mamillary body in position) types (Fig 2). All cases of asymmetrically small fornix or mamillary body were correlated with the side of hippocampal sclerosis (in the presurgical hippocampal sclerosis group) or surgery (in the postsurgical hippocampal sclerosis group).

The frequency of asymmetrically small fornix and mamillary body was statistically compared among the control, presurgical hippocampal sclerosis, and postsurgical groups. To examine the relationship between the presence of an asymmetrically small fornix and the severity of hippocampal atrophy in the presurgical hippocampal sclerosis group, MR-based hippocampal volume ratios (diseased hippocampal volume to contralateral hippocampal volume) were statistically compared between patients with asymmetrically small fornix ipsilateral to the side of hippocampal sclerosis and patients with hippocampal sclero-




Fig 1. The fornices equal in size. The fornical size was evaluated on fast spin-echo coronal MR image (3-mm section thickness) by comparing the cross-sectional areas of both fornices at the level of the rostral crus of the fornix. Both fornices appear equal in size (arrows).




Fig 2. A, Different morphologic types of the mamillary body. Equal size (*left*): both mamillary bodies are equal in size and same in position. Asymmetrically small (*center*): one mamillary body is smaller (in height and width) than the other mamillary body. High position (*right*): one mamillary body is higher in position than the other mamillary body; however, both mamillary bodies are equal in size.

B, The mamillary bodies equal in size and same in position. Fast spin-echo coronal MR image (3-mm section thickness) at the level of the mamillary body shows both mamillary bodies (*arrows*) being equal in size and same in position.

sis but without evidence of ipsilaterally small fornix. Hippocampal volumetry was performed on fast spin-echo coronal images as previously reported (4) by a neuroradiologist experienced in MR volumetric techniques.

## Results

An asymmetrically small fornix was found in 6% (2 of 34) of the control group, 42% of the presurgical hippocampal sclerosis group, 39% (13 of 33) ipsilateral and 3% (1 of 33) contralateral (Fig 3), and in 71% (5 of 7) of the postsurgical hippocampal sclerosis group, all ipsilateral (Fig 4A). The frequency of an asymmetrically small fornix ipsilateral to the side of hippocampal sclerosis or temporal lo-




Fig 3. Asymmetrically small fornix in a patient with hippocampal sclerosis. On fast spin-echo coronal MR image (2-mm section thickness) at the level of the rostral crus of the fornix, the left fornix (*solid arrow*) appears smaller than the right fornix. The left hippocampus (*open arrow*) has abnormally high signal intensity and is smaller than the normal right hippocampus, suggesting hippocampal sclerosis.

nectomy in the presurgical hippocampal sclerosis group and the postsurgical hippocampal sclerosis group was statistically significantly higher than in the control group ( $\chi^2$  test and Fisher's Exact Test, respectively;  $P < .001$  in both). An asymmetrically small mamillary body was found in none (0 of 34) of the control group, in 3% (1 of 33, ipsilateral) of the presurgical hippocampal sclerosis group, and in 57% (4 of 7, all ipsilateral) of the postsurgical hippocampal sclerosis group (Fig 4B). The frequency of an asymmetrically small mamillary body in the postsurgical hippocampal sclerosis group was statistically significantly higher than in the control and presurgical hippocampal sclerosis groups (Fisher's Exact Test;  $P < .001$  and  $< .01$ , respectively). All patients (4 of 7) with an asymmetrically small mamillary body in the postsurgical hippocampal sclerosis group also had an asymmetrically small fornix on the same side. An asymmetrically small mamillary body seen in one patient (1 of 33) of the presurgical hippocampal sclerosis group was not accompanied by an asymmetrically small fornix.


In the postsurgical hippocampal sclerosis group, two patients with time intervals (between surgery and follow-up MR examination) of 5 days and 3 months, respectively, did not show an asymmetrically small fornix or mamillary body. Four patients with time intervals of 9 months, 4 years, 7 years, and 8 years, respectively, had an asymmetrically small fornix and mamillary body ipsilaterally. One patient with a time interval of 1.2 years had asymmetrically small fornix only.

As a subtype of the equal size mamillary body, high-position type was found in 6% (2 of 34) of the control group, in 9% (3 of 33) of the presurgical hippocampal sclerosis group (all

Fig 4. Asymmetrically small mamillary body and fornix in a patient with temporal lobectomy 8 years ago for presumed hippocampal sclerosis.

A, Fast spin-echo coronal MR image (3-mm section thickness) at the level of the mamillary body shows the left mamillary body (*arrow*) being smaller than the right mamillary body. The left temporal lobe including the hippocampus is in resected state.

B, At the level of the rostral crus of the fornix, the left fornix (*arrow*) appears much smaller than the right fornix.



contralateral), and in none (0 of 7) of the post-surgical hippocampal sclerosis group. High positioning of the mamillary body on coronal fast spin-echo MR images of the 5 patients (2 from the control group and 3 from the presurgical hippocampal sclerosis group) was not accurately delineated on T1-weighted axial and coronal images, mimicking an asymmetrically small mamillary body (Fig 5).

With respect to the relationship between the presence of an asymmetrically small fornix and the severity of hippocampal atrophy in the presurgical hippocampal sclerosis group, hip-

pocampal volume ratios quantitatively measured by MR were significantly smaller in patients with an asymmetrically small fornix ipsilateral to the side of hippocampal sclerosis ( $n = 13$ ) than in patients without that ( $n = 20$ ) (t-test, two-sided;  $P < .05$ ).

## Discussion

Two kinds of antegrade neuronal degeneration can occur when the neural pathway is disrupted because of pathologic abnormalities, wallerian degeneration, and transneuronal de-




Fig 5. High position of the mamillary body mimicking the asymmetrically small mamillary body.

A, Fast spin-echo coronal MR image (3-mm section thickness) at the level of the mamillary body shows the left mamillary body (*solid arrows*) being higher in position than the right mamillary body, but of equal size. The right hippocampal head (*open arrow*) has abnormally high signal intensity and is smaller than the normal left hippocampus, suggesting hippocampal sclerosis.

B, On T1-weighted coronal MR image (3-mm section thickness) at the same level, the outline of the left mamillary body (*arrow*) is not clearly defined, mimicking the asymmetrically small mamillary body.

C, On T1-weighted axial MR image (5-mm section thickness), the right mamillary body (*arrow*) is seen in normal size; however, the left mamillary body is not seen at this level, mimicking the asymmetrically small mamillary body.

generation (11). Wallerian degeneration occurs in the axon and myelin sheath when the proximal axon or its cell body is damaged; although it was first described in the peripheral nervous system (12), similar changes have been found in many pathologic conditions of the central nervous system (11, 13, 14). Transneuronal degeneration occurs in the postsynaptic neuron when synaptic input is disrupted (ie, deafferentation) because of disease of the presynaptic neuron; loss of neuropil and shrinkage or loss of nerve cell body are found histopathologically (11, 15). The end result of both types of degeneration is atrophy of the involved fiber tract and the postsynaptic neuron.

The hippocampus includes the cornu Ammonis, the dentate gyrus, and the subiculum, which constitute essential parts of a single limbic circuit. The fornix is a compact fiber bundle containing the efferent fibers originating from the hippocampus (16, 17). Therefore, neuronal damage of the hippocampus in hippocampal sclerosis may cause atrophy of the fornix and mamillary body as a consequence of previously described neuronal degenerations. However, the majority of the fornical fibers originate from the subiculum, not the cornu Ammonis, and project predominantly to the mamillary body via the postcommissural fornix, although some of the fibers project to the septal nuclei via the precommissural fornix (16–19). The remaining portion of the fornical fibers arise from the cornu Ammonis and terminate exclusively in the septal nuclei via the precommissural fornix (16–19). The dentate gyrus does not give rise to direct extrahippocampal projection (16, 17). Therefore, neuronal damage of the cornu Ammonis and dentate gyrus, without involving the subiculum as usually seen in hippocampal sclerosis, may not be enough to produce the substantial effect of wallerian degeneration in the fornix, and it is not likely to induce transneuronal degeneration in the mamillary body. The subiculum is not commonly affected in hippocampal sclerosis, although neuronal loss may occur to some extent in hippocampal sclerosis (20). Although the mean neuronal density of the subiculum is slightly lower in patients with hippocampal sclerosis than in control subjects, this difference is not statistically significant (N. Lee, unpublished data). Furthermore, the majority of the subicular efferent fibers do not traverse the fornix, but project to the adjacent entorhinal cortex and

then to other widespread cortical areas (5, 16). In our study, the asymmetrically small fornix and mamillary body were found ipsilaterally in 39% (13 of 33) and 3% (1 of 33) of patients with hippocampal sclerosis, respectively. Therefore, we do not consider the asymmetrically small fornix or mamillary body to be sensitive lateralizing signs of hippocampal sclerosis as opposed to the results of previous reports (8, 9) that have been studied with smaller patient and control populations than those in our study. However, after anterior temporal lobectomy, asymmetrically small fornix and mamillary body were found in 71% (5 of 7) and 57% (4 of 7) of patients, respectively. Therefore, recognizable atrophy of the fornix and mamillary body can be seen commonly in the postsurgical setting, because temporal lobectomy exaggerates the effect of neuronal degeneration as a result of massive neuronal loss in the medial temporal region (5).

Although an asymmetrically small fornix on MR images is not common in the presurgical hippocampal sclerosis cases of our study, its frequency was statistically significantly higher than in the control group. Also, the patients with hippocampal sclerosis and an asymmetrically small fornix had statistically significantly smaller hippocampal volume ratios than the patients with hippocampal sclerosis but without an asymmetrically small fornix. This result suggests a positive correlation between the amount of hippocampal neuronal loss and the presence of an asymmetrically small fornix although the fibers arising from the cornu Ammonis constitute a minor portion of the fornical fiber bundle. However, an asymmetrically small fornix was found in the contralateral side in 3% (1 of 33) of the presurgical hippocampal sclerosis group and, furthermore, it was found in 6% (2 of 34) of the control group. This suggests that an asymmetrically small fornix can be found as a normal variation.

We suggest that the deafferentation-producing mamillary body atrophy should produce fornical atrophy necessarily, because all of the fibers projecting to the mamillary body traverse the fornix, and these fibers constitute the majority of the fornical fibers. This hypothesis is supported by our results in that all asymmetrically small mamillary bodies found in the postsurgical hippocampal sclerosis group were accompanied by concordantly small fornix on the

same side. Therefore, the asymmetrically small mamillary body not accompanied by the concordantly small fornix seen in one patient of the presurgical hippocampal sclerosis group may be a normal variation.

That subicular damage is considered a major cause of the mamillary body atrophy has been also supported by several recent clinical reports (6, 7). Two autopsy cases of mamillary body atrophy have been identified in association with previous ischemic damage of the hippocampus (7). Ischemic damage causes extensive neuronal loss in the subiculum as well as the cornu Ammonis (19), unlike that found in hippocampal sclerosis, allowing much more of a deafferentation effect on the mamillary body. Two MR cases of mamillary body atrophy accompanying hippocampal atrophy in patients with temporal lobe amnesia have been reported in which the role of subicular involvement in hippocampal damage of amnesic patients was suggested as a mechanism of the mamillary body atrophy (6).

Congenital morphologic abnormalities of the mamillary body including hypoplasia or agenesis have been rarely reported in autopsy cases usually in association with other cerebral malformations (21–23). In our study, several cases of asymmetric positioning but equal size of the mamillary body were found independent of hippocampal disease or seizure disorder. Interestingly, asymmetric positioning was more easily identified on T2-weighted coronal fast spin-echo MR images than on conventional spin-echo T1-weighted images, likely because of the improved delineation of the mamillary bodies by the extremely T2-weighted technique and by improved contrast between gray and white matter. This morphologic abnormality of the mamillary body may occur, as a normal variation, by disturbances in certain morphogenetic periods of the mamillary body without other accompanying cerebral malformations (21).

Recently, three cases of the mamillary body asymmetry on MR images were reported in seizure patients (9). One case consisted of unilateral absence of the mamillary body ipsilateral to the side of seizure focus in patient with presumed temporal lobe epilepsy, but without MR evidence of hippocampal abnormality. The relationship of the mamillary body atrophy and the seizure disorder is unclear in this case, although based on the current concepts of neuro-

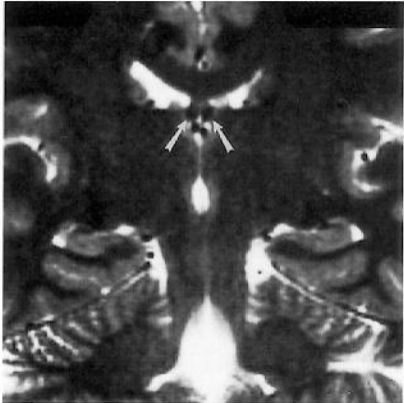
nal pathway the mamillary body may have an important role in seizure propagation (24). Another case showed an unilateral absent mamillary body in a patient with a long history of unspecified seizures with gross atrophy of the ipsilateral hippocampus and old occipital infarct. In this case, the absence of the mamillary body may have been caused by ischemic damage, because there was a coexistent old occipital infarct; however, microscopic evaluation of the hippocampus was not performed. The final case showed asymmetrically small mamillary body ipsilateral to gross hippocampal atrophy in a patient with hippocampal sclerosis pathologically. In this case, the fornices seen on the coronal MR images published appear to be symmetric, although this was not mentioned in the report. This may suggest that the asymmetrically small mamillary body in this patient may be a normal variation independent of hippocampal sclerosis, because most of the mamillary body atrophy secondary to hippocampal or temporal disease perhaps will not occur without the concordant fornical atrophy. Therefore, two of three mamillary body abnormalities (the first and third cases) in this report may represent normal variations that do occur in the healthy population.

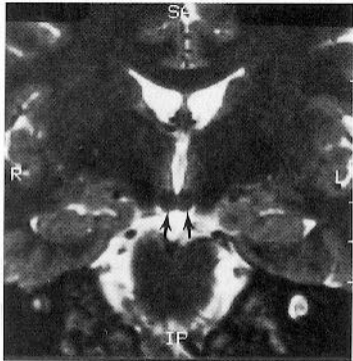
Coronal T2-weighted fast spin-echo MR imaging enables accurate depiction of fornix and mamillary body morphology as well as evaluation of the hippocampus. Based on the results of our study with 74 patients and control subjects, an asymmetrically small fornix can be seen in patients with hippocampal sclerosis, reflecting fornical atrophy as a result of wallerian degeneration caused by hippocampal neuronal loss. However, its role in lateralizing the seizure focus is limited by its low frequency of occurrence, potential false-positivity, and its association with severe hippocampal atrophy only. The role of an asymmetrically small mamillary body for presurgical lateralization of hippocampal sclerosis is much more limited by its rare occurrence in presurgical cases of hippocampal sclerosis. However, an asymmetrically small fornix and mamillary body are frequently seen after temporal lobectomy, reflecting fornical and mamillary body atrophy occurring secondary to wallerian degeneration and deafferentation after the widespread neuronal loss inherent in temporal lobectomy.

## References

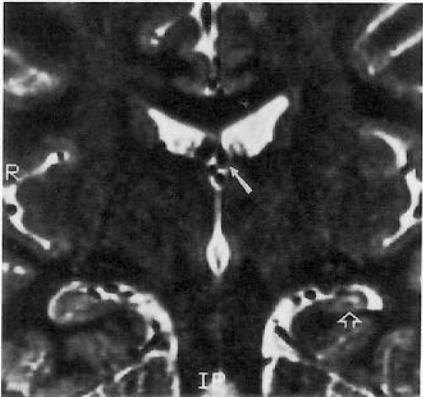
1. Kuzniecky R, de la Sayette V, Ethier R, et al. Magnetic resonance imaging in temporal lobe epilepsy: pathological correlations. *Ann Neurol* 1987;22:341-347
2. Jack CR Jr, Sharbrough FW, Twomey CK, et al. Temporal lobe seizures: lateralization with MR volume measurements of the hippocampal formation. *Radiology* 1990;175:423-429
3. Bronen RA, Cheung G, Charles JT, et al. Imaging finding in hippocampal sclerosis: correlation with pathology. *AJNR Am J Neuroradiol* 1991;12:933-940
4. Tien RD, Felsberg GJ, de Castro CC, et al. Complex partial seizures and mesial temporal sclerosis: evaluation with fast spin-echo MR imaging. *Radiology* 1993;189:835-842
5. Zola-Morgan S, Squire LR, Amaral DG. Lesions of the hippocampal formation but not lesions of the fornix or the mamillary nuclei produce long-lasting memory impairment in monkeys. *J Neurosci* 1989;9:898-913
6. Squire LR, Amaral DG, Press GA. Magnetic resonance imaging of the hippocampal formation and mamillary nuclei distinguish medial temporal lobe and diencephalic amnesia. *J Neurosci* 1990;10:3106-3117
7. Lindboe CF, Erichsen AA, Strom EH. Atrophy and sponginess of the mamillary bodies with neural sparing: not only inactive Wernicke's encephalitis. *APMIS* 1989;97:667-670
8. Baldwin GN, Tsuruda JS, Maravilla KR, Hamill GS, Hayes CE. The fornix in patients with seizures caused by unilateral hippocampal sclerosis: detection of unilateral volume loss on MR images. *AJR Am J Roentgenol* 1994;162:1185-1189
9. Mamourian AC, Brown DB. Asymmetric mamillary body: MR identification. *AJNR Am J Neuroradiol* 1993;14:1332-1335
10. Tien RD, Felsberg GJ, Crain B. Normal anatomy of the hippocampus and adjacent temporal lobe: high-resolution fast spin-echo MR images in volunteers correlated with cadaveric histologic sections. *AJR Am J Roentgenol* 1992;159:1309-1313
11. Duchen LW. General pathology of neurons and neuroglia. In: Adams JH, ed. *Greenfield's Neuropathology*. New York: John Wiley & Sons, 1984:15-20
12. Waller AV. Experiments on the section of the glossopharyngeal and hypoglossal nerves of the frog, and observations of the alterations produced thereby in the structure of their primitive fibres. *Philos Trans R Soc Lond Biol* 1850;140:423-429
13. Kuhn MJ, Johnson KA, Davis KR. Wallerian degeneration: evaluation with MR imaging. *Radiology* 1988;168:199-202
14. Kuhn MJ, Mikulis DJ, Ayoub DM, Kosofsky BE, Davis KR, Taveras JM. Wallerian degeneration after cerebral infarction: evaluation with sequential MR imaging. *Radiology* 1989;172:179-182
15. Matthews MR. Further observations on transneuronal degeneration in the lateral geniculate nucleus of the macaque monkey. *J Anat* 1964;98:255-263
16. Nieuwenhuys R, Voogd J, van Huijzen C. *The Human Cerebral Nervous System: A Synopsis and Atlas*. 3rd ed. New York, Berlin: Springer-Verlag, 1988:334-344
17. Carpenter MB, Sutin J. *Human Neuroanatomy*. 8th ed. Baltimore: Williams & Wilkins, 1983:630-632
18. Swanson LW, Cowan WM. An autoradiographic study of the organization of the efferent connections of the hippocampal formation in the rat. *J Comp Neur* 1977;172:49-84
19. Meibach RC, Siegel A. Efferent connections of the hippocampal formation in the rat. *Brain Res* 1977;124:197-224
20. Babb TL, Brown WJ. Pathologic findings in epilepsy. In: Engel J Jr, ed. *Surgical Treatment of the Epilepsia*. New York: Raven Press, 1987:511-540
21. Pitella JEH, Maciel STN. Partial fusion of the mamillary bodies: case study and review of congenital anomalies of these structures. *Arch Pathol Lab Med* 1985;109:567-568
22. Probst FP. *The Prosencephalies: Morphology, Neuroradiological Appearances and Differential Diagnosis*. New York: Springer Publishing Co Inc, 1979:54, 57, 61
23. Friede RL. Uncommon syndromes of cerebellar vermis aplasia: tecto-cerebellar dysraphia with occipital encephlocele. *Dev Med Child Neurol* 1978;20:764-772
24. Mirski MA. Unraveling the neuroanatomy of epilepsy. *AJNR Am J Neuroradiol* 1993;14:1336-1342

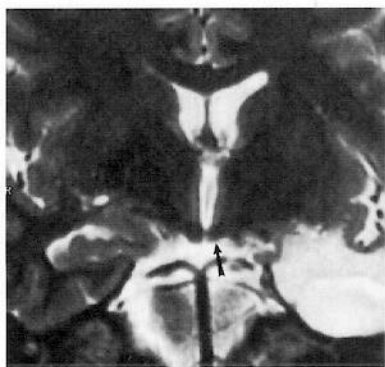



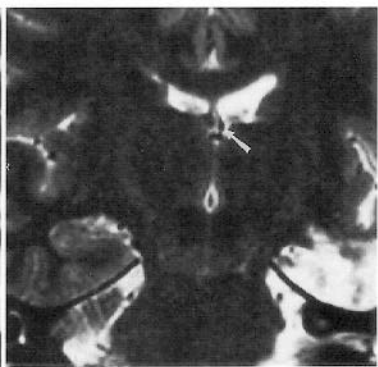


**B**

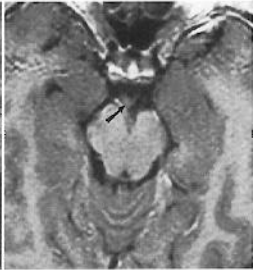
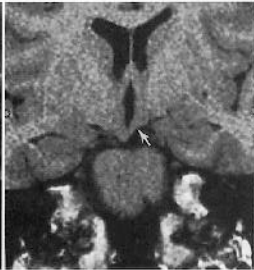
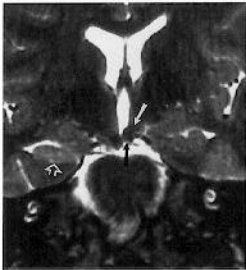

A



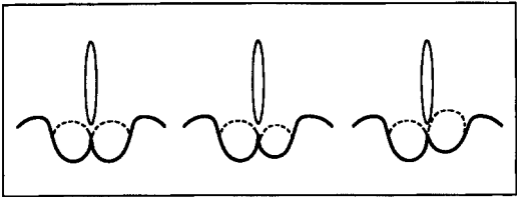
B



A

B

C



A