Are your MRI contrast agents cost-effective?
Learn more about generic Gadolinium-Based Contrast Agents.
FRESENIUS KABI
caring for life

AJNR

Gangliocytoma of the cervicothoracic spinal cord.

C P Russo, D S Katz, R J Corona, Jr and J A Winfield

AJNR Am J Neuroradiol 1995, 16 (4) 889-891
http://www.ajnr.org/content/16/4/889

This information is current as of May 3, 2024.

Gangliocytoma of the Cervicothoracic Spinal Cord

Craig P. Russo, Douglas S. Katz, Robert J. Corona, Jr, and Jeffrey A. Winfield

Summary: We present a case of an extensive cervicothoracic gangliocytoma in an asymptomatic 9-year-old boy with progressive scoliosis. MR findings were that of a moderately enhancing cervicothoracic intramedullary mass, which throughout most of its length could not be distinguished from the normal spinal cord.

Index terms: Spinal cord, neoplasms; Children, neoplasms; Ganglioneuroma

Mature ganglion cell tumors of the central nervous system are unusual, and those involving the spinal cord are especially rare (1–6). We present a case of an extensive cervicothoracic intramedullary gangliocytoma in a 9-year-old boy who presented with progressive nonpainful scoliosis.

Case Report

The patient is a previously healthy, asymptomatic, active 9-year-old boy who was discovered to have an approximately 19° convex right scoliosis during routine school screening. The scoliosis worsened, and the patient was referred for further evaluation. Neurologic examination revealed only decreased pinprick sensation at the level T7–8 and below bilaterally and slightly increased tone in both lower extremities. The remainder of the neurologic findings were normal.

Magnetic resonance (MR) was performed using a 1.5-T system. Sagittal T1-weighted images, 500/15/3 (repetition time/echo time/excitations), through the thoracic and cervical spinal cord (450/15/2) demonstrated a heterogenous intramedullary mass expanding the cord from the C-7 to T-6 levels (Fig 1). On axial T1-weighted images (600/15/2) through the upper thoracic spine (Fig 1B), cord expansion was identified. Sagittal T2-weighted images (2500/80/1) showed heterogeneous increased signal intensity throughout the mass (Fig 1C). Gadolinium-enhanced T1-weighted images showed moderate heterogeneous enhancement of the mass (Fig 1D).

At surgery the tumor was easily identified, expanding the spinal cord from the C-7 to T-7 levels. Grossly, the tumor appeared slightly lobulated and had a gray-yellow color. There was a well-defined margin between the tumor and the dorsal columns of the cord. All tumor that could be grossly identified was resected using microsurgical technique. The patient tolerated the procedure well, and after surgery his neurologic findings reverted to normal.

Pathologic specimen obtained at surgery showed a tumor predominantly composed of neoplastic neurons irregularly arranged in a benign fibrillary glial background. An occasional binucleate neuron was noted. No immature neuronal or glial elements were seen. A diagnosis of gangliocytoma was made (Fig 1E).

Discussion

Tumors containing mature ganglion cells may be most broadly classified as occurring primarily in the central nervous system or in relation to peripheral neural elements. Peripheral ganglion cell tumors (ganglioneuromas) are characterized by the presence of mature ganglion cells supported by a connective tissue network containing Schwann cells. Gangliocytomas and gangliogliomas, on the other hand, are mature ganglion cell tumors that primarily arise within the central nervous system. These uncommon tumors occur most frequently in children and young adults, most often in the temporal lobe and floor of the third ventricle. In fewer than 10% of cases, the tumor may be found in the spinal cord (1, 4–6). Gangliogliomas contain mature, neoplastic ganglion cells supported by a normocellular to hypercellular neoplastic glial background. Gangliocytomas contain mature neoplastic neuronal elements within a normocellular network of nonneoplastic glial cells. The terms *gangliocytoma* and *gan-*

Received August 18, 1993; accepted after revision December 17.

From the Departments of Radiology (C.P.R., D.S.K.), Neuropathology (R.J.C.), and Neurosurgery (J.A.W.), State University of New York Health Science Center at Syracuse.

Address reprint requests to Douglas S. Katz, MD, Department of Radiology, SUNY Health Science Center at Syracuse, 750 E Adams St, Syracuse, NY 13210.

AJNR 16:889–891, Apr 1995 0195-6108/95/1604–0889 © American Society of Neuroradiology

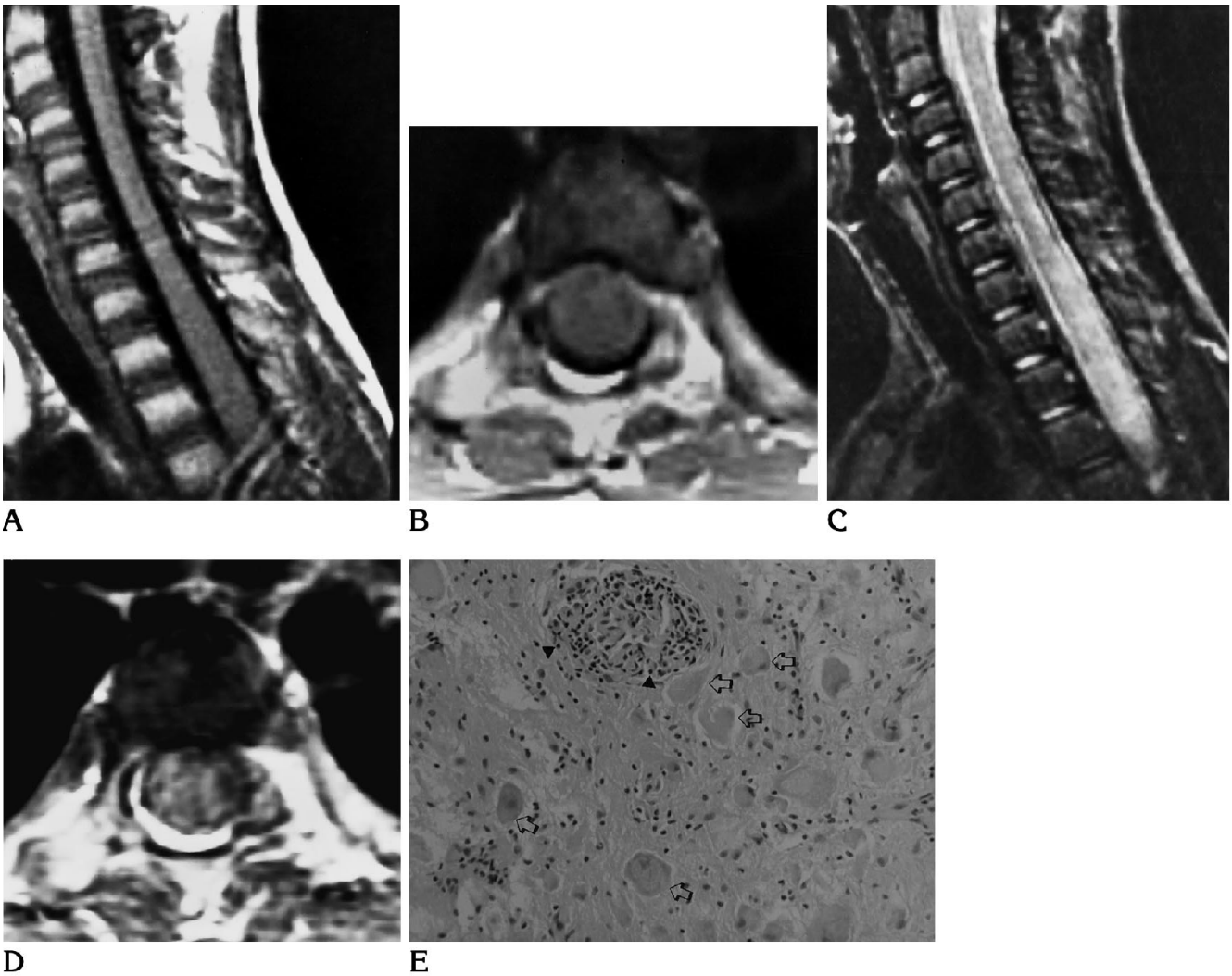

Fig 1. *A,* A sagittal T1-weighted image of the cervical spine demonstrates smoothly tapered widening of the middle to lower cervical cord, consistent with an intramedullary mass.

B, An axial T1-weighted image of the midthoracic cord demonstrates widening of the cord with areas of isointensity to hypointensity.

C, T2-weighted sagittal image of the cervical and upper thoracic cord demonstrates heterogeneously increased signal intensity within the expanded cord.

D, An axial T1-weighted image of the midthoracic cord shows moderate heterogenous enhancement of the intramedullary mass.

E, Neoplastic ganglion cells (*arrows*) are irregularly arranged in a normocellular glial background. The neoplastic nature of the ganglion cells is demonstrated by irregular distribution, bizarre sizes and shapes, abnormal orientation, and occasional binucleation. Perivascular collections of lymphocytes, frequently seen in ganglion cell neoplasms, also are observed (*arrowheads*).

glioneuroma often are used synonymously in the literature when referring to central tumors containing nonneoplastic glial cells and mature neoplastic ganglion cells. Strictly speaking, however, *ganglioneuroma* should be reserved for those tumors with a matrix derived from Schwann cells (7).

Gangliocytomas and gangliogliomas appear as nonspecific intramedullary masses, often involving multiple spinal cord segments. The MR findings in the present case were that of a long segment intramedullary mass of heterogeneous signal intensity with heterogenous enhancement and without an associated syrinx. Others have reported extensive cyst formation along with tumor enhancement (3). There presently is no way to distinguish a gangliocytoma from a ganglioglioma on the basis of imaging characteristics. This distinction may not be necessary, because both types of tumors show little propensity for growth and both are treated with surgery (8).

Acknowledgment

We thank Lawrence B. Poe, MD, for bringing this case to our attention.

References

1. Albright L, Byrd RP. Ganglioma of the entire spinal cord. *Childs Brain* 1980;6:274–280
2. Bevilacqua G, Sarnelli R. Ganglioma of the spinal cord: a case with a long survival. *Acta Neuropathol* 1979;48:239–242
3. Furei DM, Felsberg GJ, Tien RD, Friedman HS, Fuchs H, McLendon R. MRI of gangliocytoma of cerebellum and spinal cord. *J Comput Assist Tomog* 1993;17:488–491
4. Garrido E, Becker LF, Hoffman HJ, Hendrick EB, Humphreys R. Gangliomas in children. *Childs Brain* 1978;4:339–346
5. Kalyanaraman UP, Henderson JP. Intramedullary ganglioneuroma of spinal cord: a clinicopathologic study. *Human Pathol* 1982;13: 952–955
6. Ng THK, Fung CF, Goh W, Wong CVN. Ganglioneuroma of the spinal cord. *Surg Neurol* 1991;35:147–151
7. Russell DS, Rubinstein LJ. *Pathology of Tumors of the Central Nervous System*. 5th ed. Baltimore: Williams & Wilkins, 1989:289–301, 924–933
8. Johannson JH, Rekate HL, Roessman U. Gangliogliomas: pathological and clinical correlation. *J Neurosurg* 1981;54:58–63