AJNR

# Agenesis of the internal carotid artery with intercavernous anastomosis.

R B Midkiff, M W Boykin, D R McFarland and J A Bauman

*AJNR Am J Neuroradiol* 1995, 16 (6) 1356-1359
http://www.ajnr.org/content/16/6/1356

This information is current as of October 11, 2024.

# Agenesis of the Internal Carotid Artery with Intercavernous Anastomosis

Russell B. Midkiff, Mayola W. Boykin, David R. McFarland, and John A. Bauman

**Summary: We report a case of unilateral agenesis of the internal carotid artery with intercavernous anastomosis, a rare development anomaly. MR and carotid ultrasound, in association with clinical awareness, can be used to diagnose this condition.**

**Index terms: Arteries, abnormalities and anomalies; Arteries, carotid, internal; Cavernous sinus**

Unilateral agenesis of the internal carotid artery is a rare developmental anomaly. Fewer than 80 cases have been reported in the English literature since the description by Tode (1) in 1787 at postmortem examination. Verbiest (2) in 1954 reported the anomaly angiographically. Because most of the reported cases have been made in asymptomatic adults, sufficient collateral circulation must have existed. Arterial insufficiency is usually prevented by the contralateral internal carotid artery and the vertebrobasilar system via the circle of Willis. Less commonly, the affected hemisphere is supplied by an intercavernous anastomotic vessel connecting the internal carotid arteries. This unusual anastomosis has been reported 15 times (3–15) since the description by Lie in 1966 (4). We review the previous cases and report a case of this vascular anomaly with magnetic resonance (MR) and carotid duplex sonographic correlation in a patient with multiple sclerosis.

## Case Report

A 21-year-old man presented with a 1-week history of right upper-extremity weakness. The right carotid pulse was significantly less than the left. No bruits were present. Admission MR showed a lesion in the posterior limb of the left internal capsule and a second in the right periventricular white matter. A duplex carotid sonogram was performed to rule out plaque as an embolic source, and the right internal carotid artery was not visualized (Fig 1A and B). Right common carotid and arch angiography revealed agenesis of the right internal carotid artery. Left carotid injection showed a large collateral vessel connecting the cavernous portions of the internal carotids (Fig 2). Further review of the MR (Figs 3 and 4) confirmed the angiographic findings.

## Discussion

A developmental failure postulated to result in the absence of the internal carotid artery is thought to occur before the 24-mm stage of growth when the circle of Willis becomes embryologically complete (4, 16). Absence may be referred to as agenesis or aplasia. Agenesis is a primary failure of development with absence of the bony carotid canal. In aplasia, the carotid canal is present and a remnant of the vessel persists. We prefer the term *agenesis* in this case with absence of the bony carotid canal and cervical and petrous portions of the internal carotid artery.

In cases of unilateral absence of the internal carotid artery, Lie (4) described three types of collateral circulation. In the "fetal" type (which is thought to occur early in embryonic life), the anterior cerebral artery of the affected side is supplied by the normal contralateral internal carotid artery via the anterior communicating artery. The middle cerebral artery arises from the basilar artery through an enlarged posterior communicating artery. This is the most common type of collateral circulation. The second kind is termed the "adult" type, because it resembles what usually occurs in cases of thrombosis of the internal carotid artery. In this situation, both the anterior and middle cerebral arteries are fed by a patent anterior communicating artery.

The third type, which is the least common, is

Received May 10, 1993; accepted after revision April 13, 1994.

From the Department of Radiology, Brooke Army Medical Center, Fort Sam Houston, San Antonio, Tex.

Address reprint requests to Russell B. Midkiff, MD, Department of Radiology, Walter Reed Army Medical Center, Washington, DC 20307-5001.

AJNR 16:1356–1359, Jun 1995 0195-6108/95/1606–1356 © American Society of Neuroradiology

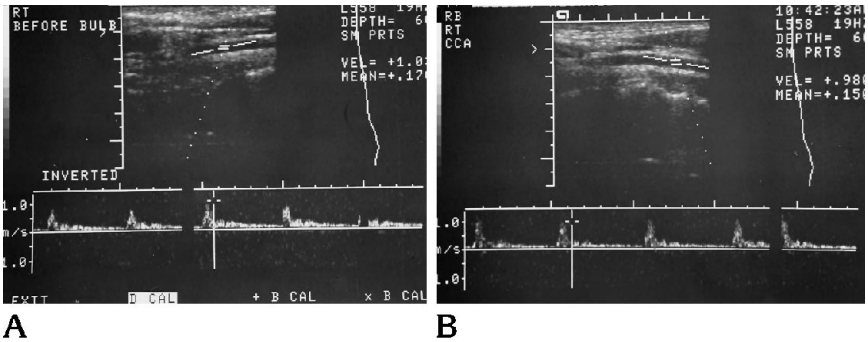


Fig 1. *A*, The right common carotid artery demonstrates high-resistance characteristics with sharp systolic peaks and little diastolic flow.

*B*, The right external carotid waveform demonstrates high-resistance characteristics and is indistinguishable from the common carotid artery waveform.

similar to our case. In this type, the cervical and petrous portions of the internal carotid artery are absent, and an intercavernous vessel arising from the contralateral internal carotid artery reconstitutes most of the cavernous and the supraclinoid portion of the vessel. Various authors have speculated about the origin of the anastomotic vessel. Lie (4) thought his case was best explained by fusion of two primitive trigeminal arteries, which failed to develop their normal connection to the basilar artery. Padget (16), in a 4- to 5-mm embryo, described plexiform channels around Rathke's pouch, which connected the internal carotid arteries. This has not been confirmed by others. Subsequent explanations have focused on hypertrophy of a normally developing blood supply as a more likely scenario. Proposed causes include anastomoses of primitive maxillary arteries (14, 17), inferior hypophyseal or capsular arteries (9), and preexisting medial rami from the cavernous carotid arteries (6). The exact blood vessels that enlarge will determine where the anomalous vessel crosses the base of the skull (3).

Agenesis of the internal carotid artery associated with an intercavernous anastomosis is a rare anomaly, which has been reported only 15 times (3–15). The age range of patients is 7 to 69 years with a mean of 38.8 years. There was a 2:1 male predominance (10 male and 5 female) with one unknown. Unlike the previously reported left-sided predominance of 3:1 for all cases of unilateral agenesis of the internal carotid artery (18), there was an equal incidence

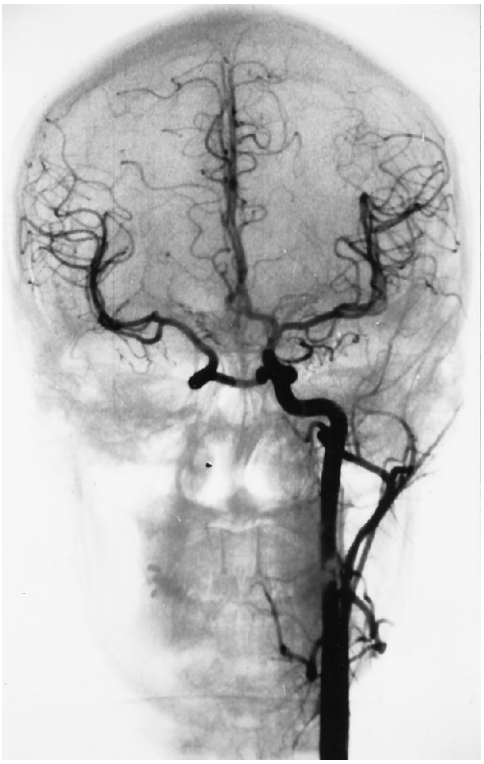

Fig 2. Left common carotid angiogram reveals an anomalous collateral vessel connecting the cavernous portions of the right and left internal carotid arteries. The right anterior cerebral artery fills via a patent anterior communicating artery.

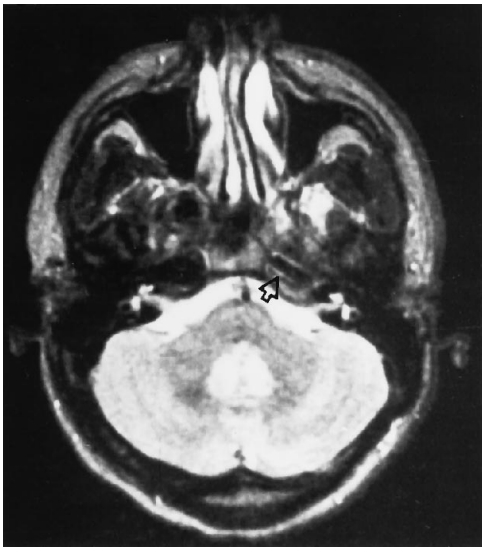

Fig 3. MR through the skull base demonstrates normal flow void in the left internal carotid artery (*arrow*) and no visibility of the right internal carotid artery.

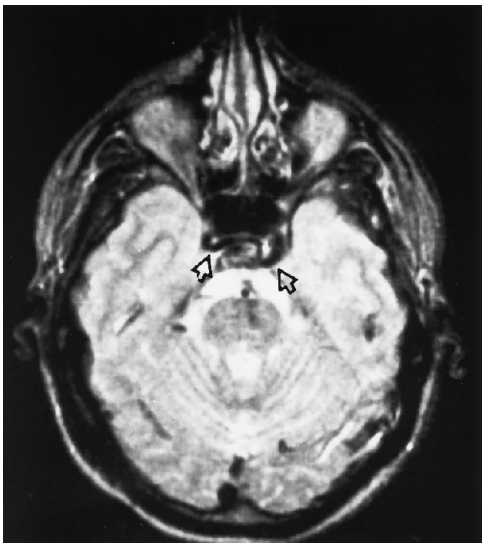

Fig 4. MR at the level of the floor of the sella demonstrates a flow void (*arrows*), which corresponds to the intercavernous anastomotic vessel seen on angiography.

of right- and left-sided occurrences (8 right and 8 left). Three (18.8%) of 16 patients had intracranial aneurysms; there were a total of five aneurysms in the 3 patients. This exceeds the 2% to 4% natural incidence of intracranial aneurysms (19) but is less than the 25% to 34% incidence that has been found in all cases of agenesis or hypoplasia of the internal carotid artery (20). Deranged hemodynamic forces or developmental errors are potential explanations (20). Finally, it can be noted that in 13 of 16 cases (including our case) the A1 segment of the anterior cerebral artery on the side of the agenetic internal carotid artery was not seen angiographically, consistent with agenesis or aplasia. Lie (4) described the A1 segment as being hypoplastic.

MR findings in agenesis of the internal carotid artery have been reported once (21). In our case, patency of an intercavernous anastomatic vessel was demonstrated (Fig 4). Previous reports suggest that dynamic computed tomography is not a reliable method of excluding this anomaly (15). Perhaps MR will be more sensitive in detection—a fact that has clinical relevance when MR is performed before transsphenoidal surgery for pituitary adenoma. Agenesis of the internal carotid artery should be considered when the normal internal carotid flow void is absent (Fig 3).

Carotid duplex sonography may also aid in diagnosis. When the internal carotid artery is occluded (or, as in our case, absent), branches of the external carotid artery may simulate the bifurcation; hence, correct identification is essential (22). Although size and orientation may be helpful, the best means of identifying these two vessels is noting their pulsatility differences. Normally, both the common and internal carotid arteries exhibit low peripheral resistance characteristics with a broad systolic and relatively high diastolic velocity. However, when significant obstruction (or, as in our case, absence) exists, the common carotid artery assumes high peripheral resistance characteristics such as those seen in the external carotid artery. In our case, the flow characteristics of the common and external carotid circulations were indistinguishable (Fig 1A and B). It is suggested that agenesis of the internal carotid artery be considered in the differential diagnosis of a patient with a duplex picture consistent with occlusion; particularly if "externalization" of the common carotid artery Doppler spectrum is noted.

## References


1. Tode. *Med Chir Biblio (Kopenh)* 1787;10:408
2. Verbiest H. Radiologic findings in a case with absence of the left internal carotid artery and compression of several cranial nerve roots in the posterior fossa by the basilar artery. *Med Contemp* 1954;71:601–609
3. Quint DJ, Boulos RS, Spera TD. Congenital absence of the cervical and petrous internal carotid artery with intercavernous anastomosis. *AJNR Am J Neuroradiol* 1989;10:435–439
4. Lie TA. *Congenital Anomalies of the Carotid Arteries.* Amsterdam: Excerpta Medica, 1968:35–51
5. Harispe L, Creissard P, Martinez G, Metzger J. Une artere communicante anormale unissant les deux arteres carotides internes intracraniennes. *J Radiol* 1978;51:759–762
6. Smith RR, Kees CJ, Hogg ID. Agenesis of the internal carotid artery with an unusual primitive collateral: case report. *J Neurosurg* 1972;37:460–462
7. Faivre J, Vallee B, Carsin M, Scarabin JM, Simon J. Agenesie des portions cervicale et petreuse de la carotide interne gauche. *J Neuroradiol* 1978;5:133–138
8. Janicki PC, Limbacher JP, Guinto FC Jr. Agenesis of the internal carotid artery with a primitive transsellar communicating artery. *AJR Am J Roentgenol* 1979;132:130–132
9. Staples GS. Transsellar intracavernous intercarotid collateral artery associated with agenesis of the internal carotid artery: case report. *J Neurosurg* 1979;50:393–394
10. Kishore PRS, Kaufman AB, Melichar FA. Intrasellar carotid anastomosis simulating pituitary microadenoma. *Radiology* 1979; 132:381–383
11. Schmidt RC. Partielle aplasie der rechten arteria crotis interna mit einer ungwohnlichen kollateralarterie unterhalb der hypophyse. *Fortschr Rontgenstr* 1979;130:572–575
12. Huber G. Intracranial carotid anastomosis and partial aplasia of an internal carotid artery. *Neuroradiology* 1980;20:207–212

13. Khangure MS, Apsimon HT. Some pitfalls in the diagnosis of pituitary tumors: the importance of carotid angiography. *Surg Neurol* 1981;16:300–308
14. Elefante R, Fucci F, Granata F, Graziussi G, Smaltino F. Agenesis of the right internal carotid artery with an unusual transsellar intracavernous intercarotid connection. *AJNR Am J Neuroradiol* 1983;4:88–89
15. Alexander MWT, Chui MC, Gray T. Transsellar intercavernous carotid anastomosis with agenesis of internal carotid artery and right sided descending aorta: case report. *J Can Assoc Radiol* 1984;35:92–95
16. Padget DH. The development of the cranial arteries in the human embryo. *Contrib Embryol Carnegie Inst* 1948;32:205–261
17. Lasjaunias P, Moret J, Vignaud J. Collaterales C5 du siphon carotidien: embryologie, correlations radioanatomique, radio-anatomie pathologique. *Neuroradiology* 1978;16:304–305
18. Worthington C, Olivier A, Melanson D. Internal carotid artery agenesis: correlation by conventional and digital subtraction angiography, and by computed tomography. *Surg Neurol* 1984;22: 295–300
19. Servo A. Agenesis of the left internal carotid artery associated with an aneurysm of the right carotid siphon: case report. *J Neurosurg* 1977;46:677–680
20. Affi AK, Godersky JC, Menezes A, Smoker WR, Bell WE, Jacoby CG. Cerebral hemiatrophy, hypoplasia of internal carotid artery and intracranial aneurysm: a rare association occurring in an infant. *Arch Neurol* 1987;44:232–235
21. Breidahl WH, Khangure MS. MRI diagnosis of congenital absence of the internal carotid artery. *Clin Radiol* 1990;42:354–355
22. Zwiebel WJ. Ultrasound cerebrovascular diagnosis. *Semin Ultrasound CT MR* 1987;8:1–50