

Are your MRI contrast agents cost-effective?

Learn more about generic Gadolinium-Based Contrast Agents.



**FRESENIUS
KABI**

caring for life

AJNR

**Meningeal symptoms induced by an otologic
implant during MR.**

B H Adler, R Nusynowitz and C Ballart

AJNR Am J Neuroradiol 1995, 16 (6) 1365-1366

<http://www.ajnr.org/content/16/6/1365>

This information is current as
of April 29, 2024.

Meniere Symptoms Induced by an Otologic Implant during MR

Brent H. Adler, Russell Nusynowitz, and Carol Ballart

Summary: A patient who had had sacculotomy with placement of a stainless steel sacculotomy tack 20 years earlier experienced vertigo and auditory sensations during MR imaging. The safety of these prostheses in MR is questionable. A simple method of determining ferromagnetic interaction is proposed.

Index terms: Ear, prostheses; Iatrogenic disease or disorder; Magnetic resonance; Meniere disease

The effects of high-strength magnetic fields on in vivo foreign bodies has been widely discussed in the literature. Case reports of morbidity and mortality abound; however, the magnetic resonance (MR) evaluation of patients with otologic implants is considered safe (1, 2). Throughout the 1960s and 1970s, thousands of patients with Meniere disease underwent sacculotomy with placement of a sacculotomy tack. These stainless steel tacks act as a valve to relieve hydrops as pressure accumulates (3). In theory, the 2-mm nonferromagnetic prosthesis should be unaffected by the magnet. Our experience raises some doubts about their safety and the means of measuring in vitro magnetic effects. We also are proposing a simple but sensitive method of determining ferromagnetic interaction.

Case Report

A 60-year-old patient with intermittent dizziness and vertigo was referred to our imaging center for MR to evaluate her internal acoustic canals. All patients we image are questioned about surgical and work history as well as any prostheses that may be pertinent for their safety near the magnet. Imaging is done on a 1.5-T Siemens magnet. As the patient entered the magnet, she told the technologist she was feeling dizzy and was having an attack of Meniere disease but could continue. She admitted to the technologist she had a "plastic tack" placed approximately 20 years ago for Meniere disease. She was placed into the bore and a locating image and T2-weighted axial images were obtained. At this point, the patient could no longer

tolerate her increasing vertigo and a loud "popping sound." The patient began to hear the sound as she entered the bore and before a sequence began. She was removed from the magnet suite and felt immediate diminution of her symptoms. Her vital signs were unremarkable, her skin warm and dry. She described her symptoms as exactly corresponding to Meniere disease. Approximately 8 hours after the exam she began to feel better, with complete resolution by the following morning. Further investigation revealed that she had a "Cody stainless steel tack." The sacculotomy tack was placed for decompression of the saccule from endolymphatic hydrops (Cody Sacculotomy Tack Information Sheet, Smith and Nephew Richards, Bartlette, Tenn) [3]. This accounts for the artifact on her scan (Fig 1).

We were able to obtain several sacculotomy tacks from the manufacturer and attempted to reproduce the experiment performed by Shellock et al (1). In his work, the ferromagnetism of the device was determined by movement of the object on a petri dish placed in the magnetic bore. We modified the experiment and floated the tacks on distilled water. The tacks are small enough to be suspended by the surface tension of water. By doing this we have overcome the static friction of the metal on plastic. (This technique is borrowed from ancient compass design.) We readily observed motion of the tack, which maintained orientation with the magnetic field.

Discussion

Injury has been widely reported from dislodged and broken surgical prostheses in patients undergoing MR imaging. However, otologic implants (excluding cochlear implants) frequently are reported as safe in in vitro experiments in field strengths up to 1.5-T (1, 2, 4). These tests concentrated on evaluating ferromagnetic properties and motion of ex vivo implants. These reports have included stainless steel and other nonferromagnetic devices, including this specific device, the Richards Cody sacculotomy tack, stainless steel American Society for Testing Material (ASTM) F138, manu-

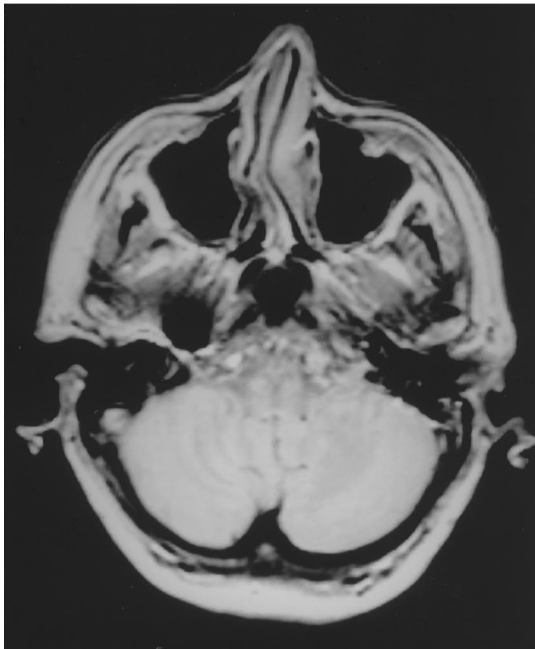
Received October 5, 1993; accepted after revision May 6, 1994.

From the Department of Radiology, Sinai Hospital of Detroit (Mich).

Address reprint requests to Russell N. Nusynowitz, MD, Department of Diagnostic Radiology, Sinai Hospital, 6767 W Outer Dr, Detroit, MI 48235.

Fig 1. Metallic susceptibility artifact in right temporal bone from stainless steel sacculotomy tack, T1-weighted locating MR sequence.

Fig 2. The Richards Cody sacculotomy tack, stainless steel ASTM F138, manufactured between 1972 and 1975.



1



2

factured between 1972 and 1975 (Fig 2). It frequently has been postulated that significant amounts of impurity will exist in nonferromagnetic prostheses simply from the cold working of the device after forging. These impurities would likely lead to a weak ferromagnetism in the smallest devices.

Our patient's vertigo and auditory sensations with proximity to the magnet lead us to believe that her prosthesis is adversely affected by the field, either by some physical irritation to the adjacent sensory organ (the stapes, saccule, utricle, or vestibular or cochlear nerve), or that an electric current was induced that might stimulate the vestibular or cochlear nerve. Our patient's symptoms and the preliminary work we

have done with the Cody tack suggest that in vitro evaluation of small prosthesis may be incomplete.

References

1. Shellock F, Schatz C. Metallic otologic implants: in vitro assessment of ferromagnetism at 1.5T. *AJNR Am J Neuroradiol* 1991; 12:279-281
2. Mattucci K, Setzen M, Hyman R. The effect of nuclear magnetic resonance imaging on metallic middle ear prostheses. *Otolaryngol Head Neck Surg* 1986;94:441
3. Cody D, Simonton KM, Hallberg DE. Automatic repetitive decompression of the saccule in endolymphatic hydrops (tack operation): preliminary report. *Laryngoscope* 1967;77:1480-1501
4. Applegaum E, Valvassori G. Further studies on the effects of magnetic resonance imaging fields on middle ear implants. *Ann Otol Rhinol Laryngol* 1990;90:801-804