

Are your **MRI contrast agents** cost-effective?

Learn more about generic **Gadolinium-Based Contrast Agents**.



FRESENIUS
KABI

caring for life

AJNR

Spontaneous involution of optic pathway lesions in neurofibromatosis type 1: serial contrast MR evaluation.

C Parazzini, F Triulzi, E Bianchini, V Agnetti, M Conti, C Zanolini, M M Maninetti, L N Rossi and G Scotti

This information is current as of May 2, 2024.

AJNR Am J Neuroradiol 1995, 16 (8) 1711-1718
<http://www.ajnr.org/content/16/8/1711>

Spontaneous Involution of Optic Pathway Lesions in Neurofibromatosis Type 1: Serial Contrast MR Evaluation

C. Parazzini, F. Triulzi, E. Bianchini, V. Agnetti, M. Conti, C. Zanolini, M. M. Maninetti, L. N. Rossi, and G. Scotti

PURPOSE: To evaluate with contrast MR the evolution in size, signal, and contrast enhancement of optic pathway lesions in four patients with neurofibromatosis type 1. **METHODS:** The four reported patients are children with ages ranging from 21 months to 13 years affected by neurofibromatosis type 1 and optic pathway lesions. No treatment of the optic pathway lesions was carried out in these patients. They have been followed by serial contrast MR. **RESULTS:** In all patients a change in size, signal, and enhancement of optic pathways lesions was noted with time, and in the last follow-up study a marked reduction in size and enhancement of optic pathway lesions was observed in all cases. **CONCLUSIONS:** Modification and regression of optic pathway lesions with spontaneous disappearance of the enhancement is demonstrated. This finding could have a crucial influence on the therapeutic approach of the optic pathway lesions.

Index terms: Brain, magnetic resonance; Neurofibromatosis; Optic tract

AJNR Am J Neuroradiol 16:1711–1718, September 1995

Neurofibromatosis is a genetic disorder characterized by the association of nervous system lesions with cutaneous abnormalities. Eight types of neurofibromatosis have been described; the most common is neurofibromatosis type 1 occurring in 1 in 3000 births. This disorder is transmitted as an autosomal dominant trait, although spontaneous mutations are responsible for about half the cases (1). Among these patients, intracranial abnormalities account for some of the most frequent and disabling features (1). The incidence of the central nervous system tumors in patients with neurofibromatosis is much higher than in the general population (2). Central nervous system neoplasms occur in the form of optic pathway gliomas, astrocytomas, and ependymomas and

are a common cause of death in children affected by neurofibromatosis type 1 (1). Optic pathway gliomas are the most frequent tumor in neurofibromatosis type 1: their incidence has been reported to range from 15% to 70% (3–4). Central nervous system dysplasia are also common; they may be manifest by a wide spectrum of hamartomatous or heterotopic lesions within the brain (1).

In this study four patients affected by neurofibromatosis type 1 and optic pathway lesions were sequentially studied with contrast magnetic resonance (MR) to evaluate the evolution of size, signal, and contrast enhancement of the lesions.

Subjects and Methods

Eleven patients affected by neurofibromatosis type 1, including seven girls and four boys ranging in age from 21 months to 13 years (average, 7.3 years) were studied with serial MR. One or more follow-up studies were performed in all cases for a total of 32 cranial MR examinations; 23 studies were done with contrast medium. The follow-up studies were done 3 to 13 months after the first examination; only in one case was the first follow-up done 3 years after the baseline study. A review of these sequential cranial MR examinations revealed five patients with optic pathway lesions. In one patient, a 10-year-old girl, on the

Received October 14, 1994; accepted after revision March 27, 1995.

From the Department of Neuroradiology, Scientific Institute H. S. Raffaele (C.P., F.T., E.B., G.S.), and the Department of Pediatrics (C.Z., M.M.M., L.N.R.), University of Milan; and the Department of Neurology and Radiology, University of Sassari (V.A., M.C.), Italy.

Address reprint requests to C. Parazzini, MD, Department of Neuroradiology, Scientific Institute H. S. Raffaele, University of Milan, Via Olgettina 60, 20132 Milan, Italy.

AJNR 16:1711–1718, Sept 1995 0195-6108/95/1608-1711

© American Society of Neuroradiology

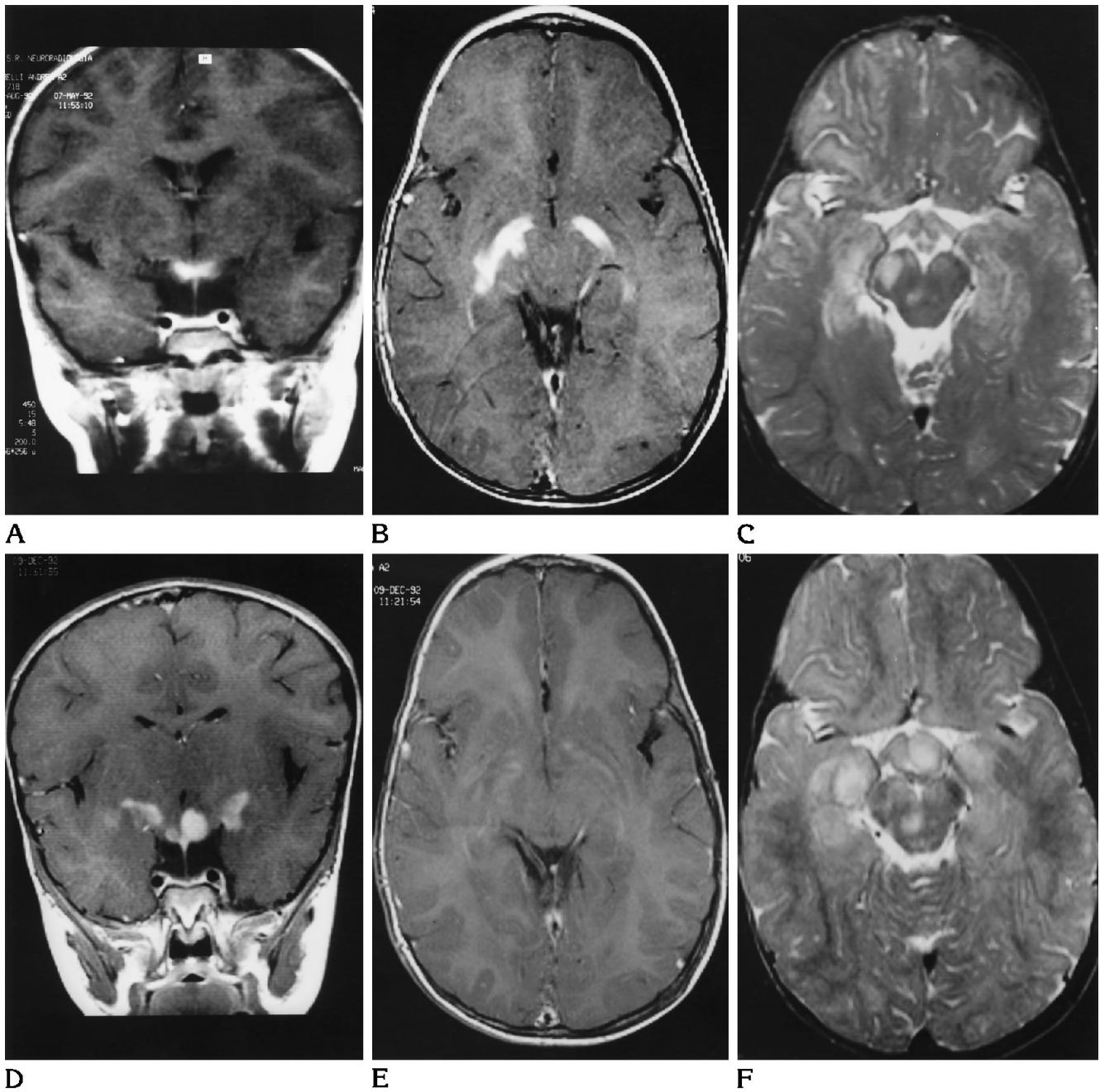


Fig 1. Case 1.

A–C, Baseline study at 21 months of age. A and B, Coronal and transverse postcontrast T1-weighted images (450/15 and 600/15). C, Transverse T2-weighted image (3000/120). An increase in size, signal, and enhancement of the optic chiasm and tracts are shown. A striking enhancement of the region of the lateral geniculate bodies and of the retrolenticular portion of the internal capsule is also detectable. Focal areas of hyperintensity are also present in the right midbrain (C).

D–F, First follow-up study at 28 months of age. D and E, Coronal and transverse T1-weighted images (500/15 and 600/15). F, Transverse T2-weighted image (3000/120). A further increase in the enhancement of the optic chiasm and tracts and a clear reduction in the enhancement of posterior optic pathways are evident. The signal alteration of the optic pathway lesions has not changed. Furthermore we observe an increase in size, signal, and enhancement of the hypothalamus (D and F). *Figure continues.*

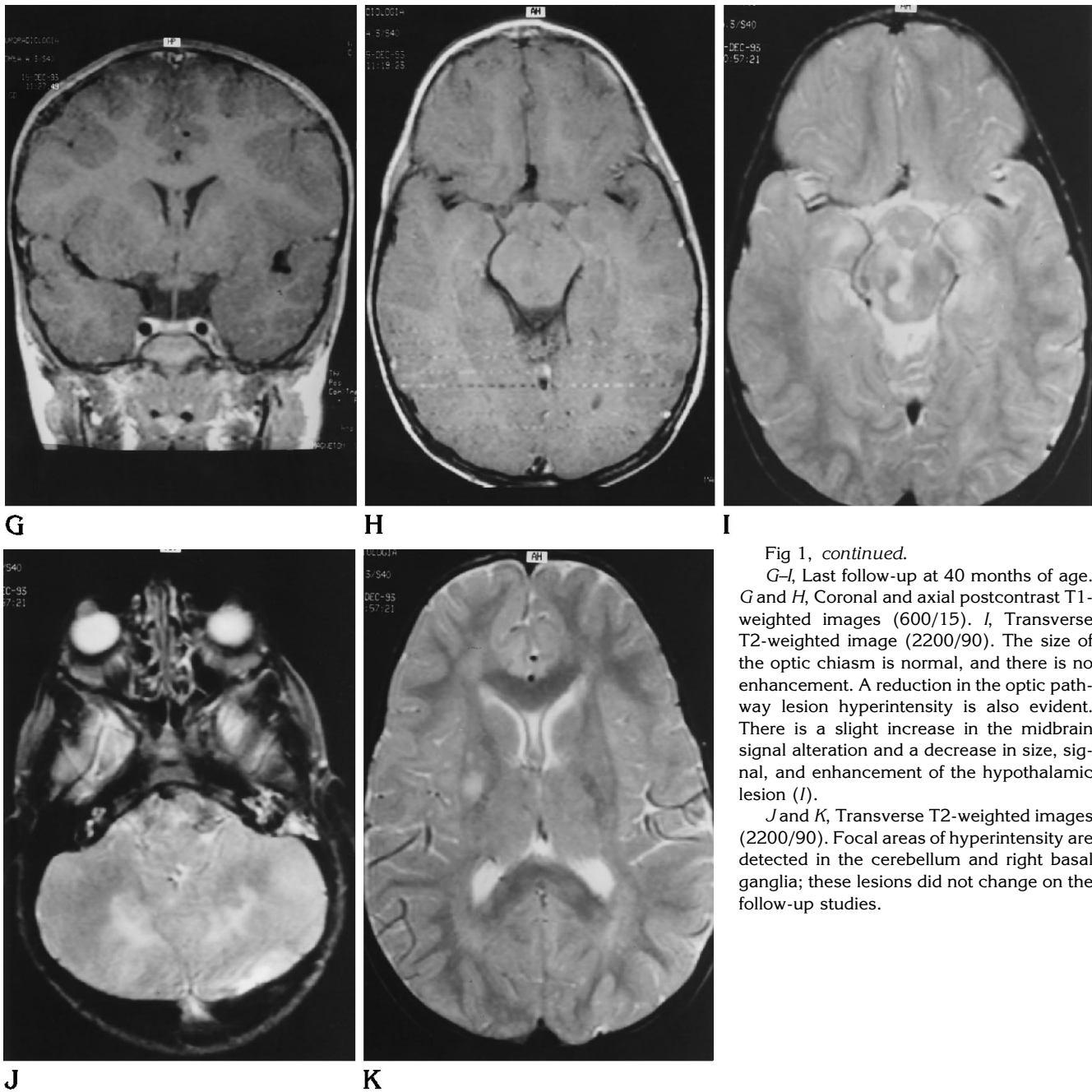


Fig 1, continued.

G-I, Last follow-up at 40 months of age. G and H, Coronal and axial postcontrast T1-weighted images (600/15). I, Transverse T2-weighted image (2200/90). The size of the optic chiasm is normal, and there is no enhancement. A reduction in the optic pathway lesion hyperintensity is also evident. There is a slight increase in the midbrain signal alteration and a decrease in size, signal, and enhancement of the hypothalamic lesion (I).

J and K, Transverse T2-weighted images (2200/90). Focal areas of hyperintensity are detected in the cerebellum and right basal ganglia; these lesions did not change on the follow-up studies.

first examination we observed an increase in the size of the right optic nerve with no signal alteration; this finding did not change during the follow-up studies over 3 years.

In four patients the optic pathway lesions found on the baseline studies showed an involution as time passed. These four patients were two boys and two girls, ranging in age from 21 months to 13 years. They were sequentially studied with contrast cranial MR. The diagnosis of neurofibromatosis type 1 was made on the basis of the criteria established by the National Institutes of Health Consensus

Development Conference in 1987. The patients underwent MR examinations as follows: case 1 (M.A., male) at 21, 28, 32, 35, and 40 months of age; case 2 (C.M., male) at 25 and 40 months of age; case 3 (F.M., female) at 22, 28, and 38 months of age; and case 4 (U.E., female) at 13 years and after 4 and 8 months. Cases 1, 2, and 3 were asymptomatic and had normal neurologic findings at the time of the baseline study. In case 1, intermittent esotropia of the left eye and a slight proptosis of the right eye had developed on the follow-up study. Case 4 presented with sei-

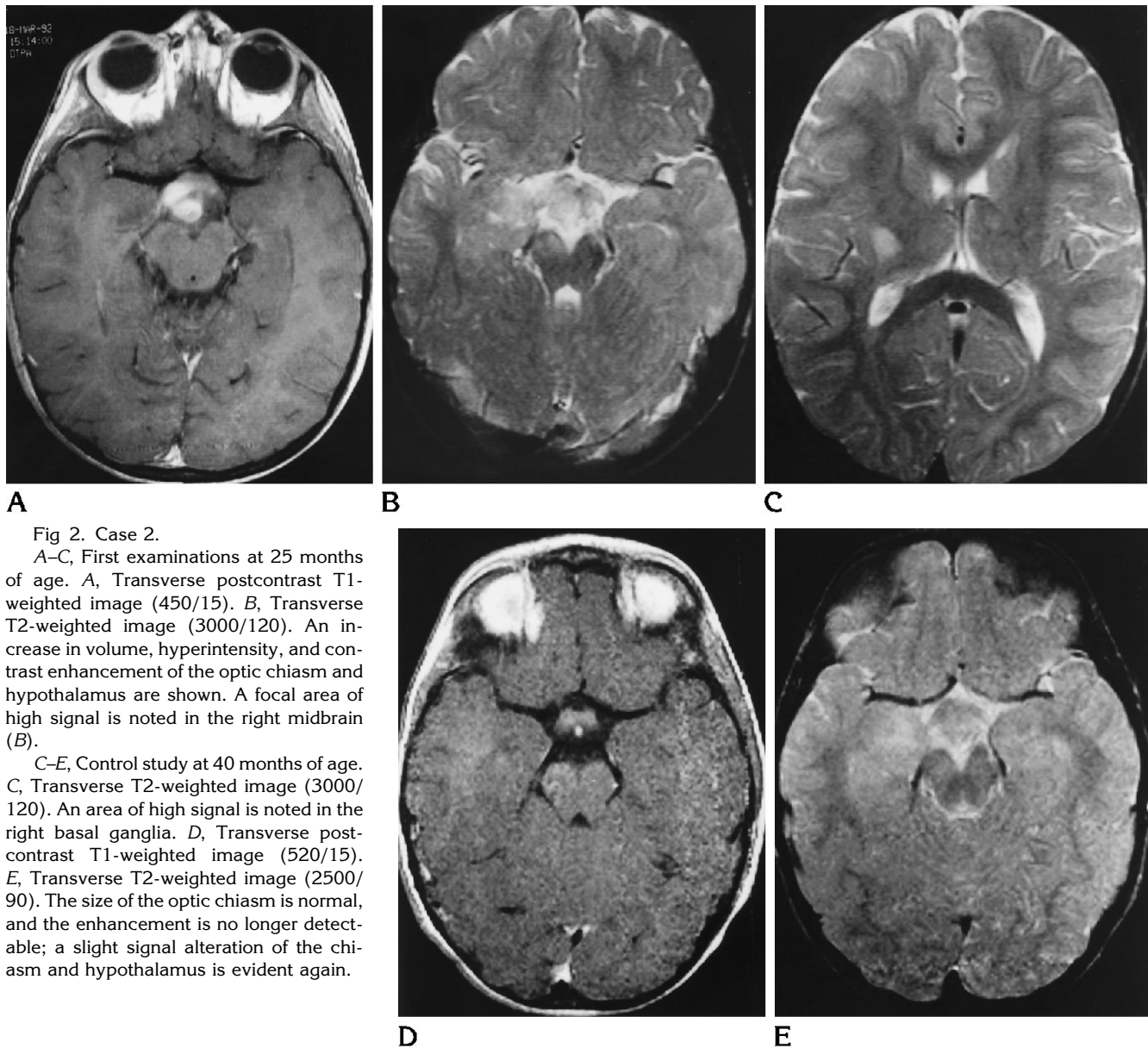


Fig 2. Case 2.

A–C, First examinations at 25 months of age. A, Transverse postcontrast T1-weighted image (450/15). B, Transverse T2-weighted image (3000/120). An increase in volume, hyperintensity, and contrast enhancement of the optic chiasm and hypothalamus are shown. A focal area of high signal is noted in the right midbrain (B).

C–E, Control study at 40 months of age. C, Transverse T2-weighted image (3000/120). An area of high signal is noted in the right basal ganglia. D, Transverse post-contrast T1-weighted image (520/15). E, Transverse T2-weighted image (2500/90). The size of the optic chiasm is normal, and the enhancement is no longer detectable; a slight signal alteration of the chiasm and hypothalamus is evident again.

zures. A cerebral astrocytoma was detected. The patient underwent surgical resection of the astrocytoma with no subsequent radiation therapy or chemotherapy. No treatment was carried out in cases 1, 2, and 3.

The MR examinations were performed on a 1.5-T system. Images were obtained in the transverse plane with a proton density- and T2-weighted double-echo spin-echo sequence (2200–3000/15–20, 90–120 [repetition time/echo time]) and in the transverse or coronal plane with a T1-weighted spin-echo sequence (450–600/15). All the patients were also studied after receiving contrast medium (gadopentetate dimeglumine) administration with T1-weighted spin-echo sequences in the transverse and coronal planes and occasionally in the sagittal plane. The section thickness was 5 and 4 mm with an acquisition matrix of 256 × 256.

Results

In all patients the baseline studies showed increase in size, hyperintense signal on T2-, proton density-weighted images, and enhancement of optic chiasm and optic tracts (Figs 1A, B, and C; 2A and B; 3A and B; and 4A and B). In case 1 the signal alteration and the enhancement also involved the right optic nerve, the lateral geniculate bodies, and the retrolenticular portion of the internal capsules; also in cases 2 and 3 there was an involvement of the optic nerves.

Case 1 showed a further increase in size, signal, and contrast enhancement of the optic chi-

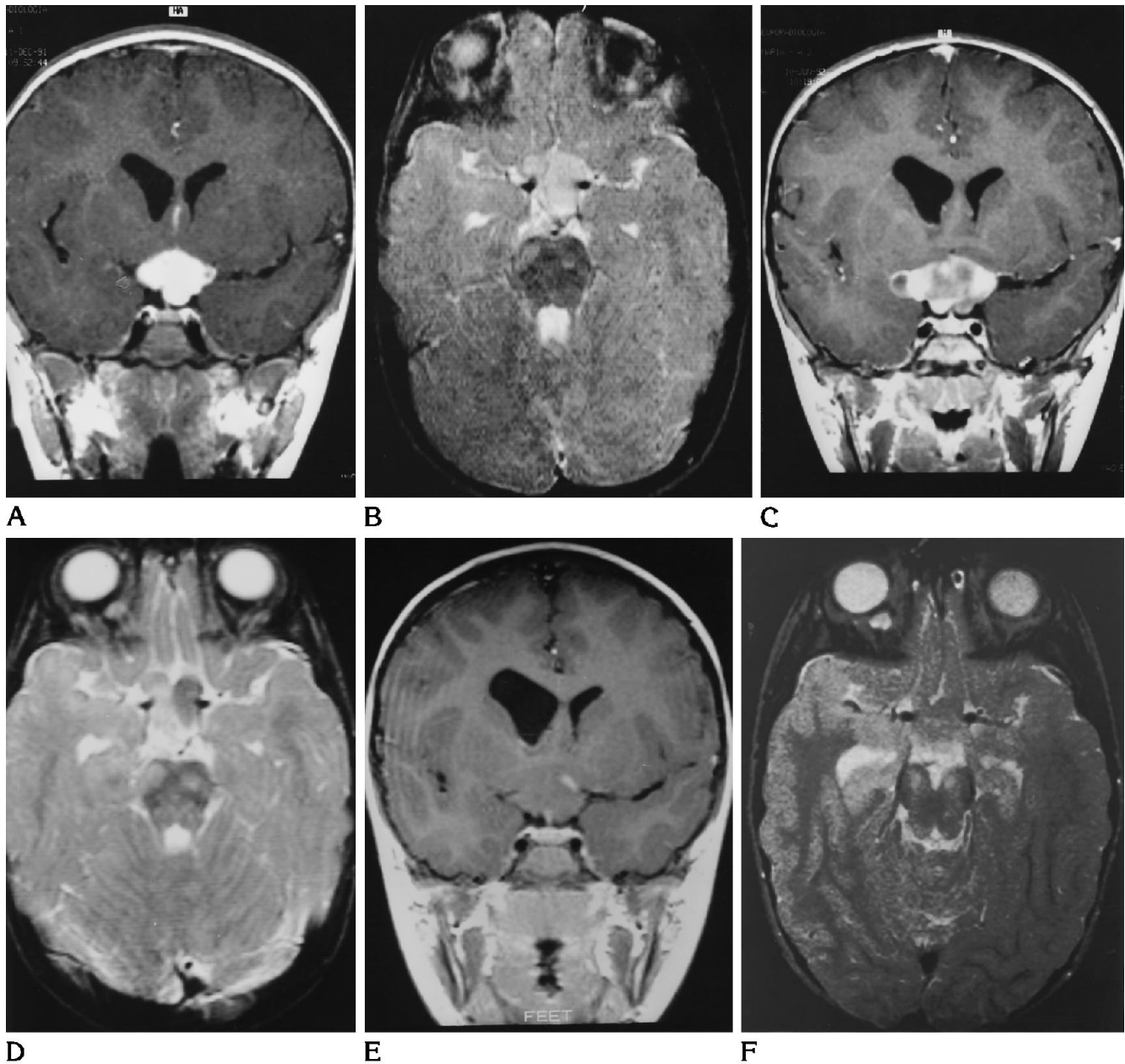


Fig 3. Case 3.

A and *B*, Baseline study at 22 months of age. *A*, Coronal postcontrast T1-weighted image (450/15). *B*, Transverse T2-weighted image (3000/120). An increase in size, a marked enhancement, and a hyperintensity of the optic chiasm are shown. Signal alteration of the midbrain is also detected (*B*).

C and *D*, First follow-up at 28 months of age. *C*, Coronal postcontrast T1-weighted image (450/15). *D*, Transverse T2-weighted image (3000/120). An increase in size of the optic chiasm is evident; there is a slight decrease in the hyperintensity of the left side of the optic chiasm and a change of the enhancement. There is also a progressive involvement of the fornix.

E and *F*, Last study at 38 months of age. *E*, Coronal postcontrast T1-weighted image (600/15). *F*, Transverse T2-weighted image (2500/90). The enhancement and the signal alteration of the optic chiasm have almost completely disappeared; there is a slight reduction in the lesion size too.

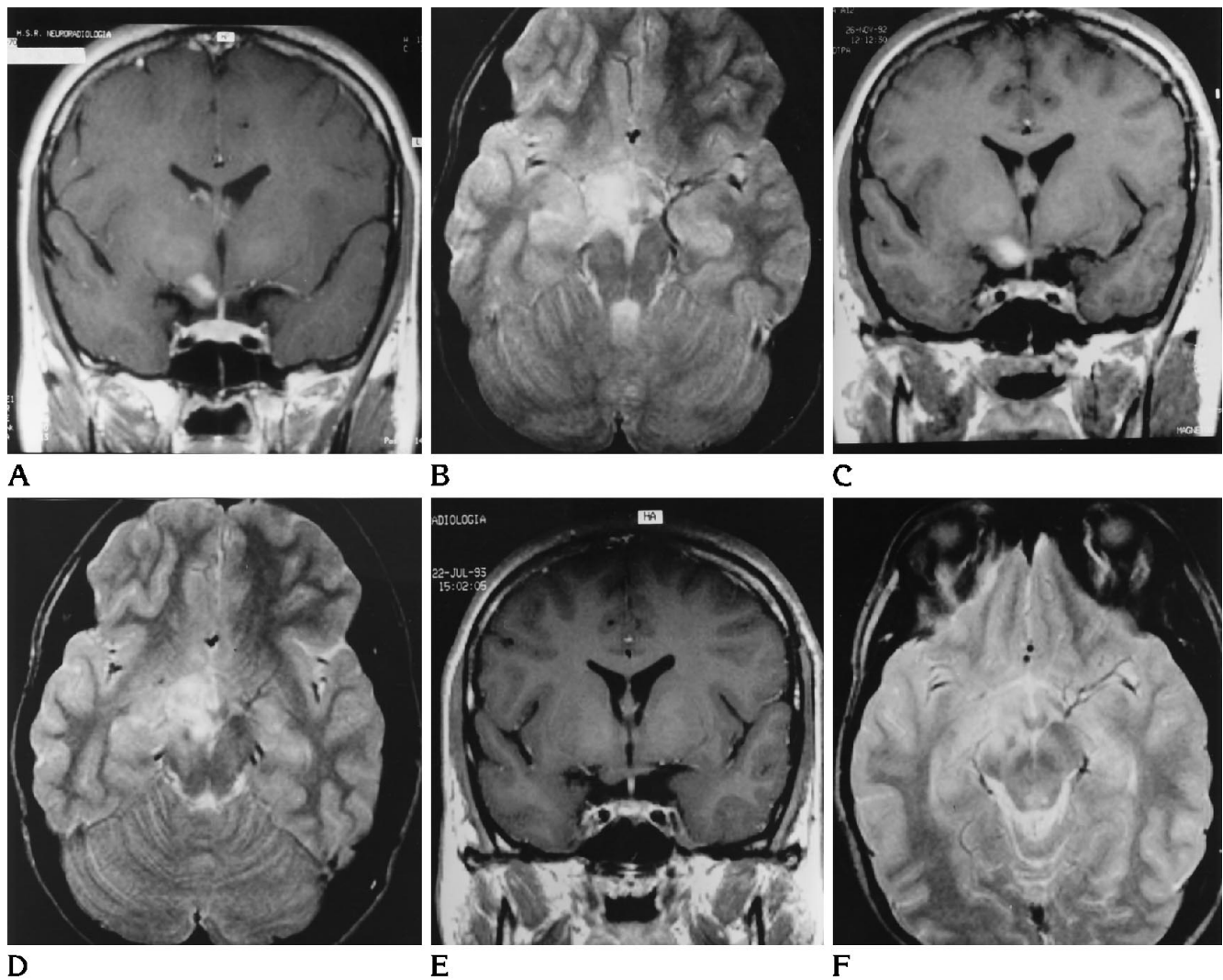


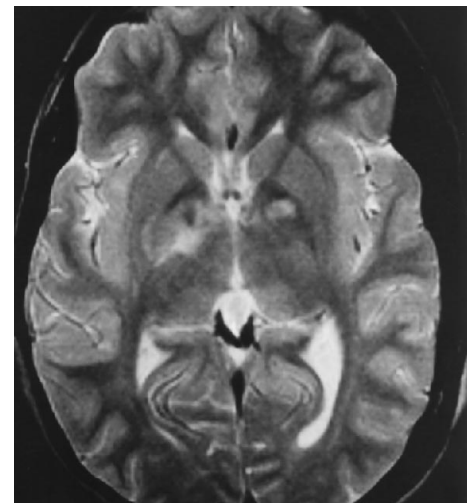
Fig 4. Case 4.

A and B, First study at 13 years of age. *A*, Coronal postcontrast T1-weighted image (450/15). *B*, Transverse T2-weighted image (2400/90). An increase in size, signal, and enhancement of the right optic chiasm and the optic tract are shown.

C and D, Second study after 4 months. *C*, Coronal postcontrast T1-weighted image (600/15). *D*, Transverse T2-weighted image (2400/90). A slight increase in signal and enhancement of the lesion is observed.

E and F, Last examination after 8 months. *E*, Coronal postcontrast T1-weighted image (600/15). *F*, Transverse T2-weighted image (2400/90). A reduction in size, a slight signal decrease, and the disappearance of the enhancement are shown.

G, Transverse T2-weighted image (2400/90). Focal areas of high signal are detected in the basal ganglia bilaterally; these lesions did not change during the follow-up studies.



G

asm and optic tracts in the first follow-up obtained after 7 months (Fig 1D and F); however, there was a clear reduction in the posterior optic pathways enhancement while a hyperintensity on T2-, proton density-weighted images was noted again (Fig 1E and F).

In case 3, the first follow-up obtained after 6 months showed a further increase in size of the optic chiasm and optic tracts with a decrease in signal on the left optic chiasm and a change in enhancement (Fig 3C and D).

In case 2 we had only one follow-up, obtained after 15 months; the MR examination showed a complete disappearance of the optic pathway lesion enhancement and only slight signal alteration on T2-, proton density-weighted images (Fig 2D and E). Case 4 showed a very slight increase in signal and enhancement of the lesion in the first control study, obtained after 4 months (Fig 4C and D).

Progressively, in the further follow-up studies, in all the cases there was a dramatic reduction in the optic pathway lesion enhancement until it was no longer present in the last follow-up. The optic pathway lesions exhibited only a slight hyperintensity on long-repetition-time images. In the last study the size of the optic pathways was normal in cases 1 and 2 (Figs 1G, H, and I; 2D and E), whereas the size of the optic chiasm and optic tracts was larger than normal in cases 3 and 4 (Figs 3E and F; 4E and F).

In cases 1, 2, and 4, focal areas of hyperintensity on T2-, proton density-weighted images were detected in the cerebellum and midbrain, basal ganglia, and white matter (Figs 1J and K; 2C; and 4G); these lesions did not change during the follow-up studies. Only in case 1 did a midbrain lesion become more evident in the periaqueductal region over time (Fig 1C, F, and I). In case 3 a midbrain lesion became more extensive, and a new cerebellar lesion appeared during the control studies. Furthermore, in the same case a progressive involvement of the fornix and the anterior commissure with an abnormal enhancement was detected. The lesion caused a hydrocephalus affecting the foramen of Monro (Fig 3A, C, and E).

In cases 1 and 2 an increase in the size of the hypothalamic region with hyperintensity on T2-, proton density-weighted images and contrast enhancement after gadopentetate dimeglumine injection was observed (Figs 1D and F; 2A and B). In the last control study, the en-

hancement was no longer detectable (Figs 1G and H; 2D).

Discussion

Today neurofibromatosis is considered a complex disorder of the neural crest with formation of dysplastic and neoplastic lesions that involve all organs and tissues, in particular the central nervous system. The most typical MR feature of neurofibromatosis type 1 is the presence of focal intraparenchymal areas of hyperintensity on T2-, proton density-weighted images. The foci of T2-proton density hyperintensity do not exhibit mass effect or edema, fail to enhance with gadolinium, and seem to change in size as time passes, particularly in young patients (1, 4-6). In our cases we observed foci of high signal on T2-, proton density-weighted images that did not change during follow-up. Only in one asymptomatic patient were an increase in size of a midbrain lesion and the appearance of a new cerebellar lesion detected. The real nature of these lesions is unknown, and the apparently benign features of focal areas of increased signal have led most authors to suggest that these lesions represent hamartomas or heterotopias (1). Other possible pathologic explanations include low-grade tumor or preneoplastic areas (6).

Optic pathway gliomas are the most common tumors in patients affected by neurofibromatosis type 1; they have an incidence from 15% to 70% according to the different studies (3, 4). Optic pathway gliomas typically appear at an early age and have a peak incidence around 4 to 5 years of age (5). Usually they are limited to one or both optic nerves, but in some cases they involve the posterior optic pathways. Their clinical course is extremely variable. Frequently they are asymptomatic and nonprogressive, and hence have a good prognosis, but sometimes they can enlarge rapidly, leading to visual impairment and exophthalmos. Occasionally they behave in a biologically aggressive fashion, with development of leptomeningeal metastasis (7). The prognosis seems to be poorer when there is a posterior optic pathway involvement, with the possibility of having hydrocephalus and hypothalamic dysfunction (8). The MR manifestations of optic pathway lesions are usually an increase in size, a mild to strong hyperintensity on T2-, proton density-weighted images, and an isohypointensity on T1-

weighted images (4). There is a great variability of enhancement after intravenous injection of gadopentetate dimeglumine.

Very little information concerning the clinical and MR follow-up of optic pathway gliomas in patients affected by neurofibromatosis type 1 is available. One case of spontaneous regression of optic pathway lesions in patients with neurofibromatosis type 1 has been described, but we found no reports about the change of signal intensity and contrast enhancement (9). In our study we observed by means of MR imaging the spontaneous decrease in size, signal intensity, and contrast enhancement of the optic pathway lesions in four patients affected by neurofibromatosis type 1. In these cases, optic pathway lesions, even though they are true masses that can enhance, seem to behave like the white matter lesions; but unlike them, not only signal intensity but also mass size and enhancement vary with time.

The possibility of spontaneous regression of an enhancing neoplasticlike lesion seems to be very uncommon and difficult to explain. Like the white matter lesions, the optic pathway involvement detected by MR in neurofibromatosis type 1 probably represents a spectrum of disease and not a homogeneous group. They range from benign hamartomalike lesions with self-limited growth (8) to very malignant astrocytomas. In addition, optic pathway lesions associated with neurofibromatosis type 1 could have distinct features in comparison with those that arise in patients without phakomatosis. The average age at the time of diagnosis of this tumor is lower in patients with neurofibromatosis than in patients without neurofibromatosis (2).

In our cases the optic pathway lesions could represent dysplastic changes rather than true neoplastic lesions. The change of optic pathway lesions signal and enhancement and hence of the blood-brain barrier integrity could represent the different degree of activity of the lesions,

and the disappearance of the enhancement with time could express the progressive maturation of the blood-brain barrier and the development of new patterns of vascularization.

In conclusion, we found that optic pathway lesions in neurofibromatosis type 1 can regress spontaneously. Those findings underline the extreme heterogeneity of these lesions and may have clinical implications. A screening MR study is recommended in patients with neurofibromatosis type 1, even in the absence of neurologic deficits, to detect clinically silent optic pathway involvement, and serial MR studies are required to follow the evolution of these lesions. No aggressive treatment should be undertaken without follow-up studies, and neurosurgical resection should be limited to those lesions that are clinically and radiologically in progression.

References

1. Mirowitz SA, Sartor K, Gado M. High-intensity basal ganglia lesions on T1-weighted MR images in neurofibromatosis. *AJNR Am J Neuroradiol* 1989;10:1159-1163
2. Brown EW, Riccardi VM, Mawad M, Handel S, Goldman A, Bryan RN. MR imaging of optic pathways in patients with neurofibromatosis. *AJNR Am J Neuroradiol* 1987;8:1031-1036
3. Bognanno JR, Edwards MK, Lee TA, Dunn DW, Roos KL, Klatte EC. Cranial MR imaging in neurofibromatosis. *AJNR Am J Neuroradiol* 1988;9:461-468
4. Aoki S, Barkovich AJ, Nishimura K, et al. Neurofibromatosis types 1 and 2: cranial MR findings. *Radiology* 1989;172:527-534
5. Menor F, Marti-Bonmati L, Mulas F, Cortina H, Olague R. Imaging consideration of central nervous system manifestations in pediatric patients with neurofibromatosis type 1. *Pediatr Radiol* 1991;21:389-394
6. Sevick RJ, Barkovich AJ, Edwards MSB, Koch T, Berg B, Lempert T. Evolution of white matter lesions in neurofibromatosis type 1: MR findings. *AJR Am J Roentgenol* 1992;159:171-175
7. Bruggers CS, Friedman HS, Phillips PC, et al. Leptomeningeal dissemination of optic pathway gliomas in three children. *Am J Ophthalmol* 1991;111:719-723
8. Liu GT, Lessell S. Spontaneous visual improvement in chiasmal gliomas. *Am J Ophthalmol* 1992;114:193-201
9. Brzowski AE, Bazan C, Mumma JV, Ryan SG. Spontaneous regression of optic glioma in a patient with neurofibromatosis. *Neurology* 1992;42:679-681