

The **next generation** GBCA
from Guerbet is here

Explore new possibilities >

Guerbet | 

© Guerbet 2024 GUOB220151-A

AJNR

Multiple myeloma involving the thyroid cartilage.

C W Van Dyke, T J Masaryk and P Lavertu

AJNR Am J Neuroradiol 1996, 17 (3) 570-572

<http://www.ajnr.org/content/17/3/570>

This information is current as
of September 21, 2024.

Multiple Myeloma Involving the Thyroid Cartilage

Carolyn W. Van Dyke, Thomas J. Masaryk, and Pierre Lavertu

Summary: Extraosseous multiple myeloma involving the larynx is rare. We describe a patient with multiple myeloma and a plasmacytoma involving the thyroid cartilage. Ossification of the thyroid cartilage with formation of a marrow space could explain the occurrence of multiple myeloma in this unusual location.

Index terms: Larynx, neoplasms; Multiple myeloma

Case Report

A 62-year-old man had had worsening hoarseness for 6 months and neck swelling for several weeks. Four years earlier a chest wall plasmacytoma with expansile lytic rib destruction was found, and a diagnosis of multiple myeloma was made on the basis of the presence of a markedly elevated serum IgG level, an abnormal serum and urine electrophoresis showing a monoclonal kappa cell population with an M spike, and results of a bone marrow biopsy that revealed normocellular marrow with a monoclonal kappa plasma cell population. The hemoglobin was 12.8 g/dL, hematocrit was 38.7%, and a red blood cell count was $3.62 \times 10^{12}/L$. Other serum and urine chemistries, including blood urea nitrogen, creatinine, and calcium, were normal. A bone survey revealed no additional lytic lesions. Initial chemotherapy, including vincristine, doxorubicin hydrochloride, and dexamethasone, produced a remission, but the patient relapsed, with increasing bone marrow abnormality and increasing chest wall mass 1 year later. Nine months before admission to our institution, multiple bony lesions developed.

Physical examination at the time of presentation revealed an anterior neck mass with the size, shape, and consistency of the thyroid gland. Direct laryngoscopy showed mobile vocal cords with diffuse submucosal swelling involving both the glottic and supraglottic regions without ulceration. A contrast-enhanced helical computed tomographic (CT) scan (Fig 1A) revealed an expansile mass originating within the thyroid cartilage, causing narrowing of the glottis. Results of a needle biopsy of the mass showed plasmacytoma. The patient was treated with radiation therapy (total of 40 Gy over 36 days, in fractionated doses) with resolution of the palpable mass. A follow-up CT scan (Fig 1B) obtained 6

months after radiation therapy showed a marked decrease in the mass and relief of airway stenosis.

Discussion

Plasma cell tumors have classically been divided into three types: multiple myeloma, solitary plasmacytoma of bone, and extramedullary plasmacytoma. The disseminated form, multiple myeloma, is the most frequent, and has the least favorable prognosis. Extramedullary plasmacytoma and solitary plasmacytoma of bone exhibit more benign characteristics and are usually localized, although either may evolve into classical multiple myeloma months to years after initial diagnosis. Both extramedullary plasmacytoma and multiple myeloma may involve the soft tissues. In multiple myeloma, an intraosseous plasmacytoma may spread to adjacent soft tissues or there may be distant metastatic disease. Whether the latter represents hematologic seeding from previous marrow involvement or separate areas of abnormal plasma cell proliferation in tissues already rich in plasma cell populations is unclear (1).

Disseminated extraosseous disease in patients with multiple myeloma is common, although it is usually clinically silent. Autopsy series of patients with multiple myeloma show extraosseous deposits in 71% to 73%, half of which is gross disease, usually of the liver, spleen, and lymph nodes (1, 2). Laryngeal involvement in a patient with known multiple myeloma is rare, and only a few cases have been reported in the English-language literature (1, 3–6). Of these eight reported cases, one involved the false cord and aryepiglottic fold, one the true cord, and three the subglottic region (one additionally involving the true cords).

Received April 4, 1995; accepted after revision August 15.

From the Departments of Radiology (C.W.V.D., T.J.M.) and Otolaryngology (P.L.), Cleveland (Ohio) Clinic Foundation.

Address reprint requests to Carolyn W. Van Dyke, MD, Desk L10, Cleveland Clinic Foundation, 9500 Euclid Ave, Cleveland, OH 44195.

AJNR 17:570–572, Mar 1996 0195-6108/96/1703-0570 © American Society of Neuroradiology

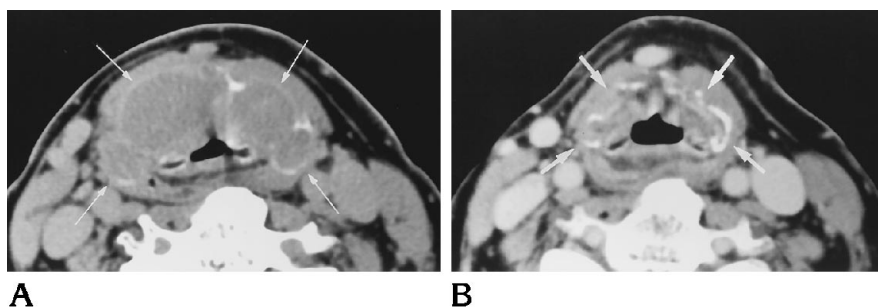


Fig 1. Sixty-two-year-old man with multiple myeloma of the thyroid cartilage.

A, Contrast-enhanced CT scan of the larynx shows plasmacytoma contained within arcs of expanded thyroid cartilage (arrows), causing compression of glottis.

B, Repeat contrast-enhanced CT scan 6 months after radiation therapy shows marked diminution of the mass, with collapse of thyroid cartilage (arrows). Airway size has returned to normal.

The location in the remaining three was not described.

In contradistinction, primary extramedullary plasmacytoma, a localized soft-tissue plasma cell tumor without evidence of multiple myeloma at the time of diagnosis, preferentially involves sites contiguous to the upper respiratory passages (7–9). The larynx is involved in 5% to 18% of cases (7, 10, 11), and at least 88 cases have been reported (6, 8, 11, 12). The relationship between multiple myeloma and extramedullary plasmacytoma is controversial (4, 10, 11, 13). Extramedullary plasmacytoma has a much better prognosis, with a 5-year survival of 33% to 75% (14), as compared with 18% in multiple myeloma (13). However, multiple myeloma may develop in patients with extramedullary plasmacytoma months to many years after initial diagnosis (8, 15). Nearly all plasmacytomas of the larynx represent extramedullary plasmacytoma rather than extraosseous multiple myeloma.

There have been several reports of involvement of the cricoid cartilage by plasmacytomas, both in patients with multiple myeloma (5, 13, 16) and in those with extramedullary plasmacytoma (17). There are two postulated mechanisms for cartilaginous involvement. First, cartilage may be invaded by an adjacent plasmacytoma (5, 17). Second, cartilage, particularly in older patients, may undergo osseous metaplasia with formation of a true central marrow space, and plasmacytomas could originate directly within this marrow (16). Osseous metaplasia has been previously documented in both the cricoid and the thyroid cartilage (9, 13, 16), and plasmacytoma occurring within an ossified cricoid cartilage has been confirmed pathologically (16). Although the presence of both red marrow and plasmacytoma within a cartilage would suggest an etiologic relationship, especially since multiple myeloma usually develops within bone

marrow, documentation of this is difficult, given the rarity of cartilaginous plasmacytomas with either multiple myeloma or extramedullary plasmacytoma.

Is a plasmacytoma that arises in the marrow space of an ossified cartilage intraosseous or extraosseous? Although it could be argued that cartilage that has undergone bony metaplasia is essentially bone, and that this is merely just another intraosseous myelomatous lesion, the term *extraosseous* is believed to be a more accurate description. First, ossified cartilage is not developmentally true bone, even though there has been some structural change. Second, to term this lesion *intraosseous* tends to equate this rare presentation with the ordinary intramedullary lesion seen in nearly all patients with multiple myeloma, and would suggest that this is a relatively common occurrence when osseous metaplasia is present. It is notable that although osseous metaplasia of cartilage is frequent, especially in older age groups, myelomatous involvement of cartilage is quite rare.

It is likely, although there is no pathologic confirmation, that the plasmacytoma in this case arose in a region of osseous metaplasia of the thyroid cartilage. The pattern of involvement, with thinning and expansion of the lamina, strongly suggests origin within the thyroid ala rather than erosion by an adjacent plasmacytoma. A soft-tissue plasmacytoma with secondary destruction of the thyroid cartilage should not cause uniform expansion, and no soft-tissue mass was present adjacent to the thyroid cartilage. Occurrence in an area of osseous metaplasia of the thyroid cartilage, however, would explain both the central location of the tumor and the “exploded” appearance of the thyroid cartilage.

Conclusion

Plasmacytoma involving the larynx is rare and usually represents primary extramedullary

plasmacytoma without multiple myeloma, although metastatic myeloma to the larynx has been reported. The pattern of involvement in this case, with marked expansion and destruction of the thyroid cartilage in a patient with known myeloma, suggests myelomatous involvement of extraskeletal marrow formed by osseous metaplasia of the thyroid cartilage rather than soft-tissue metastatic disease. Extramedullary plasmacytoma and extraosseous multiple myeloma, although rare, should be considered when destruction of a laryngeal cartilage is seen.

References

1. Hayes DW, Bennett WA, Heck FJ. Extramedullary lesions in multiple myeloma. *Arch Pathol* 1952;53:262-272
2. Churg J, Gordon AJ. Multiple myeloma: lesions of the extraosseous hematopoietic system. *Am J Clin Pathol* 1950;20:934-945
3. Agarwal MK, Samant HC, Gupta OP, Khanna S. Multiple myeloma invading the larynx. *Ear Nose Throat J* 1981;60:395-397
4. East D. Laryngeal involvement in multiple myeloma. *J Laryngol Otol* 1978;92:61-65
5. Georgiou PR, Hogg ML. Immunoglobulin A myeloma presenting with laryngeal obstruction. *Med J Aust* 1988;149:447-449
6. Maniglia AJ, Xue JW. Plasmacytoma of the larynx. *Laryngoscope* 1983;93:741-744
7. Wax MK, Yun KJ, Omar RA. Extramedullary plasmacytomas of the head and neck. *Otolaryngol Head Neck Surg* 1993;109:877-885
8. Mochimatsu I, Tsukuda M, Sawaki S, Nakatani Y. Extramedullary plasmacytoma of the larynx. *J Laryngol Otol* 1993;107:1049-1051
9. Wiltshaw E. The natural history of extramedullary plasmacytoma and its relation to solitary myeloma of bone and myelomatosis. *Medicine* 1976;55:217-238
10. Poole AG, Marchetta FC. Extramedullary plasmacytoma of the head and neck. *Cancer* 1968;22:14-21
11. Kost KM. Plasmacytomas of the larynx. *J Otolaryngol* 1990;19:141-146
12. Weissman JL, Myers JN, Kapdia SB. Extramedullary plasmacytoma of the larynx. *Am J Otolaryngol* 1993;14:128-131
13. Rutka J, Noyek AM, Chapnik JS, Amato D, Couter N, Steinhardt MI. Multiple myeloma involving the cricoid cartilage. *J Otolaryngol* 1985;14:309-312
14. Barbu RR, Khan A, Port JL, Abramson A, Gartenhaus WS. Case report: extramedullary plasmacytoma of the larynx. *Comput Med Imaging Graph* 1992;16:359-361
15. Webb HE, Harrison EG, Masson JK, ReMine WH. Solitary extramedullary myeloma (plasmacytoma) of the upper part of the respiratory tract and oropharynx. *Cancer* 1962;15:1142-1155
16. Jones NS, Kenyon GS, Mahy N. Multiple myeloma in bony metaplasia of the cricoid cartilage. *J Laryngol Otol* 1987;101:1301-1305
17. Gormley PK, Primrose WJ, Bharucha H. Subglottic plasmacytoma of the larynx: an acute presentation. *J Laryngol Otol* 1985;99:925-929