Are your MRI contrast agents cost-effective?
Learn more about generic Gadolinium-Based Contrast Agents.
FRESENIUS KABI
caring for life

AJNR

Must radiation dose for CT of the maxilla and mandible be higher than that for conventional panoramic radiography?

C G Diederichs, W G Engelke, B Richter, K P Hermann and J W Oestmann

AJNR Am J Neuroradiol 1996, 17 (9) 1758-1760
http://www.ajnr.org/content/17/9/1758

This information is current as of April 19, 2024.

Must Radiation Dose for CT of the Maxilla and Mandible Be Higher than That for Conventional Panoramic Radiography?

Christoph G. Diederichs, Wilfried G. H. Engelke, Britta Richter, Klaus-Peter Hermann, and Joerg W. Oestmann

Summary: We evaluated the feasibility of performing preoperative spiral CT of the maxilla and mandible with a radiation dose similar to that used for conventional panoramic radiography. The skin entrance doses of radiation used for spiral CT (collimation, 1 mm; pitch, 2; tube voltage, 80 kV; tube current, 40 mA) and for panoramic radiography (75 kV, 8 mA, 15 seconds) were measured in one patient by using thermoluminescent dosimeter chips. Results were 0.56 ± 0.06 mGy for CT and 0.59 ± 0.04 mGy for radiography. Image quality was adequate for preoperative implant planning. Spiral CT of the mandible and maxilla may therefore be feasible with a radiation dose of similar magnitude as that used for conventional panoramic radiography.

Index terms: Radiation, dose; Temporomandibular joint, computed tomography

Routine panoramic radiography for preoperative assessment for implant surgery has some limitations in regard to the alveolar crest and alveolar nerve: the alveolar nerve may not be seen; magnification of the anatomy is not uniform, the images are slightly distorted; the imaging plane predetermined by the manufacturer may not be congruent with the shape of the dental arches under study; and cross-sectional anatomy is not appreciated.

High-resolution computed tomography (CT) combined with cross-sectional and panoramic reformations enables the determination of height, width, and angulation of the alveolar ridge as well as the distance between the alveolar crest and the mandibular canal, the floor of the maxillary sinus, and the nasal cavity. Cross-sectional reformations are important in assessing the quality of bone in a given area. The images are free of overlying structures and have a spatial resolution of less than 1 mm. High-resolution CT with dental software reformations has become a powerful tool in preoperative planning (1–3).

One disadvantage of high-resolution CT is that it requires a higher radiation dose than that used for conventional radiography (4, 5). In one in vitro experiment that simulated the combined high-resolution CT examination of the mandible and maxilla, absorbed doses of up to 19 mGy were measured at the parotid glands (Table 1). On the other hand, the absorbed doses for the parotid glands in conventional panoramic radiography are generally less than 1 mGy, so the difference is 20-fold or greater.

Application and Discussion

In the present study, a 55-year-old patient with an edentulous upper left molar region

TABLE 1: Dose-relevant scanning parameters of two CT protocols

	Kassebaum et al (5)	Present Study	Dose-Reduction Factor
Mode	Dynamic serial	Spiral	. . .
Collimation	1.5 mm	1.0 mm	1.5
Spacing	1 mm	. . .	. . .
Tube voltage	140 kV	80 kV	3 – 4*
Tube current	70 mA	40 mA	1.75
Scan time per millimeter of table position	2 s	0.5 s†	4
Measured dose‡	16 – 19 mGy	0.6 mGy	27 – 32

Note.—The total difference in dose between the two CT protocols may be calculated from the product of the dose-reduction factors and should therefore be 30 to 40. This is in accordance with the dose-reduction factor obtained from the measured dose values.

* Estimation according to results from Felsenberg et al (4).

† Corresponds to a table-feed factor (pitch) of 2.

‡ For subcutaneous organs the values for skin entrance and absorbed doses are comparable within 5% (6).

Received September 25, 1995; accepted after revision January 31, 1996.

From the Departments of Radiology I (C.G.D., J.W.O.), Oral Surgery (W.G.H.E.), and Medical Physics and Biophysics (B.R., K-P.H.), Georg-August-University of Goettingen (Germany).

Address reprint requests to Christoph G. Diederichs, MD, Department of Radiology III, University Clinics of Ulm, Robert-Koch-Str 8, D-89070 Ulm, Germany.

AJNR 17:1758–1760, Oct 1996 0195-6108/96/1709–1758 © American Society of Neuroradiology

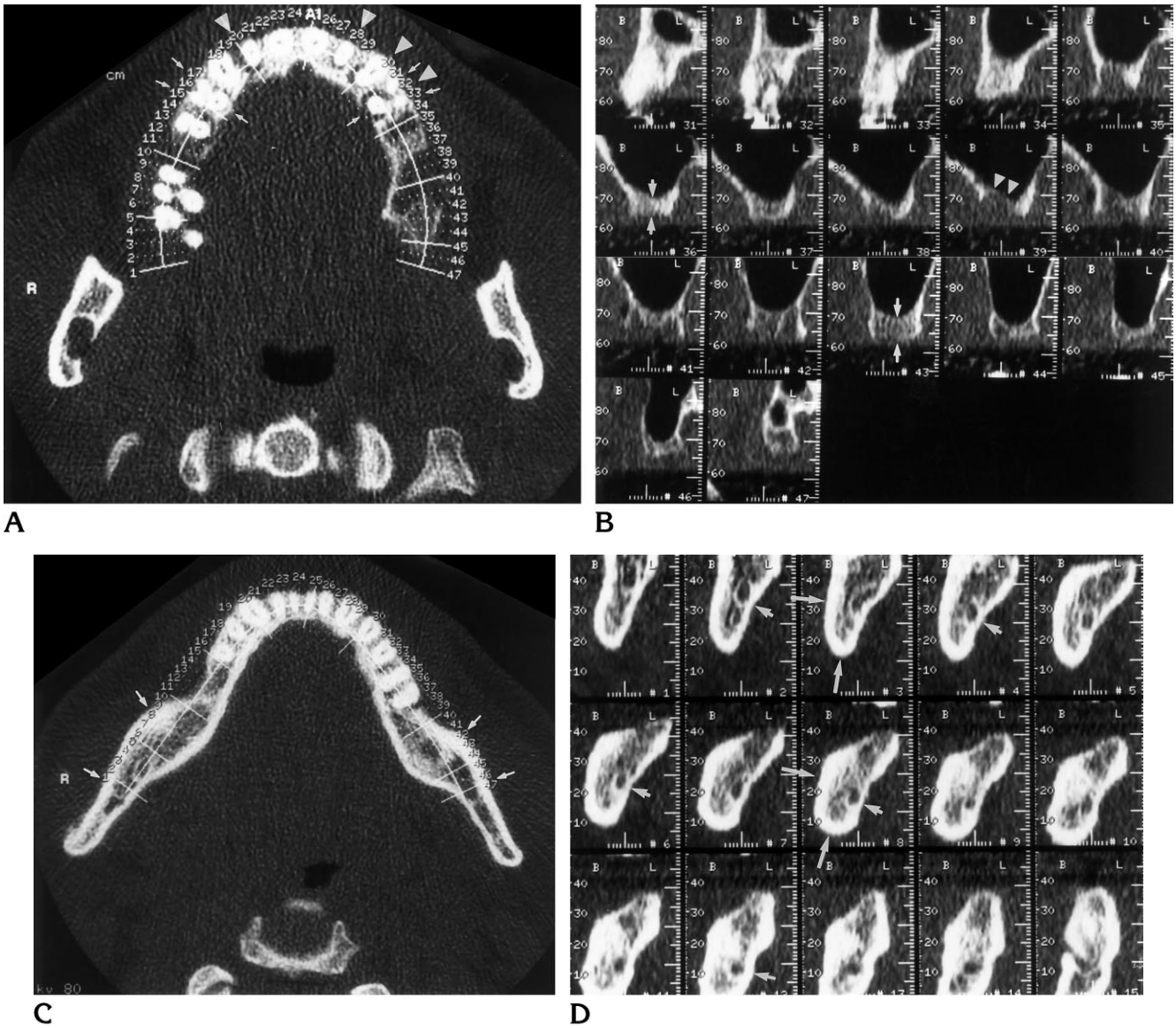

Fig 1. *A*, Axial image through the palatine alveolar crest shows an edentulous left molar region and a superimposed curve parallel to the alveolar crest. Numbered lines automatically drawn perpendicular to this curve define the location of the cross-sectional reformations seen in *B*. Numbers appear in the lower right of cross sections. The periradicular osteolysis of both the lateral incisors, the left canine, and the left first premolar (*arrowheads*) are clearly discernible. The first premolars each have three roots (*arrows*).

B, Cross-sectional images precisely display the anatomy of the alveolar crest, which has a maximum depth of 6 mm (images 36, 37, 43, 44; *arrows*). Osteolysis after the loss of the molars is displayed in images 38 to 42 (*arrowheads*). The maxillary sinus is not affected by secondary sinusitis.

C, Axial image with two-dimensional reconstruction planning curves shows a thick lateral compacta at the ramus (*arrows*). This was thought to be a suitable donor site for intraosseal bone transplantation.

D, These reformations of the mandible provide an additional cross-sectional display of the thick lateral and basal compacta (*long arrows*) and illustrate the course of the alveolar nerve, which is situated near the thinner lingual compacta (*short arrows*).

elected to have implant surgery. In addition to conventional panoramic radiography, high-resolution spiral CT of the maxilla and mandible was performed to display the extent of crest atrophy and to define optimal donor sites for an autologous transplant. The skin entrance doses on both upper eyelids, the parotid glands, and the thyroid (left and right lobes) were measured on the panoramic radiograph and on the combined mandibular and maxillary CT scan by using lithium fluoride thermoluminescent dosimeter (TLD) chips. The conventional and CT studies were performed less than 1 hour apart. It was ensured that the chips located at the pa-

rotid glands were inside the CT scanning volume. This was done by checking that the start and end position of the scan (as marked by the laser grid of the gantry on the patient's skin) were located well superior and inferior to the parotids. Three chips of $3 \times 3 \times 1$ mm^3 with a mass of 24.7 mg were used at each location (36 chips). All chips used were calibrated and read out on the same day under identical conditions.

The settings of the conventional panoramic radiograph were 75 kV, 8 mA, and 15 seconds exposure time. A helical scanner was used for the CT examination. A lateral digital scout view (80 kV, 40 mA, extending from the lower orbital rim to the tip of the jaw) was obtained to check the patient's position and to define the upper and lower limits of the study. The gantry was tilted parallel to the alignment of the teeth. One spiral CT scan from the caudal portions of the mandible extending into the maxillary sinus was acquired in 36 seconds with a collimation width of 1 mm and a pitch (ratio of table increment per gantry rotation to collimation) of 2. This corresponds to a scanning distance of 72 mm perpendicular to the gantry. The tube current was 40 mA. Because the tube current could not be reduced further, a tube voltage of 80 kV was used instead of the usual 120 kV. Radiation penetration of large skulls may be insufficient with 80 kV, and, if possible, we recommend using a tube voltage of 120 kV and a tube current lower than 40 mA instead. The scan reconstruction interval was 0.8 mm, resulting in 91 overlapping images. Axial images were transmitted to a free-standing workstation (Sparc Station 10, Sun Microsystems, Mountain View, Calif). A commercially available dental program (Dentascan, Advantage Windows, General Electric, Buc, France) was used by the radiologist to reformat panoramic and cross-sectional (frontal) images of both the maxilla and mandible (Fig 1). The results of the dosimetry are summarized in Table 2.

Even though the CT scans are displayed with a large window width of 4000 HU, noise is clearly discernible. As a consequence, contours of compact bones are slightly ragged, and low-contrast structures like spongy bone cannot clearly be differentiated from noise. This patient's head was considered large, but other patients may have even larger heads and a bigger bone mass, which would further add to image noise. Also, with other patients, the alveolar nerve may be shielded by thinner or atrophic spongy bone, which may be disguised by noise as well. However, all anatomic information important for surgical planning could be clearly obtained from this CT examination (Fig 1).

TABLE 2: Skin entrance doses, mGy, at conventional panoramic radiography and CT

Detector Position	Panoramic Radiograph	High-Resolution Spiral CT
R eye	<0.01	<0.01
L eye	<0.01	<0.01
R parotid gland	0.591 ± 0.058	0.476 ± 0.060
L parotid gland	0.581 ± 0.022	0.639 ± 0.078
R thyroid gland	<0.01	<0.01
L thyroid gland	<0.01	<0.01

Note.—There was no difference in radiation dose for panoramic radiography and CT. The measured values for conventional radiography are within normal limits of another study (Matheis B, *Bestimmung der Strahlenexposition des Patienten bei der parodontologischen Röntgendiagnostik mit Hilfe der Thermolumineszenzdosimetrie* [*Measurement of Exposed Dose with Parodontologic Roentgenography Using Thermoluminescent Dosimetry*], Göttingen, Germany: University of Göttingen, 1995, thesis), in which an average of 0.55 ± 0.18 mGy was measured for 22 patients. The radiation dose for CT of the left parotid gland was higher than that for the right side. This was due to the left lateral position of the tube during the acquisition of the digital radiograph (scout view).

In summary, a CT protocol with a reduced radiation dose down to the level of a single panoramic radiograph was feasible with one patient. Larger patient studies are necessary to identify limitations and possible pitfalls.

References

1. DelBalso AM, Greiner FG, Licata M. Role of diagnostic imaging in evaluation of the dental implant patient. *Radiographics* 1994;14:699–719
2. Abrahams JJ. The role of diagnostic imaging in dental implantology. *Radiol Clin North Am* 1993;31:163–180
3. Rothman SLG, Chafetz N, Rhodes ML, Schwartz MS. CT in the preoperative assessment of the mandible and maxilla for endosseous implant surgery. *Radiology* 1988;168:171–175
4. Felsenberg D, Kalender WA, Trinkwalter W, Wolf KJ. CT-Untersuchungen mit reduzierter Strahlendosis (CT examinations with reduced radiation dose). *Rofo Fortschr Geb Rontgenstr Neuen Bildgeb Verfahr* 1990;153:516–521
5. Kassebaum DK, Stoller NE, McDavid WD, Goshorn B, Ahrens CR. Absorbed dose determination for tomographic implant site assessment techniques. *Oral Surg Oral Med Oral Pathol* 1992;73:502–509
6. Hubbell JH. Photon mass attenuation and mass energy absorption coefficients for H, C, N, O, Ar and seven mixtures from 0.1 KeV to 20 MeV. *Radiat Res* 1977;70:58–81