This information is current as of October 12, 2024.

Polyvinyl alcohol particle superficial morphology.

A Falini, C Righi, G Scotti, A Colombo, C Tanzi and L Trovesi

AJNR Am J Neuroradiol 1997, 18 (1) 194-195
http://www.ajnr.org/content/18/1/194.citation

LETTERS

Polyvinyl Alcohol Particle Superficial Morphology

We appreciated the research by Derdeyn et al (1) from the Mallinckrodt Institute of Radiology concerning the size and suspension characteristics of polyvinyl alcohol (PVA) particles. We do agree that both size and suspension characteristics of PVA represent relevant parameters affecting the aggregation of particles during injection. In addition to these two variables, we considered further parameters that could influence particle behavior.

Using scanning electron microscopy and differential scanning calorimetry, we observed some differences between dry and suspended particles and between particles produced by different manufacturers. We noticed that particles of Contour Emboli (720 to 1000 μm) (produced in dry form by Interventional Therapeutics Corp, Fremont, Calif) are characterized by a very homogeneous, smooth, regularly punched surface (Fig 1). On the contrary, Ivalon particles of the corresponding size (600 to 1000 μm) (produced in both dry and suspended form by Nycomed Ingenor, Paris, France) demonstrate an irregular, rough surface with folded lamellas (Fig 1B). Such spicules are less pronounced in the dry form of Ivalon, which is less irregular than the suspended one. Moreover, calorimetric analysis showed that both forms of Ivalon particles had a glass transition temperature exceeding that of the Contour Emboli by 10°C. Such significant delta suggests the presence of structural differences between the PVA particles produced by the two manufacturers, which could be related to different production processes.

We are carrying on further studies to understand whether these morphological and structural differences affect aggregation characteristics both during injection and after interaction with blood. In fact, although surface irregularities can hamper the injection procedure, the same factor could interfere favorably with thrombogenic processes.

Andrea Falini
Claudio Righi
Giuseppe Scotti
Department of Neuroradiology
Scientific Institute H. S. Raffaele
University of Milan (Italy)

Andrea Colombo
Cristina Tanzi
Lara Trovesi
Department of Bioengeneering
Politecnico of Milan (Italy)

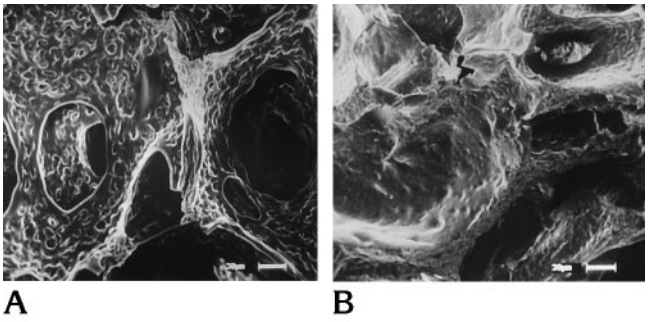

Fig 1. On scanning electron microscopy with magnification ×900, Contour emboli surface appears very homogeneous and regularly punched (*A*); Ivalon particles are characterized by an irregular rough surface with spicules (*B*). Scale bar = 30 μm.

Reference

1. Derdeyn CP, Mora CJ, Cross DT, Dietrich HH, Dacey RG Jr. Polyvinyl alcohol particle size and suspension characteristics. *AJNR Am J Neuroradiol* 1995;16:1335–1343

Reply

We thank Falini and colleagues for their interest in our work with PVA (1). The ideal embolic agent, liquid or particulate, has yet to be developed. PVA remains an important tool for therapeutic embolization, despite problems with particle delivery and the potential for vessel recanalization, because of its availability, biocompatibility, and relatively low risk of inadvertent ischemic injury.

However, the transcatheter delivery of PVA may be complicated by particle aggregation at the hub and catheter occlusion. Herrera et al (1) suggested that the surface charge of the particles may be responsible for aggregation and that this might be overcome by adding albumin to the suspension. Horton et al (2) hypothesized that irregular PVA particles tumble and roll through the catheter, creating a high coefficient of friction. They found that adding absorbable gelatin sponge to the PVA suspension improved the ease of delivery of the particles. We found that dry PVA particles swell significantly when suspended in contrast and saline. After suspension of dry 500- to 700-μm particles, the intermediate axes (the size-limiting diameter of an oval particle) often exceeded the luminal diameter of a microcatheter.

Falini and colleagues suggest that differences in the morphology of the particles might also affect how they behave within a catheter or in a vessel. In addition, there may be fundamental differences in particle structure between different manufacturers, as suggested by the differences they observed in the glass transition temperature. These structural properties might also affect the behavior of the particles.

We eagerly look forward to the results of the studies being pursued by Falini and colleagues. We hope we will gain a better understanding of the behavior of PVA, both in the catheter and in the vessel.

Colin P. Derdeyn
Christopher J. Moran
DeWitte T. Cross III
Interventional Neuroradiology
Neuroradiology Section
Mallinckrodt Institute of Radiology
Washington University School of Medicine
St Louis, Mo

References

1. Herrera M, Rysavy J, Kotula F, Rusnak B, Casteneda-Zuniga WR, Amplatz K. Ivalon shavings: technical considerations of a new embolic agent. *Radiology* 1982;144:638–640
2. Horton JA, Marano GD, Kerber CW, Jenkins JJ, Davis S. Polyvinyl alcohol foam–gelfoam for therapeutic embolization: a synergistic mixture. *AJNR Am J Neuroradiol* 1983;4:143–147

Editor's note.—*The letter of Falini et al was referred to Phillip D. Purdy for additional comment.*

Comment

The paper by Derdeyn et al and letter by Falini et al illustrate investigative work now being done on the exact characteristics of PVA particles. The first step in understanding those characteristics is understanding the morphology of the particles. The next, more difficult step is understanding the behavior of the particles in vivo. The presence of spicules on the surface of particles has been postulated to contribute to "stickiness" of the particles in the blood vessels. This is implied by the last sentence in Falini's letter. However, establishing this feature is, itself, a sticky matter.

This issue is of more than passing interest. New particles under investigation from at least one manufacturer (Micro Interventional Systems Inc, Sunnyvale, Calif) are hydrophilic, smooth, and spherical. The only factor in their use will be particle size. They offer the potential to improve injection characteristics. However, if a spiculated contour contributes to vascular adhesion and subsequent occlusion, PVA may retain some advantages. Thus, these newly published studies regarding the characteristics of PVA should be seen as the important beginning investigations of biological behavior. Standards for evaluation of particulate emboli are needed for future cross comparisons.

Phillip D. Purdy
Division of Neuroradiology
Department of Radiology
University of Texas Southwestern Medical Center
Dallas

Location of Pyramidal and Spinothalamic Tracts

We read with interest "MR Findings in Adult-Onset Adrenoleukodystrophy" by Kumar et al (1) in the June/July issue of *AJNR* (1). The authors stated that involvement of the corticospinal tract was the most common of the brain abnormalities in male patients with adrenomyeloneuropathy. Based on studies of patients with amyotrophic lateral sclerosis and cerebral infarction, it has been recognized that the corticospinal tract lies in the posterior third quarter of the posterior limb of the internal capsule (ie, third region from the anterior pole when the posterior limb is divided into four equal parts) (2–4). Furthermore, it has been reported that normal hyperintense foci in the internal capsule on T2-weighted images represent fibers of the corticospinal tract (4–6). In their Figure 2C, Kumar et al showed three hyperintense lesions in the right internal capsule on a proton density–weighted image, representing demyelination of the pyramidal fibers. Two anterior lesions were in the anterior part of the posterior limb, whereas the third was in the posterior part of the posterior limb. There was an area of normal signal intensity between the second and third lesions in the posterior limb. Our report, which contains imaging and pathologic findings (4), and previous anatomic studies (2, 3) indicated that the corticospinal fibers in the internal capsule occupy a small compact space in the posterior third quarter of the posterior limb. In the report of Kumar et al, we feel that the two anterior lesions were too anterior to represent corticospinal fibers. If all three lesions represented demyelination of the corticospinal fibers, we would ask why the corticospinal fibers were separated. Why did the corticospinal fibers occupy such a long space in the internal capsule? Moreover, how did they identify the corticospinal tract in the internal capsule?

Kumar et al stated that spinothalamic tract demyelination could be identified as the tracts went through the thalamic nuclei. In their Figure 2B, they showed that abnormal hyperintensity represented the spinothalamic tract demyelination in a section at the level of the third ventricle and thalamus. It is important to define the location of the spinothalamic tracts on MR images. However, we could find the ventral posterolateral nucleus of the thalamus, but not the spinothalamic tracts, in the lower thalamic level on a neuroanatomic atlas (7). We would like to ask how they identified the spinothalamic tract at the level of the thalamus.

Akira Yagishita
Department of Neuroradiology
Tokyo (Japan) Metropolitan Neurological Hospital

Imaharu Nakano
Department of Neuropathology
Tokyo (Japan) Metropolitan Institute for Neuroscience

References

1. Kumar AJ, Köhler W, Kruse B, et al. MR findings in adult-onset adrenoleukodystrophy. *AJNR Am J Neuroradiol* 1995;16:1227–1237
2. Hirayama K, Tsubaki T, Toyokura Y, Okinaka S. The representation of the pyramidal tract in the internal capsule and basis pedunculi. *Neurology* 1962;12:337–342
3. Englander RN, Netsky MR, Adelman LS. Location of human pyramidal tract in the internal capsule: anatomic evidence. *Neurology* 1975;25:823–826
4. Yagishita A, Nakano I, Oda M, Hirano A. Location of the corticospinal tract in the internal capsule at MR imaging. *Radiology* 1994; 191:455–460
5. Curns JT, Burger PC, Djang WT, Boyko OB. MR imaging of compact white matter pathways. *AJNR Am J Neuroradiol* 1988;9: 1061–1068
6. Cheung G, Gawal MJ, Cooper PW, Farb RI, Ang LC. Amyotrophic lateral sclerosis: correlation of clinical and MR imaging findings. *Radiology* 1995;194:263–270
7. Riley HA. *An Atlas of the Basal Ganglia, Brain Stem and Spinal Cord Based on Myelin-Stained Material.* Baltimore, Md: Williams & Wilkins; 1943;334–338

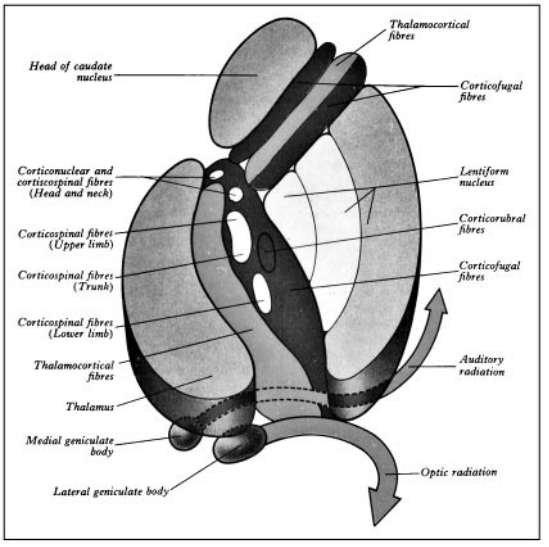

Fig 2. Main components of the internal capsule (from Gray [2]) after Strong and Elwyn [3]).

Reply

In our Figure 2C, the demyelinated pyramidal fibers in the posterior limb of the internal capsule are outlined by black open arrows. This finding was based on an anatomic description of the main components of the posterior limb of the internal capsule as outlined in *Gray's Anatomy* (1). The reference states, "The posterior limb includes the corticospinal tract in scattered bundles, the fibres connected with the upper limb being anterior and followed by those for the trunk and lower limbs." A diagram from *Gray's Anatomy* (Fig 2) can help to explain some of the findings exhibited in Figure 2C in our article. The more anterior hyperintense areas (black open arrows in our Figure 2C) in the anterior portion of the posterior limb of the internal capsule represent corticospinal fibers connected with the upper limb, whereas the more posterior hyperintense areas in the posterior portion of the posterior limb of the internal capsule (black open arrows in our Figure 2C) represent corticospinal fibers in the lower limb. This can explain the normal signal intensity between hyperintense areas.

However, there appear to be alternative views, even among neuroanatomists, regarding the position of corticospinal tracts in the internal capsule. The work of Kretschmann et al (4) states that the corticospinal fibers change their relative position as they course through the internal capsule. In the superior portion of the internal capsule, at the level of the interventricular foramen, the pyramidal tract is located in the middle of the posterior limb, and in the inferior portion, at the level of the subthalamic nucleus and metathalamus, in the posterior third of the posterior limb. However, the work of Yagishita et al indicates that the corticospinal fibers in the internal capsule occupy a small, compact space in the posterior third quarter of the posterior limb. *Thus, there is probably some variability in the course of corticospinal fibers in the internal capsule in different persons.*

Spinothalamic tracts (small white arrows in our Figure 2B) are identified by the location of tracts emanating from the ventral posterolateral nucleus of the thalamus and the clinical symptoms of the spinothalamic tract involvement. Our Figure 2B is a slightly angled section of the brain, probably accounting for the visibility of the spinothalamic tracts at the level of the thalamus. However, we would like to emphasize that it is often difficult to separate these tracts, because corticospinal tracts and audiovisual tracts merge with each other, as emphasized in the text.

I thank Drs Yagishita and Nakano for their comments. The purpose of our paper was to outline broadly the MR findings of adrenoleukodystrophy in adults with strong, clinical evidence of demyelination of various tracts in the brain, not to challenge the differing neuroanatomists' views.

A. J. Kumar
Diagnostic Radiology
The Unviersity of Texas
M. D. Anderson Cancer Center
Houston

References

1. Gray H. *Gray's Anatomy*. 37th ed. Edinburgh, Scotland: Churchill Livingstone; 1989:1073
2. Gray H. *Gray's Anatomy*. 37th ed. Edinburgh, Scotland: Churchill Livingstone; 1989:1078
3. *Strong & Elwyn's Human Neuroanatomy*. 5th ed. Baltimore, Md: Williams & Wilkins; 1964:43
4. Kretschmann HJ. Localisation of the corticospinal fibres in the internal capsule in man. *J Anat* 1988;160:219–225