

Are your **MRI contrast agents** cost-effective?

Learn more about generic **Gadolinium-Based Contrast Agents**.



**FRESENIUS
KABI**

caring for life

AJNR

Myelolipoma of the thoracic spine.

D G Omdal, D E Baird, B S Burton, W W Goodhue, Jr and E M Giddens

AJNR Am J Neuroradiol 1997, 18 (5) 977-979

<http://www.ajnr.org/content/18/5/977>

This information is current as
of April 19, 2024.

Myelolipoma of the Thoracic Spine

David G. Omdal, Dean E. Baird, Bradford S. Burton, William W. Goodhue, Jr, and Eugene M. Giddens

Summary: We describe a myelolipoma of the thoracic spine in a patient with gradual and progressive myelopathy. MR imaging showed this predominately fatty lesion to be extradural in location.

Index terms: Spine, neoplasms; Lipoma

Myelolipomas are rare, benign, nonfunctioning tumors typically found in the adrenal gland. Extraadrenal myelolipomas are even less common (1–12). We report a case of a myelolipoma of the thoracic spine.

Case Report

A 49-year-old man had progressive bilateral lower extremity numbness and gait disturbance. He reported that his initial symptoms had begun approximately 6 months previously as intermittent numbness in both feet. Three to four months later, these sensory changes had begun to progress slowly into both legs until, finally, approximately 2 weeks before admission, he had increased numbness to the level of the umbilicus, progressive difficulty coordinating gait, pain and stiffness of the back, and the onset of intermittent bladder incontinence.

Physical examination confirmed decreased sensation to the level of the umbilicus, decreased lower extremity proprioception, and bilateral lower extremity weakness. There were no other signs or symptoms of acute or chronic disease. A magnetic resonance (MR) examination of the spine revealed an epidural mass situated posteriorly in the canal extending from the T-1 through T-10 levels (Fig 1A–D).

The patient was placed on intravenous methylprednisolone and reported subjective improvement in lower extremity sensation and less back stiffness. He was taken to surgery for a T-1 through T-10 laminectomy and resection of the thoracic spinal lesion. The mass was excised in multiple fragments, all with soft yellow and friable red-purple areas corresponding microscopically to mature fat and blood-forming tissue. The latter showed 80% cellularity, a 2:1 myeloid:erythroid ratio, and occasional lymphoid aggregates devoid of germinal centers (Fig 1E).

Owing to the highly vascular nature of the lesion, intraoperative blood loss was over 2500 mL, requiring transfusion of 3 U of packed red cells intraoperatively and 2 U postoperatively. The patient was discharged on the 12th postoperative day with significant improvement in his gait disturbance and lower extremity numbness. A follow-up MR study obtained 2 months after surgery showed no evidence of residual or recurrent tumor and resolution of the increased cord signal. At present, the patient is 10 months from surgery and reports subjective resolution of all symptoms.

Discussion

Extraadrenal myelolipomas are usually single, well-circumscribed, encapsulated masses most commonly seen in middle-aged to elderly persons with a 2:1 female predominance. Approximately half are located in the presacral region followed by mediastinal, perirenal, hepatic, and gastric sites in decreasing frequency. Extraadrenal myelolipomas are postulated to arise from metaplasia of previously uncommitted mesenchymal cells or from choristomatous hematopoietic stem cells carried to ectopic sites during fetal life. As such, it is unclear whether these growths represent hyperplasia, choristomas, or neoplasia. Nonetheless, they must be distinguished from extramedullary hematopoiesis tumors, which are associated with chronic anemias, myeloproliferative syndromes (1, 2), and some skeletal disorders (13).

Fowler et al (2) provided criteria for differentiating extraadrenal myelolipoma from extramedullary hematopoiesis tumor. Patients with extraadrenal myelolipomas, unlike those with extramedullary hematopoiesis tumors, typically have no history of chronic anemia, hepatosplenomegaly, or skeletal disorders predisposing to marrow extrusion. The variegated

Received February 7, 1996; accepted after revision August 16.

The opinions or assertions contained herein are the private views of the authors and are not to be construed as official or as reflecting the views of the Department of the Army, Department of Defense, or Tripler Army Medical Center.

From the Departments of Radiology (D.G.O., D.E.B., B.S.B.), Pathology (W.W.G.), and Neurosurgery (E.M.G.), Tripler Army Medical Center, Honolulu, Hawaii.

Address reprint requests to Bradford S. Burton, MD, Department of Radiology, Tripler Army Medical Center, Honolulu, HI 96859-5000.

AJNR 18:977–979, May 1997 0195-6108/97/1805-0977 © American Society of Neuroradiology

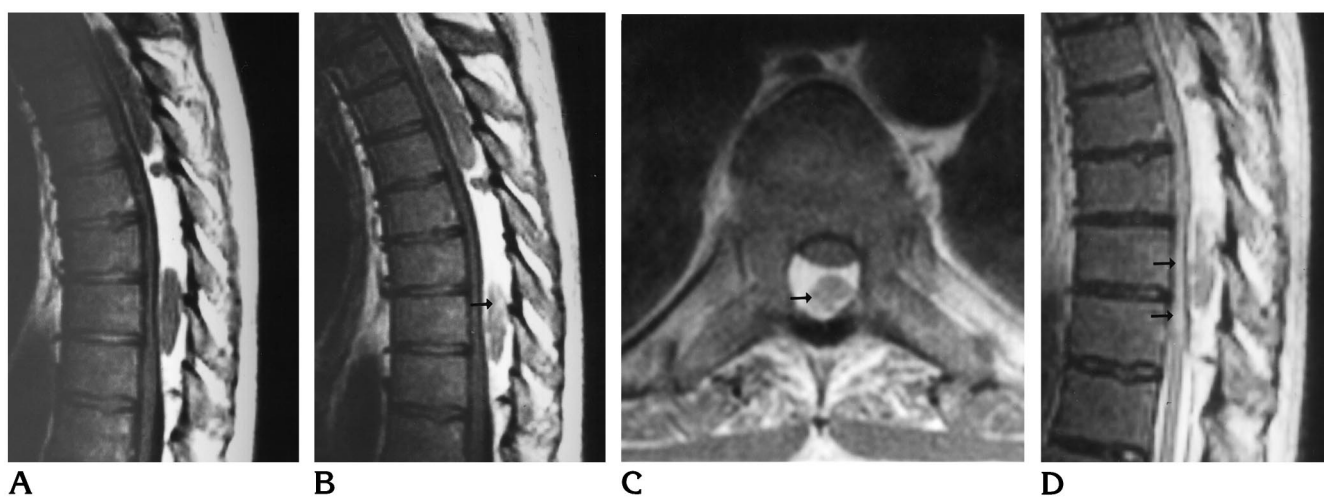


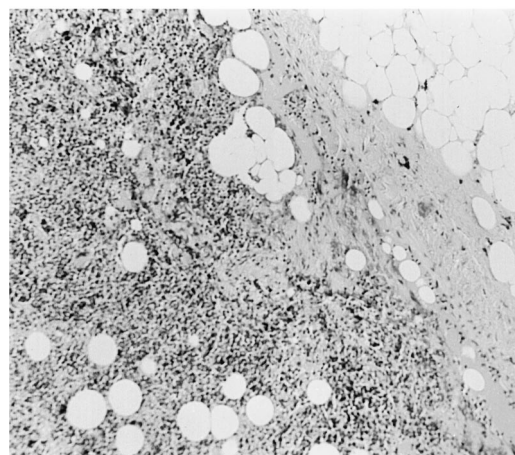
Fig 1. A 49-year-old man with myelolipoma of the thoracic spine.

A, Sagittal T1-weighted (400/15/2 [repetition time/echo time/excitations]) MR image shows an elongated epidural mass situated posteriorly in the spinal canal extending from the T-1 through the T-10 levels. The lesion compresses and displaces the cord anteriorly, most severely at the T-4 through T-8 levels. Note the predominately hyperintense T1 signal of the mass with focal regions of intermediate signal.

B and C, Contrast-enhanced T1-weighted images in sagittal (400/20/2) (B) and axial (600/15/3) (C) planes show mild focal enhancement (arrows). These areas correspond to the myeloid elements of the tumor.

D, Sagittal fast spin-echo T2-weighted (4000/100/2) MR image shows increased signal within the compressed spinal cord (arrows). The bulk of the epidural lesion follows the signal of subcutaneous fat on this image, whereas the myeloid elements show intermediate signal intensity.

E, Photomicrograph of tissue specimen shows cellular hematopoietic tissue with adjacent mature adipose tissue (hematoxylin-eosin, original magnification $\times 100$).



gross appearance of extraadrenal myelolipomas, unlike that of extramedullary hematopoiesis tumors, reflects an admixture of fat and hematopoietic tissue; microscopically erythroid hyperplasia is uncommon whereas lymphoid aggregates may be prominent. Our patient's clinical history and physical examination, as well as the pathologic features of the excised mass, all favored extraadrenal myelolipoma.

The MR examination in this case included only fast spin-echo T2-weighted sequences and noncontrast and contrast-enhanced T1-weighted studies. Ideally, a fat-suppression sequence added to the postcontrast sequence would be helpful in better identifying enhancing regions within the fat.

The differential diagnosis for the MR findings of this lesion includes several entities that contain fat and soft-tissue elements. An extramed-

ullary hematopoiesis tumor may look identical to an extraadrenal myelolipoma, and has been reported to cause cord compression in the spinal canal (14). However, extramedullary hematopoiesis tumors should be characterized by the clinical and pathologic features mentioned above. A spinal angioliipoma may have an identical clinical presentation and location, but has been reported to be isointense to hyperintense on T1-weighted images and hyperintense on T2-weighted images, in addition to showing diffuse homogeneous enhancement (15, 16). Epidural lipomatosis may also be considered, but this lesion can be differentiated by the absence of areas of soft-tissue signal, which represent blood-forming tissue (17). MR imaging clearly defines the predominately fatty nature of this lesion and its extradural location within the spinal canal.

Although rare, extraadrenal myelolipoma

should be included in the differential diagnosis when a mixed fatty and soft-tissue lesion is identified on a spinal MR examination.

References

- Brietta L, Watkins D. Giant extra-adrenal myelolipoma. *Arch Pathol Lab Med* 1994;118:188-90
- Fowler M, Williams R, Alba J, Byrd C. Extra-adrenal myelolipomas compared with extramedullary hematopoietic tumors. *Am J Surg Pathol* 1982;6:363-374
- Massey G, Green J, Marsh W. Presacral myelolipoma. *Cancer* 1987;60:403-406
- Grignon D, Shkrum M, Smout M. Extra-adrenal myelolipoma. *Arch Pathol Lab Med* 1989;113:52-54
- Chan Y, Yu S, Chan Y, Yik Y. Presacral myelolipoma: case report with computed tomographic and angiographic findings. *Aust N Z J Surg* 1988;58:432-434
- Dusenberry D. Extra-adrenal myelolipoma: intraoperative cytodiagnosis on touch preparations. *Acta Cytol* 1990;34:89-91
- Evans G, Olinde H, Kozdereli E. Extra-adrenal myelolipoma: a lesion that can be diagnosed by fine needle aspiration biopsy. *Acta Cytol* 1990;34:536-538
- Hunter S, Schemankewitz E, Patterson C, Varma V. Extra-adrenal myelolipoma: a report of two cases. *Am J Clin Pathol* 1992;97:402-404
- Krag D, Reich S. Heterotopic bone marrow (myelolipoma) of the mediastinum. *Chest* 1972;61:514-515
- Kim K, Koo B, Davis J, Franci-Saenz R. Primary myelolipoma of the mediastinum. *J Comput Assist Tomogr* 1984; 8:119-123
- Prahlow J, Loggie B, Cappellari J, Scharling E, Iskandar S. Extra-adrenal myelolipoma: report of two cases. *South Med J* 1995;88:639-643
- Strimlan C, Khasnabis S. Primary mediastinal myelolipoma. *Clev Clin J Med* 1993;60:69-71
- Kader S, Kalisher L, Schiller A. Extramedullary hematopoiesis in Paget's disease of bone. *AJR Am J Roentgenol* 1977;129:493-495
- Lau SK, Chan CK, Chow YY. Cord compression due to extramedullary hematopoiesis in a patient with thalassemia. *Spine* 1994; 19:2467-2470
- Preul M, Leblanc R, Tampieri D. Spinal angioliipoma: report of three cases. *J Neurosurg* 1993;78:280-286
- Mascalchi M, Graziano A, Giancarlo D. Spinal epidural angioliipoma: MR findings. *AJNR Am J Neuroradiol* 1991;12:744-745
- Doppman J. Epidural lipomatosis. *Radiology* 1989;171:581-582