Are your MRI contrast agents cost-effective?
Learn more about generic Gadolinium-Based Contrast Agents.
FRESENIUS KABI
caring for life

AJNR

Brain MR in chronic fatigue syndrome.

A Greco, C Tannock, J Brostoff and D C Costa

AJNR Am J Neuroradiol 1997, 18 (7) 1265-1269
http://www.ajnr.org/content/18/7/1265

This information is current as of May 7, 2024.

Brain MR in Chronic Fatigue Syndrome

Alina Greco, Charles Tannock, Jonathan Brostoff, and Durval C. Costa

PURPOSE: To determine the prevalence of MR white matter abnormalities in patients with chronic fatigue syndrome (CFS). **METHODS:** Brain MR studies of 43 patients (29 women and 14 men, 22 to 78 years old) with a clinical diagnosis of CFS (n = 15), CFS with associated depression (n = 14), and CFS with associated other psychiatric disorders, namely, anxiety and somatization disorder (n = 14), were compared with brain MR studies in 43 age- and sex-matched control subjects. **RESULTS:** MR findings were abnormal in 13 (32%) of the patients in the study group (ages 34 to 78 years) and in 12 (28%) of the control subjects (ages 26 to 73 years). One patient with CFS had multiple areas of demyelination in the supratentorial periventricular white matter. Another patient with CFS and associated depression had a single focus of probable demyelination in the supratentorial periventricular white matter. In four patients with CFS (ages 34 to 48 years) MR abnormalities consisted of one or several punctate hyperintense foci in the corona radiata, centrum ovale, and frontal white matter. The remaining seven patients (ages 50 to 78 years) had fronto-parietal subcortical white matter foci of high T2 signal. The prevalence of white matter hyperintensities was not different between the patients and the control subjects. **CONCLUSIONS:** Our findings suggest that no MR pattern of white matter abnormalities is specific to CFS.

Index terms: Brain, magnetic resonance; Degenerative disease

AJNR Am J Neuroradiol 18:1265–1269, August 1997

Chronic fatigue syndrome (CFS), also known as myalgic encephalomyelitis, is characterized by cognitive difficulties and exercise-induced fatigue as well as symptoms of immunologic dysfunction (1). Although all ages can be affected, it tends to occur in young adults and is more frequent in women. There are no specific physical findings or laboratory data to support the diagnosis of CFS (2–5). Brain functional imaging techniques have been used in the assessment of clinically suspected CFS (6–9), and reports of magnetic resonance (MR) studies of the brain have also appeared in the literature (9–13). We performed a retrospective study to determine the prevalence of abnormal MR patterns in the brains of patients with CFS as compared with those of healthy control subjects.

Materials and Methods

Forty-three patients (29 women and 14 men, 22 to 78 years old) with clinically diagnosed CFS were enrolled in the study. A standardized diagnostic instrument (the structured clinical interview for DSM-III-R patient version) (14) was used to divide the patient population into three subgroups: the CFS group, which included 15 patients with CFS and neither past nor present diagnosis of psychiatric disorders; the CFS + D group, consisting of 14 patients with CFS and associated past or present diagnosis of depression; and the CFS + OD group, which comprised 14 patients with CFS and associated other past or present psychiatric disturbances, namely, anxiety and somatization disorder. Both inclusion and exclusion diagnostic criteria followed accepted standards (Oxford and Centers for Disease Control) (15, 16). Exclusion criteria were known neurologic disorders, certain recognized medications, detectable acute or chronic infections, autoimmune disease, cancer, thyroid dysfunction, diabetes mellitus, psychosis, and drug abuse.

Forty-three age- and sex-matched control subjects referred for MR assessment of clinically diagnosed benign

Received October 21, 1996; accepted after revision February 21, 1997.

Supported in part by the Action for ME and Chronic Fatigue.

From the MRI Department, Centre Hospitalier Princesse Grace, Principality of Monaco (A.G.); and the Departments of Psychiatry (C.T.) and Immunology (J.B.) and the Institute of Nuclear Medicine (D.C.C.), University College London (United Kingdom) Medical School.

Address reprint requests to Durval C. Costa, MD, Institute of Nuclear Medicine, University College London Medical School, Mortimer Street, London W1N 8AA, United Kingdom.

AJNR 18:1265–1269, Aug 1997 0195-6108/97/1807–1265
© American Society of Neuroradiology

Abnormal MR findings in patients with chronic fatigue syndrome (CFS)

Patient	Age, y/Sex	Clinical Diagnosis	MR Findings
1	34/F	CFS + OD	Subcortical frontal and right posterior parietal white matter punctate foci of high T2.
2	39/F	CFS	Subcortical and periventricular white matter hyperintense lesions. Right frontal lesion confluent around frontal horn of lateral ventricle.
3	39/F	CFS + D	Rounded focal area of hyperintensity in right periventricular white matter.
4	45/M	CFS + D	Left posterior corona radiata single hyperintense focus.
5	46/F	CFS	Right anterior external capsule punctate hyperintensity.
6	48/F	CFS	Multiple punctate foci of high T2 signal in parietal white matter and right centrum ovale.
7	50/M	CFS	Right frontal white matter multiple foci of high T2. Centrum ovale punctate hyperintense lesions.
8	51/M	CFS + OD	Left anterior external capsule hyperintense focus.
9	58/F	CFS + D	Frontal white matter punctate areas of high T2.
10	60/F	CFS + D	Centrum ovale punctate hyperintense lesions.
11	66/M	CFS + D	Frontoparietal white matter ischemic foci. Prominent ventricles and subarachnoid spaces.
12	69/F	CFS	Left parietal white matter punctate hyperintensities.
13	78/M	CFS	Frontoparietal white matter ischemic foci. Prominent ventricles and subarachnoid spaces.

Note.—OD indicates other past or present psychiatric disturbances, namely, anxiety and somatization disorder; D, associated past or present diagnosis of depression.

positional vertigo and with normal neurologic findings were also included in the study.

Sagittal and axial T1-weighted (640/14/1 [repetition time/echo time/excitations]) spin-echo MR images and axial proton density– (3000/15/1) and T2-weighted (3000/90/1) spin-echo images were obtained in all cases. A 1.0-T unit was used for the CFS group and a 1.5-T unit was used for the control group.

MR studies were analyzed by a reviewer who was blinded to psychiatric subclassification within the CFS group.

Results

Thirty of the 43 CFS patients had normal brain MR findings. In 13 patients (32%), ages 34 to 78 years, spin-echo T2-weighted images showed supratentorial white matter abnormalities (Table). The prevalence of MR abnormalities was age dependent. Seven (64%) of the 11 elderly CFS patients (age range, 50 to 78 years) had abnormal white matter signal, compared with only six (21%) of 32 younger CFS subjects (age range, 34 to 49 years). This difference in prevalence was statistically significant (χ^2 test = 7.819, P = .0052; Fisher's Exact Test, P = .0091).

Abnormal MR patterns consisted of punctate foci of increased T2 signal in the supratentorial white matter (corona radiata, centrum ovale, frontoparietal subcortical white matter, external capsule) in 11 patients. Of these, four were 34 to 48 years old and seven were 50 to 78 years old. In the former group, findings were nonspecific and consisted of one (two cases) or more (two cases) punctate foci of high T2 signal (Figs 1 and 2). In the latter group, the distribution and pattern of abnormalities were compatible with small-vessel disease, consistent with the aging process (Fig 3).

Two patients in the younger group had MR images that showed periventricular high signal intensity foci compatible with demyelination. In one 39-year-old woman the distribution and morphology of multiple lesions were highly consistent with demyelination (Fig 4), and in another 39-year-old woman, T2-weighted MR images showed a single lesion abutting the lateral ventricular wall, compatible with a single focus of demyelination (Fig 5).

The relative prevalence of white matter foci of increased T2 signal among the three subgroups was as follows: six (40%) of 15 in the CFS group, five (36%) of 14 in the CFS + D group, and two (14%) of 14 in the CFS + OD group. Owing to the small numbers, such differences in frequency were not statistically significant.

Thirty-one (72%) of the 43 control subjects had normal brain MR findings and 12 (28%) had abnormal findings. Of these, seven (21%) were among the 33 subjects between 26 and 49 years old and five (50%) were among the 10 subjects between 51 and 73 years old. In the former group, findings consisted of one (three cases) or more (four cases) foci of increased T2 signal in the subcortical frontoparietal white matter. In the latter group, the hyperintense foci involved either subcortical (three cases) or posterior parietal periventricular (one case) white matter. In one patient, both subcortical and posterior parietal periventricular white matter were involved. The number of hyperintense foci varied from two (one case) to several (four cases).

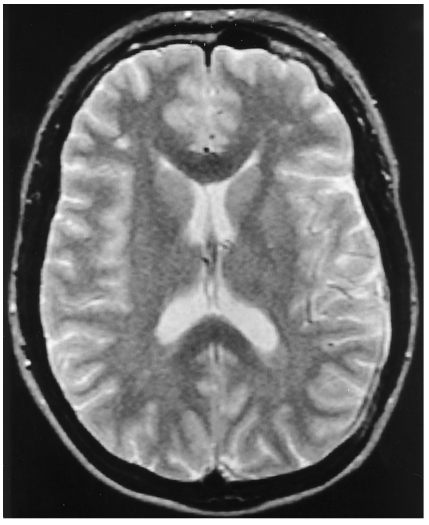

1

2

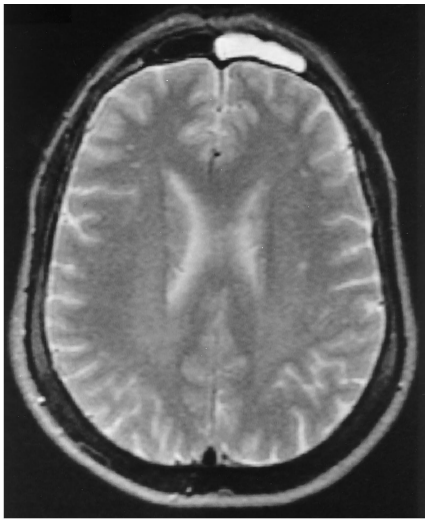

3

Fig 1. A 34-year-old woman with CFS + OD. Axial T2-weighted (3000/90) MR image shows punctate areas of increased T2 signal involving frontoparietal white matter bilaterally.

Fig 2. A 46-year-old woman with CFS. Axial T2-weighted (3000/90) MR image shows right-sided punctate focus of high T2 signal lateral to anterior external capsule.

Fig 3. A 60-year-old man with CFS + D. Axial T2-weighted (3000/90) MR image shows punctate hyperintense lesions in the centrum ovale.

4

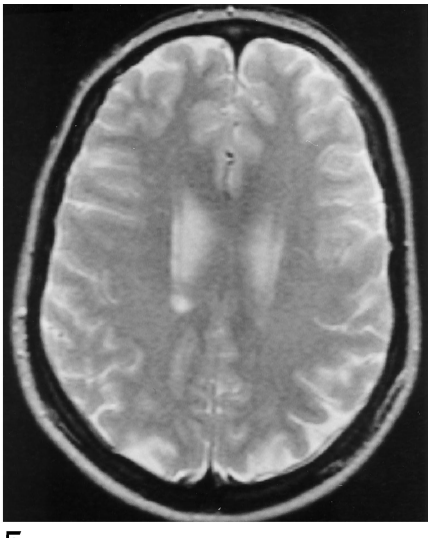

5

Fig 4. A 39-year-old woman with CFS. Axial T2-weighted (3000/90) MR image shows left-sided subcortical and deep white matter hyperintense lesions. Right frontal hyperintense lesion is confluent around the frontal horn of the right lateral ventricle.

Fig 5. A 39-year-old woman with CFS + D. Axial T2-weighted (3000/90) MR image through the roof of the lateral ventricles shows rounded focal area of increased T2 signal in the right periventricular white matter.

There were no significant differences in the prevalence of abnormal MR findings between the CFS group and the control group. However, there was a trend toward more abnormalities in the CFS subgroup of patients with no depression or associated other psychiatric disorders than in the control subjects (Fisher's Exact Test, $P = .06$).

No hypothalamic or brain stem structural lesions were found in the two populations studied, which contrasts with findings in an overlapping group investigated with single-photon emission computed tomography (8).

Discussion

The subjective and nonspecific clinical symptoms and the lack of definitive serologic and

immunologic findings make the diagnosis of CFS difficult. Both brain functional imaging (6–9) and brain MR imaging (9–13) have been used with the aim of detecting any abnormality that might be consistently correlated with the clinical findings. Daugherty et al (10) and Buchwald et al (11) reported an increased frequency (78%) of white matter lesions on MR studies of patients with CFS as compared with that of control subjects (21%). Those studies had some limitations, since the criteria for patient selection were not reported and 15% of the patients with presumed CFS had symptoms of organic central nervous system disease (paresis, ataxia, seizures), which are not generally present in CFS.

Natelson et al (12) compared the brain MR studies of 52 patients who fulfilled the CDC criteria for CFS with those of 52 control subjects matched for age and sex. Eight patients (15%) with CFS syndrome had abnormal white matter: seven had areas of increased T2 signal in the corona radiata and one had a single, small periventricular focus of high T2 signal. Only one (less than 2%) of the 52 control subjects had an abnormal MR study, showing a solitary pontine lesion.

Schwartz et al (9) used MR imaging to study 16 patients with clinically diagnosed CFS and 15 age- and sex-matched control subjects, and found a relatively increased frequency of focal white matter abnormalities (centrum ovale and subcortical and periventricular white matter) in the CFS group (50% versus 20%). However, the power of the study to detect differences between the two groups was small, and the difference did not reach significance.

Cope et al (13) compared patients with CFS, with and without coexisting depressive illness, with control subjects with and without depression. In the subgroup of CFS patients without depression (n = 13), the one abnormal MR study (8%) showed two deep white matter lesions. In the CFS patients with associated depression (n = 9), two studies (22%) showed deep white matter lesions. In the subgroup of control subjects with depression (n = 12), three MR studies showed deep white matter lesions (25%). In the control group without depression (n = 10), only one study (10%) showed a single white matter lesion. No statistically significant differences were found among the subgroups.

In our CFS group, the prevalence of white matter foci of increased T2 signal was higher than in the series of Natelson et al (12) and Cope et al (13) and lower than in the series of Schwartz et al (9) and Buchwald et al (11). Owing to the small numbers, any discrepancy in prevalence of white matter lesions found among the three CFS subgroups will require further studies with larger samples to be clarified. The prevalence of white matter abnormalities in our entire CFS group was not significantly higher than in the control group, but it reached trend level statistically in the subgroup of CFS patients without depression or other associated psychiatric disorders. The only way to eliminate a possible type II statistical error derived from the small sample size would be to conduct a significantly larger study.

We found no increased prevalence of white matter lesions in CFS patients under the age of 50 relative to that in control subjects. A review of the literature revealed that healthy persons have small focal white matter lesions that have no clinical significance and that reflect ischemic demyelination, varying degrees of myelin pallor, gliosis, and vacuolation (17–19).

Fazekas (18) studied 87 healthy volunteers and described white matter lesions in 11% of subjects aged 0 to 39 years, in 31% of subjects aged 40 to 49 years, in 47% of those aged 50 to 59 years, in 60% of those aged 60 to 69 years, and in 83% of those aged 70 years and over, consistent with our findings in the control group. In seven patients of our study group, MR findings were likely to be age related, reflecting a vasculopathy involving the small vessels of the white matter. Hendrie et al (20) identified such MR abnormalities in 59% of healthy subjects over the age of 63 years without risk factors or deficits in cognitive function, and in all subjects over the age of 75 years.

One area of concern in investigating fatigue syndromes is the possibility of a slow demyelinating process underlying some mistakenly diagnosed CFS cases (P. White, personal communication, 1994). In two patients of our series, MR appearances were suggestive of demyelination. Both refused further investigations and are being followed up. To date, no final diagnosis has been made. Natelson et al (12) also encountered two patients who had an initial diagnosis of CFS and an abnormal MR study, in whom symptoms suggestive of multiple sclerosis subsequently developed.

In conclusion, our study suggests that no MR

pattern of white matter abnormalities is specific to CFS.

Acknowledgments

We thank M. Hall-Craggs and B. K. Kendall and their team at the MR Unit, UCLH NHS Trust, London, United Kingdom.

References

1. Wessely S. The epidemiology of CFS. *Epidemiol Rev* 1995;17: 139–145
2. Lynch SP, Seth RV, Main J. Monospot and VP1 tests in chronic fatigue syndrome and major depression. *J Royal Soc Med* 1992; 85:537–540
3. Levine PH, Jacobson S, Pocinki AG, et al. Clinical, epidemiologic and virologic studies in four clusters of the chronic fatigue syndrome. *Arch Intern Med* 1992;152:1611–1616
4. Swanink CMA, Melchers WJG, Van der Meer JWM, et al. Enteroviruses and the CFS. *Clin Infect Dis* 1994;19:860–864
5. Clark MR, Katon W, Russo J, et al. Risk factors for symptom persistence in a 2½ year follow-up study. *Am J Med* 1995;98: 187–195
6. Ischise M, Salit IE, Abbey SE, et al. Assessment of regional cerebral perfusion by ^{99m}Tc-HMPAO SPECT in chronic fatigue syndrome. *Nucl Med Commun* 1992;13:767–772
7. Schwartz RB, Komaroff AL, Garada BM, et al. SPECT imaging of the brain: comparison of findings in patients with chronic fatigue syndrome, AIDS dementia complex, and major unipolar depression. *AJR Am J Roentgenol* 1994;162:943–951
8. Costa DC, Tannock C, Brostoff J. Brainstem perfusion is impaired in chronic fatigue syndrome. *QJM* 1995;88:767–773
9. Schwartz RB, Garada BM, Komaroff AL, et al. Detection of intracranial abnormalities in patients with chronic fatigue: comparison of MR imaging and SPECT. *AJR Am J Roentgenol* 1994;162:935–941
10. Daugherty SA, Henry BE, Peterson DL, et al. Chronic fatigue syndrome in northern Nevada. *Rev Infect Dis* 1991;13:39–44
11. Buchwald DS, Cheney PR, Petersos DL, et al. A chronic illness characterized by fatigue, neurologic and immunologic disorders and active herpes virus type 6 infection. *Ann Intern Med* 1992; 116:103–113
12. Natelson BH, Cohen JM, Brassloff, et al. A controlled study of brain magnetic resonance imaging in patients with the chronic fatigue syndrome. *J Neurol Sci* 1993;120:213–217
13. Cope H, Pernet A, Kendall B, et al. Cognitive functioning and magnetic resonance imaging in chronic fatigue syndrome. *Br J Psychiatry* 1995;167:86–94
14. Spitzer RL, Williams JBW. *Structured Clinical Interview for DSM-III-R Patient Version (SCID-P, 7/1/85)*. New York, NY: Biometrics Research Department, Psychiatric Institute; 1985
15. Sharpe MC, Archard LC, Banatvala JE, et al. A report: chronic fatigue syndrome: guidelines for research. *J Royal Soc Med* 1991; 84:118–121
16. Holmes GP, Kaplan JE, Grantz NM, et al. Chronic fatigue syndrome: a working case definition. *Ann Intern Med* 1988;108:378–379
17. Horikoshi T, Yagi S, Fukamachi A. Incidental high-intensity foci in white matter on T2-weighted magnetic resonance imaging. *Neuroradiology* 1993;35:151–155
18. Fazekas F. Magnetic resonance signal abnormalities in asymptomatic individuals: their incidental and functional correlates. *Eur Neurol* 1989;29:164–168
19. Wallace CJ, Sevick RJ. Multifocal white matter lesions. *Semin Ultrasound CT MR* 1996;17:251–264
20. Hendrie HC, Farlow MR, Austrom MG, et al. Foci of increased T2 signal intensity on brain MR scans of healthy elderly subjects. *AJNR Am J Neuroradiol* 1989;10:703–707