

Are your **MRI contrast agents** cost-effective?

Learn more about generic **Gadolinium-Based Contrast Agents**.



**FRESENIUS
KABI**

caring for life

AJNR

MR of the brain in Sjögren-Larsson syndrome.

F Van Mieghem, J W Van Goethem, P M Parizel, L van den Hauwe, P Cras, J De Meirleire and A M De Schepper

AJNR Am J Neuroradiol 1997, 18 (8) 1561-1563

<http://www.ajnr.org/content/18/8/1561>

This information is current as of April 19, 2024.

MR of the Brain in Sjögren-Larsson Syndrome

F. Van Mieghem, J. W. M. Van Goethem, P. M. Parizel, P. Cras, L. van den Hauwe, J. De Meirleire, and A. M. De Schepper

Summary: Cerebral MR was performed in three patients with Sjögren-Larsson syndrome. In each case, a 1.5-T system was used, and the patient was under general anesthesia. The MR findings included confluent hyperintense white matter lesions in the periventricular and deep white matter of the centrum semiovale, with sparing of the subcortical U fibers. The topography of the white matter abnormalities correlated well with the clinical signs and symptoms.

Index terms: Brain, magnetic resonance; Brain, metabolism; White matter, diseases

Sjögren-Larsson syndrome (SLS) is a rare autosomal recessive disorder characterized by congenital ichthyosis, spastic diplegia or tetraplegia, mental retardation, and speech disorder. The syndrome may be associated with anomalies of the eyes and teeth, and with abnormal thoracolumbar stature. The disease is caused by an inborn error of the fatty alcohol metabolism, with a deficiency of fatty alcohol (nicotinamide-adenine dinucleotide) oxidoreductase. Biochemically, alterations are seen in the dopaminergic system of the putamen, with reduced concentrations of dopamine and its catabolic metabolites (3-methoxytyramine and homovanillic acid) (1). We document the magnetic resonance (MR) imaging appearance of cerebral abnormalities in three patients with SLS, and review the literature.

Case Reports

Case 1

A 43-year-old woman with SLS had a long-standing history of generalized motor epilepsy, spastic diplegia, cognitive deterioration, and ichthyosis. Clinical signs and symptoms had been slowly progressive over many years, with worsening of clinical status over the 3 months before MR examination. The seizures were partially suppressed

with a combination of carbamazepine and valproate sodium. Neurologic examination revealed a very limited vocabulary and spastic diplegia. There was chorioretinal atrophy with central hyperpigmentation on fundoscopic examination.

MR imaging of the brain showed diffuse hyperintense lesions in the deep white matter of the centrum semiovale of both hemispheres on axial turbo spin-echo T2-weighted images (3500/90/2 [repetition time/echo time/excitations]). These lesions were symmetric in both hemispheres, with a periventricular distribution (Fig 1). The white matter lesions were confluent. Coronal turbo inversion-recovery images confirmed the hyperintensities in the deep white matter, and also revealed hyperintense lesions along the corticospinal tracts. Both the frontal and parietal lobes were involved, whereas the cerebellar hemispheres were normal. The subcortical white matter had normal signal intensity, indicating that the subcortical U fibers were spared. The lateral ventricles were markedly dilated (Fig 1). The signal intensities of the basal ganglia, thalamus, and putamen were normal.

Case 2

This 38-year-old man with SLS was the brother of the patient in case 1. He had severe mental retardation (intellectual age less than 4 years). Neurologic examination showed a marked reduction in manual coordination and fine motor movements, and a reduced strength in the hands and legs. He also had primary hearing loss. Electroencephalography showed a flattened, decelerated curve. The patient had been institutionalized for over 20 years with no significant change in his mental or physical condition.

Axial and coronal turbo spin-echo T2-weighted MR images and coronal turbo inversion-recovery images showed hyperintense lesions in the deep white matter (centrum semiovale and periventricular white matter) of both cerebral hemispheres, with sparing of the subcortical white matter. The hyperintense white matter lesions were confluent. The lateral ventricles were slightly dilated. The cerebellar hemispheres were not affected (Fig 2).

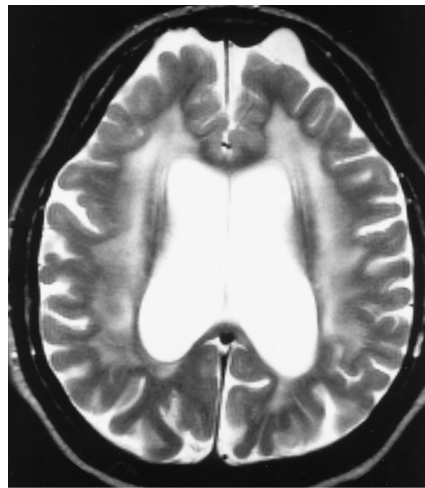
Received May 21, 1996; accepted after revision November 12.

From the Departments of Radiology (F.V.M., V.G., P.M.P., L.v.d.H., A.M.D.S.) and Neurology (P.P.C.), Universitair Ziekenhuis Antwerpen (University of Antwerp), Edegem; and Het Giels Bos, Foundation A. Kinsbergen Gehandicaptenzorg, Gierle (J.D.M.), Belgium.

Address reprint requests to J. W. M. Van Goethem, MD, Department of Radiology, Universitair Ziekenhuis Antwerpen, Wilrijkstraat 10, B-2650 Edegem, Belgium.

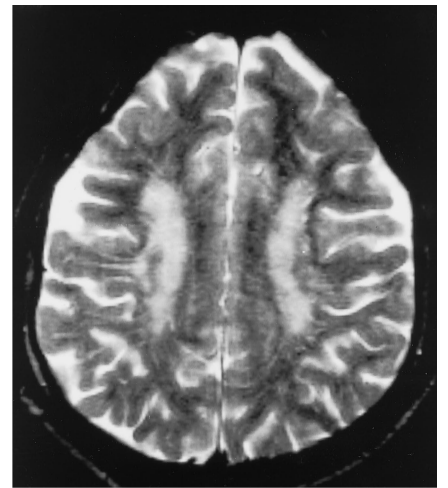
AJNR 18:1561-1563, Sep 1997 0195-6108/97/1808-1561 © American Society of Neuroradiology

Fig 1. Case 1: 43-year-old woman with SLS. Axial turbo spin-echo T2-weighted image (3500/90/2) of the brain through the upper portion of the lateral ventricles shows confluent hyperintense periventricular lesions in the white matter of both hemispheres. Note the normal signal intensity of the subcortical white matter. Both lateral ventricles are markedly dilated, with some widening of the cortical subarachnoid spaces.



1

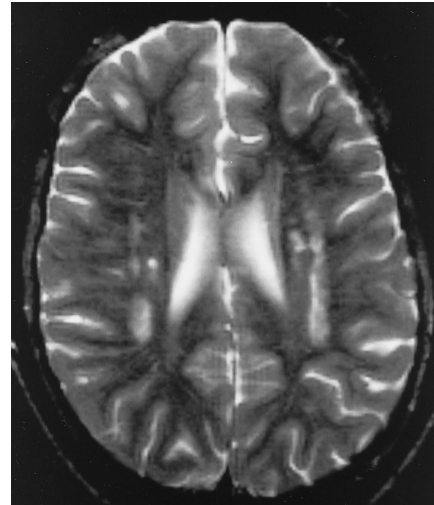
Fig 2. Case 2: 38-year-old man with SLS. Axial turbo spin-echo T2-weighted image (3500/90/2) through the centrum semiovale shows hyperintense lesions in the deep periventricular white matter in both hemispheres. The white matter lesions are confluent in appearance. Note the widening of the peripheral subarachnoid spaces, indicating mild cortical atrophy.



2

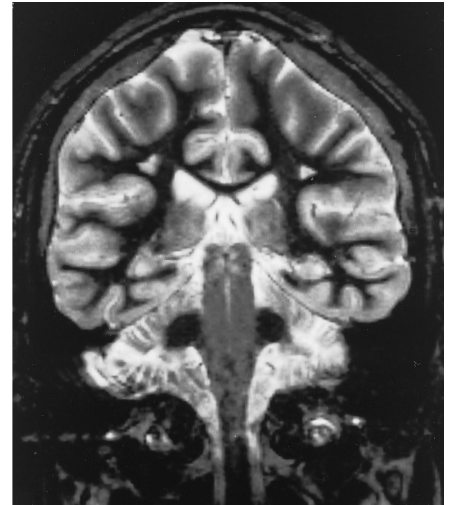
Fig 3. Case 3: 42-year-old man with SLS.

A, Axial turbo spin-echo T2-weighted image (3500/90/2) through the upper part of the lateral ventricles shows the white matter changes are rounded to oval in appearance, although confluent hyperintensities are also present. Both cerebral hemispheres are involved.



A

B, Coronal turbo inversion-recovery image (3600/19/2; inversion time, 150). The white matter lesions occur at a distance from the ventricles and are bilaterally symmetric. Sparing of the subcortical U fibers is clearly evident.



B

Case 3

Our third patient was a 42-year-old man with stigmata of SLS, including mental retardation, ichthyosis, and spastic diplegia. He had had epilepsy during childhood. He had a thoracolumbar torsion scoliosis to the right, flexion contracture of both the hip and the knee, and the feet had an equinovarus deformation. His intellectual level was that of a child of less than 2 years of age.

MR imaging of the brain, including axial and coronal turbo spin-echo T2-weighted images and turbo inversion-recovery images (3600/19/2; inversion time, 150) revealed hyperintense lesions of the deep white matter. These foci were round or oval, some sharply demarcated and others more confluent. Normal signal intensity was noted in the subcortical white matter of both hemispheres, and there was no dilatation of the lateral ventricles (Fig 3).

Discussion

In 1957 Sjögren and Larsson described a rare syndrome consisting of congenital ichthyosis associated with spastic diplegia or tetraplegia (spastic pyramidal symptoms), aphasia, and low-grade dementia (2). Since then, about 200 cases have been reported.

Neuropathologically, the hallmark of SLS is demyelination of the cerebral white matter and corticospinal and vestibulospinal tracts. There is a loss of neurons in the cortex and basal ganglia (substantia nigra and putamen) (3).

Neuroanatomically, Hussain et al (4) showed that the areas of abnormal signal intensity involve the cerebral white matter, which could

explain the low-grade dementia that is a consistent feature of SLS. It is believed that the conduction aphasia that is sometimes encountered in SLS is caused by the interruption of the arcuate fasciculus, connecting the temporal cortex to the frontal premotor cortex (4).

White matter abnormalities have been reported at computed tomography of the brain (5, 6). White matter lesions were found to vary from small periventricular hypodense regions to extensive and patchy areas of low density in the hemispheric white matter. No abnormal enhancement was noted after injection of intravenous contrast material (5, 6).

A few reports have addressed the MR imaging findings in SLS (4, 7, 8). These articles described diffuse white matter hyperintensities on T2-weighted images. The abnormal high signal intensity in SLS is noted especially in the periventricular white matter of the frontal lobes and at the level of the centrum semiovale and corpus callosum. Typically, the subcortical white matter (subcortical U fibers) is spared.

In our three cases, areas of high signal intensity on T2-weighted images were located in the deep white matter of both frontal and parietal lobes. The location of the corticospinal tracts in this region forms the anatomic basis for the spastic diplegia observed in our SLS patients. Sparing of the subcortical U fibers was found in all three cases. Additionally, we found marked dilatation of the lateral ventricles in one patient, possibly reflecting loss of periventricular white matter (case 1). In two patients (cases 1 and 2), white matter abnormalities were diffuse and confluent (Figs 1 and 2); in the third patient, the pattern of high signal intensity was more nodular, with round or oval hyperintense lesions (Fig 3).

In all three patients, the abnormalities associated with SLS consisted of changes in the white matter, including the centrum semiovale and deep white matter. Although the pattern of involvement differed individually, sparing of the subcortical U fibers was seen in all three cases. Therefore, we conclude that SLS should be included in the differential diagnosis of white matter disease, although the pattern of involvement is not pathognomonic (9–11).

References

1. Rizzo WB, Dammann AL, Craft DA, et al. Sjögren-Larsson syndrome: inherited defect in the fatty alcohol cycle. *J Pediatr* 1989; 115:228–234
2. Sjögren T, Larsson T. Oligophrenia in combination with congenital ichthyosis and spastic disorders. *Acta Psychiatr Scand* 1957;32: 1–108
3. Wester P, Bergstrom U, Brun A, Jagell S, Karlsson B, Eriksson A. Monoaminergic dysfunction in Sjögren-Larsson syndrome. *Mol Chem Neuropathol* 1991;15:13–28
4. Hussain MZ, Aihara M, Oba H, et al. MRI of white matter changes in the Sjögren-Larsson syndrome. *Neuroradiology* 1995;37:576–577
5. Gomori JM, Leibovici M, Zlotogorski A, Wirguin I, Hahem-Zadey S. Computed tomography in Sjögren-Larsson syndrome. *Neuroradiology* 1987;29:557–559
6. Mulder LJMM, Oranje AP, Loonen MCB. Cranial CT in the Sjögren-Larsson syndrome. *Neuroradiology* 1987;29:560–561
7. Morishita S, Konagaya M, Konayaga K, Takayanagai T. MRI study of three siblings of suspicious Sjögren-Larsson syndrome. *Rinsho Shinkeigaku* 1990;30:1118–1122
8. Di Rocco M, Filocamo M, Tottori-Donati P, Veneselli E, Borrone C, Rizzo WB. Sjögren-Larsson syndrome: nuclear resonance imaging of the brain in a 4-year-old boy. *J Inher Metab Dis* 1994;17:112–114
9. Osborn AG. Inherited metabolic, white matter, and degenerative diseases of the brain. In: *Diagnostic Radiology*. St Louis, Mo: Mosby; 1194:716–782
10. Edwards-Brown MK, Bonnin JM. White matter diseases. In: Atlas SW, ed, *Magnetic Resonance Imaging of the Brain and Spine*. 2nd ed. Philadelphia, Pa: Lippincott-Raven; 1996:649–706
11. Valk J, van der Knaap MS. *Magnetic Resonance of Myelin, Myelination, and Myelin Disorders*. Heidelberg, Germany: Springer; 1989:149–172