

Are your **MRI contrast agents** cost-effective?

Learn more about generic **Gadolinium-Based Contrast Agents**.



**FRESENIUS
KABI**

caring for life

AJNR

MR enhancement of the internal auditory canal induced by tissue implant after resection of acoustic neurinoma.

P Kremer, M Forsting, J Hamer and K Sartor

AJNR Am J Neuroradiol 1998, 19 (1) 115-118

<http://www.ajnr.org/content/19/1/115>

This information is current as of May 4, 2024.

MR Enhancement of the Internal Auditory Canal Induced by Tissue Implant after Resection of Acoustic Neurinoma

Paul Kremer, Michael Forsting, Jürgen Hamer, and Klaus Sartor

PURPOSE: We studied intrameatal changes in MR enhancement induced by free-tissue implant over time after surgery for acoustic neurinoma.

METHODS: Twenty-one patients were examined by MR imaging after suboccipital resection of an acoustic neurinoma. Precontrast and postcontrast MR images were obtained within 3 days after surgery (early MR images), then 6 weeks (intermediate MR images) and 6 months (late MR images) after surgery. A muscle graft as a free-tissue implant was used within the internal auditory canal in 18 of the 21 patients to seal pneumatic cells of the petrosal bone inadvertently opened and to prevent leakage of cerebrospinal fluid.

RESULTS: On the early MR images, only minimal leptomeningeal or perineural enhancement was seen in 16 patients. There was no sign of residual tumor; however, enhancement increased and changed from linear to nodular on the intermediate MR images in 16 of the 18 cases in which a muscle graft had been used during surgery, mimicking a small intrameatal tumor. This nodular enhancement was still visible on the late MR images in 13 of the 16 cases.

CONCLUSION: Nodular MR enhancement within the internal auditory canal a few weeks to months after surgery for acoustic neurinoma may be induced by packing material and should be considered when interpreting postoperative MR images.

Microsurgical resection via the suboccipital approach is an established neurosurgical treatment for acoustic neurinoma (1-4). Complete tumor removal and preservation of facial and cochlear nerve function require a high degree of surgical accuracy (5-8). Thus, in most cases, the posterior wall of the internal auditory canal (IAC) has to be drilled away to expose the lateral end of the tumor. Although this approach results in a good microsurgical view, cerebrospinal fluid may leak from opened air cells inside the IAC or from mastoid cells opened at the site of suboccipital craniectomy (3, 9, 10). To avoid this postoperative complication, air cells opened within the IAC can be closed by various techniques: bone wax, dural reflection, fibrin glue, or free-tissue implants, such as muscle or fat grafts. Mastoid cells opened at the craniectomy site are usually filled with bone wax or bone dust.

After surgery, computed tomography (CT) is per-

formed routinely to exclude complications, such as bleeding, swelling, or hydrocephalus. Magnetic resonance (MR) imaging has become well established in recent years as the best method for ascertaining the presence of tumor, not only before but also after surgery to assess for residual tumor or tumor recurrence. While the interpretation of the preoperative MR images of acoustic neurinomas is relatively straightforward (11-13), that of postoperative images presents some problems and has been the focus of recent studies (14-17). Enhancement of intrameatal structures after surgery, caused by scar tissue or tissue implants, and enhancement of residual intrameatal dura or any remaining intrameatal nerves make interpretation difficult, as was recently demonstrated in an animal study (18).

With regard to the various well-known MR enhancing patterns at the postoperative cranial site (19-21), early postoperative MR imaging seems to be an ideal tool for determining the presence of residual tumor (22). We therefore obtained the first MR images within 3 days after surgery as a baseline examination by which to gauge changes in MR enhancement over time, especially when tissue was implanted during surgery.

Methods

Twenty-one patients (12 women and nine men, 21 to 67 years old; average age, 54 years) each had three MR examina-

Received December 16, 1996; accepted after revision May 13, 1997.

From the Departments of Neurosurgery (P.K., J.H.) and Neuroradiology (M.F., K.S.), University of Heidelberg (Germany) Medical School.

Address reprint requests to Paul Kremer, MD, Department of Neurosurgery, Kopfklinikum, University of Heidelberg Medical School, Im Neuenheimer Feld 400, D-69120 Heidelberg, Germany.

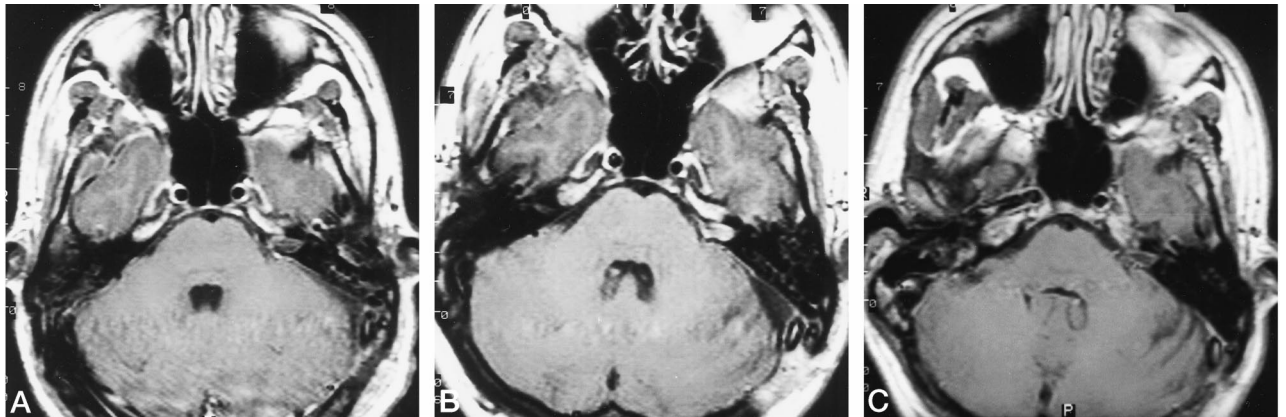


FIG 1. Contrast-enhanced axial T1-weighted MR images after resection of a small acoustic neuroma show changes in surgically induced enhancing patterns at different imaging times.

- A, Early image obtained within 3 days after surgery shows only minimal linear enhancement within the IAC.
 B, Intermediate image obtained 6 weeks after surgery shows nodular enhancement induced by tissue implant within the IAC, mimicking residual or recurrent tumor.
 C, Linear enhancement on late study 6 months after surgery shows nearly complete resorption of the free-tissue implant.

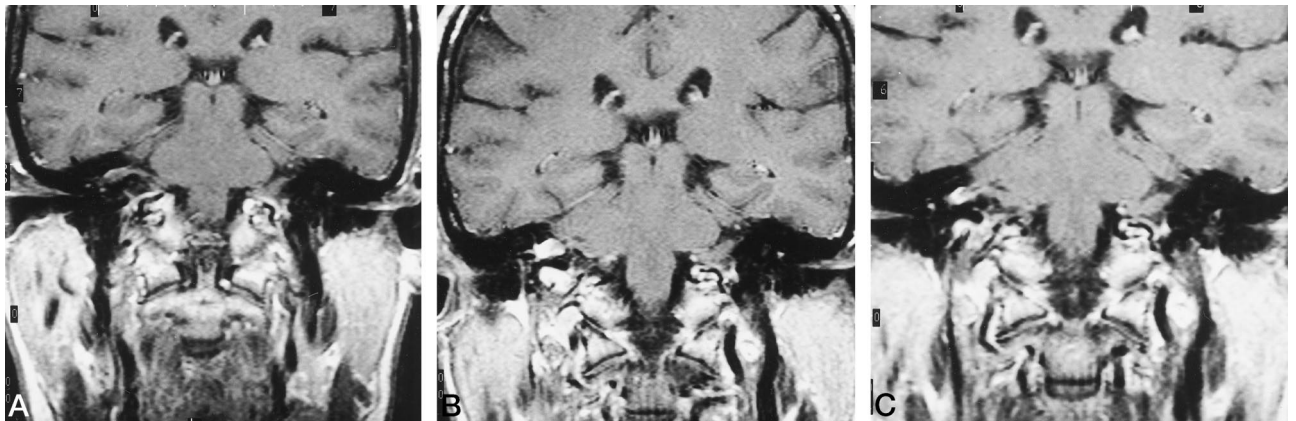

FIG 2. Contrast-enhanced coronal T1-weighted MR images after resection of an acoustic neuroma show changes in enhancement at the postoperative site.

- A, Linear enhancement is seen on early study obtained within 3 days after surgery.
 B, Change from linear to nodular enhancement is seen on intermediate examination 6 weeks after the operation. This enhancement, induced by tissue implant, mimics in appearance a small intrameatal tumor.
 C, Diminished nodular enhancement is seen on the late study 6 months after surgery.

tions (at 1.0 T or, after July 1995, at 1.5 T) after surgery for acoustic neuroma. T1-weighted images (540/20/2 [repetition time/echo time/excitations]) of the IAC were obtained with 3.5-mm-thick sections and no intersection gap before and after intravenous administration of contrast material (0.1 mmol/kg body weight) in axial and coronal planes within 3 days after surgery (early MR images), then 6 weeks after surgery (intermediate MR images) and again at least 6 months after surgery (late MR images).

In all patients, an acoustic neuroma was completely removed by microsurgical technique via the suboccipital approach, and the posterior wall of the IAC was removed with the use of a diamond drill. In 18 patients, a small muscle graft fixed by fibrin glue was applied to the IAC to seal opened pneumatic cells of the petrosal bone. All tumors were histologically identified as schwannomas of the vestibulocochlear nerve.

Tumor was intrameatal in five cases (Koos I), up to 2 cm in diameter with extrameatal extension in six cases (Koos II), up to 3 cm in diameter with initial contact with the brain stem in seven cases (Koos III), and more than 3 cm in diameter in three cases (Koos IV).

Results

Within the first 3 days after surgery, no residual tumor was visible on early MR images in any case. Some linear enhancement within the IAC was seen in 16 patients, originating from residual dural structures or from the distorted facial or cochlear nerves (Figs 1A and 2A).

On the intermediate MR images, obtained 6 weeks after surgery, enhancement increased and became nodular within the IAC in 16 of the 18 patients in whom muscle graft and fibrin glue had been used as free-tissue implant, and mimicked in appearance a small intrameatal tumor (Figs 1B and 2B). However, such nodular enhancement within the IAC was not visible in three other patients in whom no tissue implant was applied intraoperatively.

On the late MR images, obtained 6 months after surgery, nodular enhancement still remained in 13 of

the 18 patients in whom tissue had been implanted intraoperatively (Figs 1C and 2C). In 10 of these 13 patients, nodular enhancement of the IAC was diminished relative to that on the intermediate images. In three patients, enhancement of the IAC was unchanged, and in three patients nodular enhancement of the IAC was reduced to a linear aspect. In no case did enhancement within the IAC increase between the intermediate and late studies. Only one patient had neither linear nor nodular enhancement within the IAC 6 months after surgery.

Facial nerve function was preserved in 17 patients (four with Koos I tumors, six with Koos II tumors, six with Koos III tumors, and one with Koos IV tumor). In four patients (two with Koos III tumors and two with Koos IV tumors), facial nerve anastomosis to the superior radix of the cervical ansa was performed, with good clinical outcome in two cases. In eight patients with sufficient speech discrimination preoperatively (two with Koos I tumors, four with Koos II tumors, and two with Koos III tumors), speech discrimination could be preserved in four (one with Koos I tumor, two with Koos II tumors, and one with Koos III tumor). In no case was there leakage of cerebrospinal fluid.

Discussion

In recent years, MR imaging has played an important role in the diagnosis of acoustic neurinomas, largely replacing CT in this regard (11–13). Acoustic neurinomas, even small tumors, can be clearly characterized as to site, extension, and relationship to the IAC or brain stem with much greater accuracy than possible with CT. Radiologic examinations after neurosurgical procedures are usually performed with CT to exclude postoperative complications. Increasingly, MR imaging is then performed, typically weeks or months later, to assess for residual tumor or tumor recurrence.

Characteristic findings of acoustic neurinoma on preoperative MR images have been described by many authors and are well established. It is more difficult to interpret images of acoustic neurinoma after surgery, owing to changes in enhancement within the IAC and to the use of packing material, as demonstrated in recent studies (14–18, 23). Because these MR studies were performed months or years after surgery, enhancement within the IAC could not clearly distinguish residual tumor from tumor recurrence or from surgically induced nonneoplastic enhancement (19–21). Therefore, we designed a prospective study using an early postoperative MR study as a baseline examination, since, at this time, surgically induced enhancement is still limited to meningeal structures, and nodular enhancement strongly suggests residual tumor (22).

In addition to hearing loss and facial nerve palsy, complications of acoustic neurinoma surgery may include the development of a cerebrospinal fluid fistula (9, 10). The fistula may arise as a result of the opening of mastoid cells during suboccipital craniectomy that

are usually closed by bone wax or bone dust, or by cerebrospinal fluid, which may leak from the opening up of pneumatic cells when the posterior wall of the IAC is enlarged by diamond drills. In general, the frequency of this complication ranges from 4% to 27%. Various techniques have been described to occlude these opened cells inside the IAC, including using bone wax, reflecting dura, and implanting fibrin glue or free tissue, such as muscle or fat grafts (3, 9, 10). We used a small muscle graft fixed with fibrin glue as a tissue implant, and did not encounter leakage of cerebrospinal fluid in any patient.

In the early MR images after surgery, only minimal linear enhancement was seen, corresponding to the residual dural structures and the distorted nerves inside the IAC, thus indicating that residual tumor was improbable. At this stage, the muscle graft did not show any enhancement. Six weeks after surgery, enhancement increased (presumably as a result of revascularization of the graft in 16 of the 18 patients) and became nodular, mimicking in appearance a small intrameatal tumor. This nodular enhancement was still present in 13 of 18 patients 6 months after surgery, although to a lesser extent in most cases.

We have no histologic proof that enhancing intrameatal tissue 6 weeks or 6 months after surgery is scar tissue, but we suggest that because of the slow growth of acoustic neurinomas the sudden appearance of nodularity would be extremely unlikely to represent recurrent tumor (24). Moreover, no increase in intrameatal enhancement was noted between 6 weeks and 6 months after surgery. The graft used for air cell obliteration usually undergoes scarring or resorption. Enhancement requires revascularization of the graft. Since on early MR images, the muscle graft showed no enhancement, nodular enhancement 6 weeks or 6 months after the operation most likely represents organization of tissue implant and scar tissue.

In general, nodular enhancement in the postoperative state is more likely to represent residual or recurrent tumor, but it also may be induced surgically, particularly after implantation of a muscle graft. In our prospective study, we focused on these tissue implant-induced changes in MR enhancement within the IAC over time after removal of acoustic neurinomas, and demonstrated that an intrameatally placed muscle graft can mimic small residual or recurrent tumor weeks or months after surgery.

In regard to follow-up studies after resection of a malignant glioma, nodular enhancement detected on early MR images differentiates residual tumor from surgically induced enhancement (22). To verify the complete removal of tumor after resection of an acoustic neurinoma, an MR study should be conducted within the first 3 days postoperatively, when surgically induced enhancement is linear and is limited to leptomeningeal or perineural structures. Although an *early* postoperative MR study with no signs of nodular enhancement is not a guarantee against tumor recurrence, it does seem to be highly suitable

as a baseline observation for follow-up imaging examinations.

References

- Ebersold MJ, Harner SG, Beatty CW, Harper CM, Quast LM. **Current results of the retrosigmoid approach to acoustic neuroma.** *J Neurosurg* 1992;76:901-909
- Koos WT, Spetzler RF, Lang J. **Tumors of the cerebellopontine angle.** In: *Color Atlas of Microneurosurgery*. Stuttgart, Germany: Thieme; 1993:530-578
- Ojemann RG, Martuza RL. **Acoustic neuroma.** In: Youmans JR, ed. *Neurological Surgery*. Philadelphia, Pa: Saunders; 1996:2841-2861
- Whittaker CK, Luetje CM. **Vestibular schwannomas.** *J Neurosurg* 1992;76:897-900
- Fischer G, Fischer C, Rémond J. **Hearing preservation in acoustic neurinoma surgery.** *J Neurosurg* 1992;76:910-917
- Ojemann RG, Levine RA, Montgomery WM, McGaffigan P. **Use of intraoperative auditory evoked potentials to preserve hearing in unilateral acoustic neuroma removal.** *J Neurosurg* 1984;61:938-948
- Tatagiba M, Samii M, Matthies C, El Azm M, Schönmayr R. **The significance for postoperative hearing of preserving the labyrinth in acoustic neurinoma surgery.** *J Neurosurg* 1992;77:677-684
- Yokoh A, Kobayashi S, Tanaka Y, Gibo H, Sugita K. **Preservation of cochlear nerve function in acoustic neurinoma surgery.** *Acta Neurochir (Wien)* 1993;123:8-13
- Nutik SL, Korol HW. **Cerebrospinal fluid leak after acoustic neuroma surgery.** *Surg Neurol* 1995;43:553-557
- Symon L, Pell M. **Cerebrospinal fluid rhinorrhea following acoustic neurinoma surgery: technical note.** *J Neurosurg* 1991;74:152-153
- Curati WL, Graif M, Kingsley DPE, King T, Scholtz CL, Steiner RE. **MRI in acoustic neuroma: a review of 35 patients.** *Neuroradiology* 1986;28:208-214
- Press GA, Hesselink JR. **MR imaging of cerebellopontine angle and internal auditory canal lesions at 1.5 T.** *AJNR Am J Neuroradiol* 1988;9:241-251
- Valvassori GE, Morales FG, Palacios E, Dobben GE. **MR of the normal and abnormal internal auditory canal.** *AJNR Am J Neuroradiol* 1988;9:115-119
- Higgins JNP, Pigeon CN, Moseley IF. **Organising haematoma mimicking tumour on MRI following resection of acoustic neuroma.** *Neuroradiology* 1995;37:321-323
- Mueller DP, Gantz BJ, Dolan KD. **Gadolinium-enhanced MR of the postoperative internal auditory canal following acoustic neuroma resection via the middle fossa approach.** *AJNR Am J Neuroradiol* 1992;13:197-200
- Smith M, Castillo M, Campbell J, Pillsbury H, Walters T. **Baseline and follow-up MRI of the internal auditory canal after suboccipital resection of acoustic schwannoma: appearances and clinical correlations.** *Neuroradiology* 1995;37:317-320
- Weissman JL, Hirsch BE, Fukui MB, Rudy TE. **The evolving MR appearance of structures in the internal auditory canal after removal of an acoustic neuroma.** *AJNR Am J Neuroradiol* 1997;18:313-323
- Millen SJ, Daniels DL. **The effect of intracranial trauma on gadolinium-enhanced magnetic resonance imaging.** *Laryngoscope* 1994;104:804-813
- Burke JW, Podrasky AE, Bradley WG. **Meninges: benign postoperative enhancement on MR images.** *Radiology* 1990;174:99-102
- Elster AD, DiPersio DA. **Cranial postoperative site: assessment with contrast-enhanced MR imaging.** *Radiology* 1990;174:93-98
- Lanzieri CF, Larkins M, Mancall A, et al. **Cranial postoperative site: MR imaging appearance.** *AJNR Am J Neuroradiol* 1988;9:27-34
- Forsting M, Albert FK, Kunze S, Adams HP, Zenner D, Sartor K. **Radiologic follow-up after extirpation of glioblastoma: residual tumor and regrowth pattern.** *AJNR Am J Neuroradiol* 1993;14:77-87
- Thedinger BA, Glasscock ME III, Cueva RA, Jackson G. **Postoperative radiographic evaluation after acoustic neuroma and glomus jugulare tumour removal.** *Laryngoscope* 1992;102:261-266
- Valvassori GE, Guzman M. **Growth rate of acoustic neuromas.** *Am J Otol* 1989;10:173-176