

Are your **MRI contrast agents** cost-effective?

Learn more about generic **Gadolinium-Based Contrast Agents**.



**FRESENIUS
KABI**

caring for life

AJNR

Three-dimensional fast spin-echo MR of the inner ear: ultra-long echo train length and half-Fourier technique.

S Naganawa, T Itoh, H Fukatsu, T Ishigaki, T Nakashima, Y Kassai, M Miyazaki and H Takai

This information is current as of April 18, 2024.

AJNR Am J Neuroradiol 1998, 19 (4) 739-741
<http://www.ajnr.org/content/19/4/739>

Three-dimensional Fast Spin-Echo MR of the Inner Ear: Ultra-Long Echo Train Length and Half-Fourier Technique

S. Naganawa, T. Itoh, H. Fukatsu, T. Ishigaki, T. Nakashima, Y. Kassai, M. Miyazaki, and H. Takai

Summary: We compared the image quality of the newly developed ultra-long echo train length (ETL) 3-D fast spin-echo (FSE) and half-Fourier technique, which is performed in less than 3 minutes, with the conventional 3D-FSE imaging technique, which takes 15 minutes, in assessing MR examinations of the inner ear. The new method's images were almost comparable to the conventional 3D-FSE images in depicting anatomic details and pathologic findings. Implementation of the ultra-long ETL and half-Fourier 3D-FSE imaging technique enables acquisition of inner ear MR studies in a vastly reduced time and with high spatial resolution without significant penalty, opening the possibility for low-cost screening of acoustic tumors without contrast enhancement in less than 3 minutes.

The clinical utility of high-resolution heavily T2-weighted 3-D fast spin-echo (FSE) MR sequences for imaging the inner ear has been reported previously (1-3). Although the images obtained with conventional 3D-FSE (15 to 27 echo train length; ETL) are of high quality, the scan time is relatively long, typically around 15 minutes. In this study, an ultra-long ETL (148 ETL) and half-Fourier imaging technique was combined with 3D-FSE, and the results were compared with conventional 3D-FSE images in five volunteers and 30 patients with ear symptoms.

Methods

Ultra-long ETL 3D-FSE with half-Fourier imaging was performed on a 1.5-T MR Visart unit (Toshiba, Tokyo, Japan). All studies were acquired with a quadrature head coil. We compared the image quality obtained with the 148 ETL sequence with that of the conventional (27 ETL) protocol (1) while maintaining the same spatial resolution and number of excitations in five volunteers and 30 patients. The scan time was 15 minutes for the conventional 27 ETL sequence and 2 minutes 45 seconds for the 148 ETL sequence. To maintain the same T1 recovery time, TR was 3500 for the 27 ETL protocol and 5000 for the 148 ETL protocol. Other parameters included a field of view of 15 cm, TE of 250, matrix of $192 \times 256 \times 30$, thickness of 1.0 mm, and one excitation. Filling factors of k-space were 58% for the 148 ETL protocol and 100% for the 27 ETL protocol. The matrix size was zero-filled to $512 \times 512 \times 60$. The visibility of anatomic details in the five volunteers and the

appearance of pathologic findings in the 30 patients were compared for the two sequences.

Results

Images obtained using the 27 ETL (scan time, 15 minutes) and the 148 ETL (scan time, less than 3 minutes) sequences are presented in Figure 1. In the volunteers, the quality of the maximum-intensity projection (MIP) images of the inner ear are almost comparable. In all five volunteers, four nerves in the internal auditory canal, cochlea, vestibule, three semicircular canals, and ampulla are visible on each image. Both techniques produced excellent cisternographic effects. In the patients, the visibility of a small intracanalicular tumor (2-mm diameter) was comparable on each image (Fig 2), as was an intravestibular schwannoma (Fig 3). There was no difference in detecting abnormalities between the two techniques. Specific absorption ratio (SAR) of 148 ETL was 0.1 W/kg, which is within the guidelines established by the Food and Drug Administration.

Discussion

The clinical utility of high-resolution MR studies of the inner ear has been reported for 3-D gradient-echo sequences (4, 5), 2-D sequences (6), and 3D-FSE sequences (1-3). Gradient-echo imaging is susceptible to local field inhomogeneity and the 2D-FSE sequence is limited by the section thickness. Three-dimensional FSE solves these problems; however, it is limited by the scan time, typically around 15 minutes. Although wide coverage can be obtained using an interleaved multislab 3D-FSE approach in a given time (7), the signal-to-noise ratio per unit time is not improved for a specific voxel. Moreover, Venetian blind artifacts may be introduced between the slabs. To improve the signal-to-noise ratio and to reduce the scan time, a longer ETL is a must. However, a longer ETL has some drawbacks, such as blurriness, bright fat, and an increased SAR.

Received November 18, 1996; accepted after revision June 12, 1997.

From the Departments of Radiology (S.N., T.It., H.F., T.Is.) and Otolaryngology (T.N.), Nagoya University School of Medicine, Nagoya, Japan, and the Toshiba Corporation, Japan (Y.K., M.M., H.T.).

Address reprint requests to Shinji Naganawa, MD, Department of Radiology, Nagoya University School of Medicine, 65 Tsurumai, Showa-ku, Nagoya, 466 Japan.

FIG 1. MR images obtained using a 27 ETL sequence (15-minute scan time) (A) and a 148 ETL sequence (less than 3-minute scan time) (B). In both images, the anatomy of the labyrinth and internal auditory canal can be well appreciated. The quality of the MIP images of the inner ear are almost comparable (27 ETL, C; 148 ETL, D).

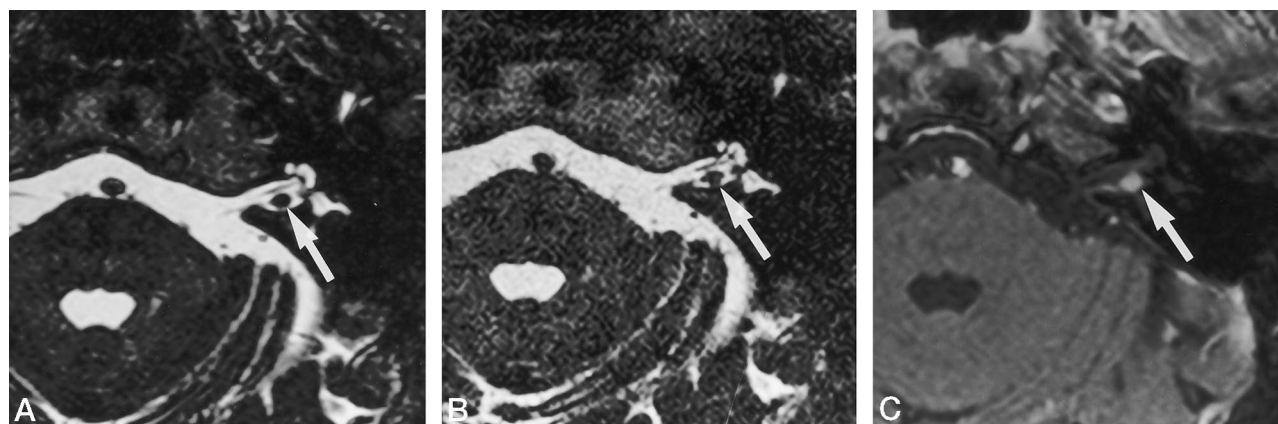
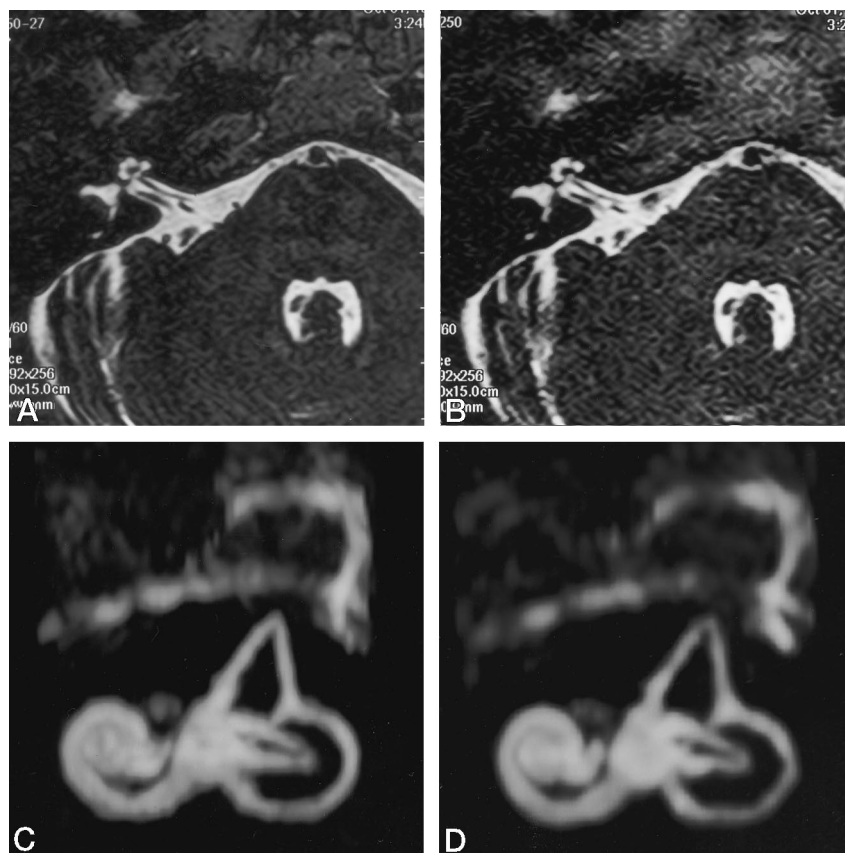
FIG 2. The visibility of a small intracanalicular (2-mm diameter) tumor (arrow) was also comparable with both imaging sequences (27 ETL, A; 148 ETL, B). Corresponding enhanced 3-D spoiled gradient-echo sequence (C) shows tumor originating from inferior vestibular nerve (arrow).

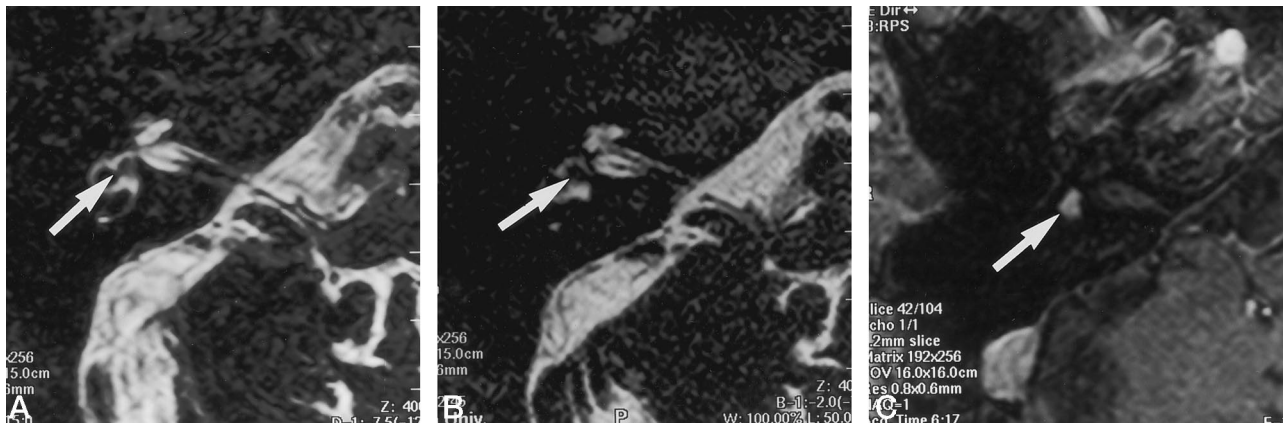


FIG 3. Intravestibular schwannoma (arrow) is seen equally well on 27 ETL sequence (A) and 148 ETL sequence (B). Corresponding enhanced 3-D spoiled gradient-echo sequence (C).

Conclusion

We conclude that images obtained with 148 ETL are acceptable for clinical examination of the inner ear. With this long ETL and half-Fourier imaging technique, the scan time can be reduced dramatically (ie, 3 minutes versus 15 minutes for the old protocol of 27 ETL). This saved time can be used to obtain higher spatial resolution or simply to reduce the patient's length of stay in the scanner. Moreover, this creates the possibility for screening acoustic tumors without contrast enhancement in less than 3 minutes.

References

1. Naganawa S, Yamakawa K, Fukatsu H, et al. **High resolution T2-weighted MR imaging of the inner ear using a long echo train length 3D fast spin echo sequence.** *Eur Radiol* 1996;6:369-374
2. Naganawa S, Yamakawa K, Fukatsu H, et al. **High resolution MR imaging of the inner ear apparatus using 3D-fast spin echo sequence.** *Nippon Acta Radiol* 1995;55:81-82
3. Naganawa S, Yamakawa K, Fukatsu H, et al. **Visualization of the internal anatomy of the inner ear using a long echo train length 3D fast spin echo sequence.** In: *Proceedings of the Third Meeting of the Society of Magnetic Resonance.* Society of Magnetic Resonance; 1995:230
4. Stillman AE, Remley K, Loes DJ, et al. **Steady-state free precession imaging of the inner ear.** *AJNR Am J Neuroradiol* 1994;15:348-350
5. Casselman JW, Kuhweide R, Deimling M, et al. **Constructive interference in steady state-3DFT MR imaging of the inner ear and cerebellopontine angle.** *AJNR Am J Neuroradiol* 1993;14:47-57
6. Phalps PD. **Fast spin echo in otology.** *J Laryngol Otol* 1994;108:383-394
7. Takehara Y, Ichijyo K, Tooyama N, et al. **Three-dimensional projection images of the labyrinth acquired with multislab 3DFT fast spin-echo sequence and dual-array surface coil.** *AJR Am J Roentgenol* 1995;165:645-646