

The **next generation** GBCA  
from Guerbet is here

Explore new possibilities >

Guerbet | 

© Guerbet 2024 GUOB220151-A

# AJNR

## **Lateral retropharyngeal node metastasis from carcinoma of the upper gingiva and maxillary sinus.**

Y Kimura, T Hanazawa, T Sano and T Okano

*AJNR Am J Neuroradiol* 1998, 19 (7) 1221-1224

<http://www.ajnr.org/content/19/7/1221>

This information is current as  
of September 26, 2024.

# Lateral Retropharyngeal Node Metastasis from Carcinoma of the Upper Gingiva and Maxillary Sinus

Yukinori Kimura, Tomomi Hanazawa, Tsukasa Sano, and Tomohiro Okano

**Summary:** Clinically unsuspected metastases to the lateral retropharyngeal nodes from carcinomas of the upper gingiva or maxillary sinus were found in five patients on follow-up CT examinations. Such uncommon metastases may follow the afferent lymphatic channels from the palate or pharyngeal region or arrive by retrograde lymphatics from positive neck nodes. Careful examination of lateral retropharyngeal nodes may be required in cancers of these primary sites.

The lateral retropharyngeal lymph nodes (of Rouviere) (1–5) are rarely involved by head and neck tumors (6–9). The highest rate of involvement of the lateral retropharyngeal lymph nodes occurs in nasopharyngeal and hypopharyngeal cancers (10–12). Metastases to the lateral retropharyngeal lymph nodes from carcinomas of the upper gingiva and maxillary sinus are considered rare, and little information about them is available in the literature. In the past several years, we encountered five patients with cancer of these sites in which CT scans showed involvement of the lateral retropharyngeal nodes. The purpose of this study was to analyze the clinical courses in these patients and to assess the possible routes of these uncommon metastases.

## Representative Case Reports

### Case 1

A 72-year-old woman underwent a partial maxillectomy on the right side and bilateral neck dissection for T2 squamous cell carcinoma of the upper gingiva. Seven years later a papillomatous lesion arising from the surgical margin of the buccal and palatal mucosa was found and diagnosed as well-differentiated squamous cell carcinoma (rT2). The buccal lesion was removed, the residual hard palate was partially resected, and the patient received 62 Gy of radiation to the residual tumor in the conserved palatal bone. Three months after treatment, she reported severe pain in the deep area of the left parotid gland. A CT study performed 5 months after surgery revealed a 28-mm lateral retropharyngeal lymph node with central necrosis on the left side (Fig 1). The patient died of massive bleeding in the involved area 2.5 months after CT diagnosis.

### Case 2

A 92-year-old man had painful swelling of the gingiva in the left upper premolar area. An incisional biopsy revealed well-differentiated squamous cell carcinoma (T2N0M0). Immediately after radiation therapy combined with chemotherapy, a CT study showed no tumor mass at the primary site, although a metastatic lymph node was detected in the contralateral submandibular region. The node was removed, followed by intraoral administration of an antineoplastic agent. Three and a half months after therapy, a CT examination showed not only recurrent nodal disease in the right upper neck region but also a 15-mm lateral retropharyngeal lymph node with central necrosis (Fig 2). Despite therapy with 50 Gy of radiation, the patient died after rapid growth of nodal disease 5 months after CT diagnosis.

### Case 3

A 51-year-old man had an ulceration of the gingiva in the left upper lateral incisor area. Incisional biopsy revealed well-differentiated squamous cell carcinoma (T1N0M0). A segmental resection confined to the anterior part of the upper alveolar ridge was performed. Two years after surgery, CT showed multiple lymph node metastases in the bilateral submandibular and right upper neck regions. Bilateral neck dissection combined with a subtotal maxillectomy was performed. Two courses of adjuvant chemotherapy followed. Eight months after the second operation, CT revealed a 15-mm lateral retropharyngeal lymph node on the right side with no evidence of recurrence of the primary lesion or the neck metastases (Fig 3A). Although one more course of adjuvant chemotherapy was added, CT revealed continuing enlargement of the right lateral retropharyngeal lymph node (Fig 3B). An abnormal retropharyngeal node was also seen on the left. Irradiation with 18 Gy to the nodes reduced the size, but the patient eventually died of liver metastasis 7.5 months after CT diagnosis, 2 months after CT diagnosis of bilateral retropharyngeal lymph nodes metastases.

### Case 4

A 66-year-old man had a swelling of the upper right gingiva of the molar area with an ulceration. CT revealed a tumor mass in the maxillary sinus with severe destruction of the alveolar processes, and submandibular lymph node enlargement on the right side. A diagnosis of moderately differentiated squamous cell carcinoma (T3N1M0) of the right maxillary sinus was made. After reduction of the tumor mass by means of preoperative radiotherapy with synchronous intraarterial chemother-

Received May 27, 1997; accepted after revision September 15.

From the Department of Radiology, Showa University Dental Hospital, 2–1–1, Kitasenzoku, Ohta-ku, Tokyo 145–8515, Japan. Address reprint requests to Dr. Yukinori Kimura.

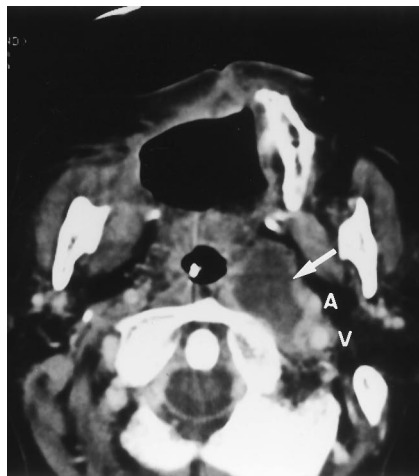


FIG 1. 72-year-old woman with squamous cell carcinoma of the upper gingiva (rT2N0M0). Contrast-enhanced axial CT scan shows a progressively enlarged low-attenuation nodal mass,  $28 \times 24$  mm, with a poorly defined rim, indicating lateral retropharyngeal node metastasis (arrow). The internal carotid artery (A) and jugular vein (V) were displaced laterally by the node.

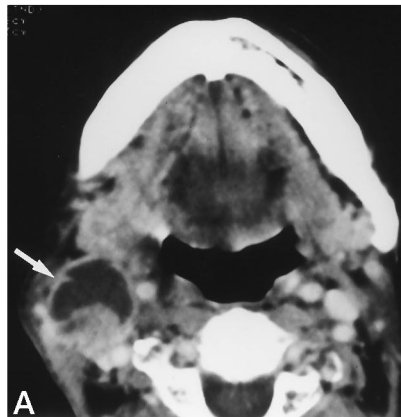
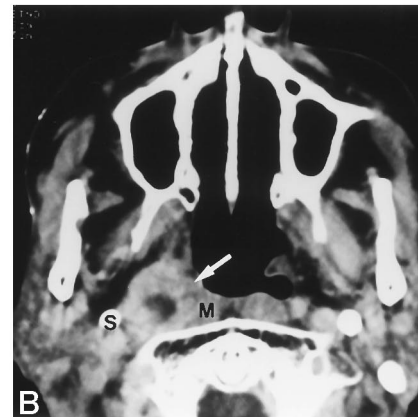


FIG 2. 92-year-old man with squamous cell carcinoma of the upper gingiva (T2N0M0). A, Contrast-enhanced axial CT scan shows recurrent tumor of the upper neck region on the right side (arrow).



B, CT scan shows an enlarged, round nodal mass with poorly defined borders and central low-attenuation between the styloid process (S) and longus colli muscle (M), indicating lateral retropharyngeal node metastasis (arrow).

apy, a partial maxillectomy combined with an upper neck dissection was performed on the right side. Nine months after surgery, CT revealed tumor recurrence on the right side of the neck, although no recurrence was seen at the primary site. In addition, a 10-mm lateral retropharyngeal lymph node with multilocular inner structure was detected on the same side (Fig 4A). The patient received 12.8 Gy of radiation followed by two courses of adjuvant chemotherapy. One month after therapy, CT revealed remission of the nodal swelling but also a 10-mm lateral retropharyngeal lymph node with multilocular inner structure on the left side, accompanied by multiple cervical lymph node metastases bilaterally (Fig 4B). The patient died of distant metastasis 2.5 months after CT diagnosis, 1.5 months after CT diagnosis of bilateral retropharyngeal lymph node metastases.

#### Case 5

A 59-year-old woman had swelling of the soft palate on the left side. CT showed a tumor involving the left maxillary sinus with bony erosion of the posterior wall. The lesion was diagnosed as well-differentiated mucoepidermoid carcinoma of the maxillary sinus (T3N0M0). A partial maxillectomy was performed and followed by chemotherapy. Seven and a half months after surgery, CT revealed tumor recurrence at the primary site. The patient was treated with 60 Gy of radiation therapy and synchronous chemotherapy. Thirteen months after surgery, CT revealed a recurrent tumor invading the nasopharyngeal wall and the ethmoidal sinus (Fig 5A). A 12-mm lateral retropharyngeal lymph node on the left side was also apparent (Fig 5B). After chemotherapy with one course, the diseased node was decreased in size; however, the recurrent tumor at the primary site extended into the middle cranial fossa. Despite chemotherapy, the patient died of local recurrence 5 months after the CT diagnosis.

#### Discussion

Involvement of lateral retropharyngeal lymph nodes by nasopharyngeal carcinoma is well-known to both head and neck cancer therapists and radiologists

(2–12). Carcinomas arising from the pharyngeal walls may metastasize to the lateral retropharyngeal nodes more often than carcinomas of any other primary site (10–12). Metastasis from carcinoma of the upper gingiva or maxillary sinus to the lateral retropharyngeal nodes is, however, considered rare, and little has been written about this type of metastasis in the literature.

Among the five cases described in this report, the primary tumor site was the upper gingiva in three cases and the maxillary sinus in two. Tumor invading both sites was seen only in one case. The distribution of tumor stages is given in the Table; no remarkable relationship was found between tumor stage and occurrence of metastasis. Among the neck tumors, three were stage N0 initially; however, one of those subsequently developed nodal metastasis. Two patients had recurrent tumors of the primary site, and three patients had aggressive neck metastasis. Thus, metastasis to the lateral retropharyngeal nodes was observed with relatively extensive recurrent tumors either at the primary site or in the deep neck area. Histopathologically, four tumors were classified as squamous cell carcinoma and the other as mucoepidermoid carcinoma; only one was moderately differentiated, the others were well-differentiated. There was no defined relationship between pathologic type or differentiation of the tumors and metastasis to the lateral retropharyngeal nodes, and there were no obvious histopathologic characteristics corresponding to development of metastasis to the nodes in our small series.

Four primary tumors were treated by surgery combined with radiotherapy and/or chemotherapy. One patient did not have surgery. This indicates that not only surgical intervention in the primary sites but also

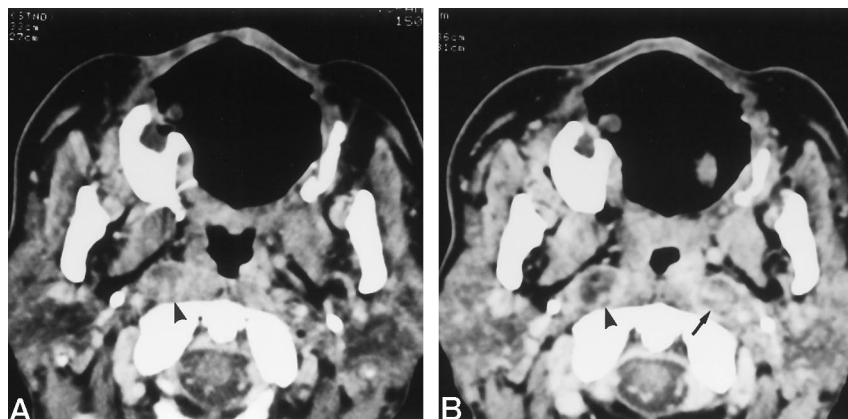


FIG 3. 51-year-old man with squamous cell carcinoma of the upper gingiva (T1N0M0).

A, CT scan shows an enlarged lateral retropharyngeal node measuring  $15 \times 12$  mm on the right side (arrowhead).

B, CT scan after further treatment shows lateral retropharyngeal nodes measuring  $18 \times 14$  mm on the right side (arrowhead) and  $16 \times 14$  mm on the left side (arrow).

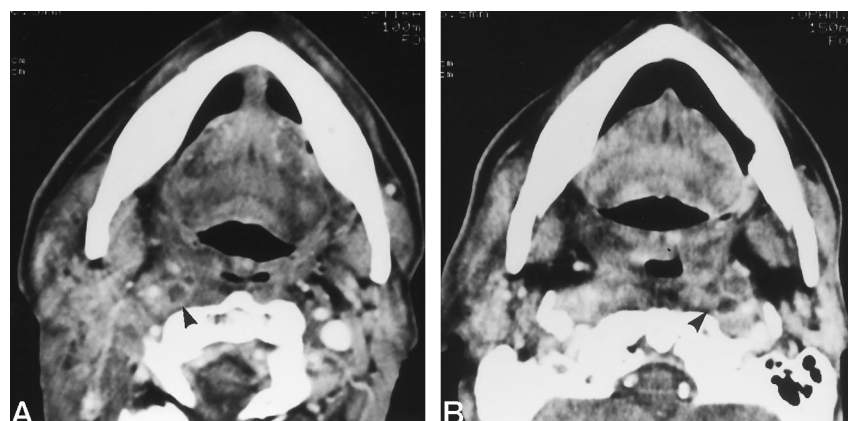


FIG 4. 66-year-old man with squamous cell carcinoma of the maxillary sinus (T3N1M0).

A, CT scan shows a  $10 \times 10$ -mm enlarged node with multilocular low-density areas (arrowhead) in the right retropharyngeal space.

B, CT scan shows a  $10 \times 8$ -mm enlarged lateral retropharyngeal node with multilocular low-density areas on the left side (arrowhead).

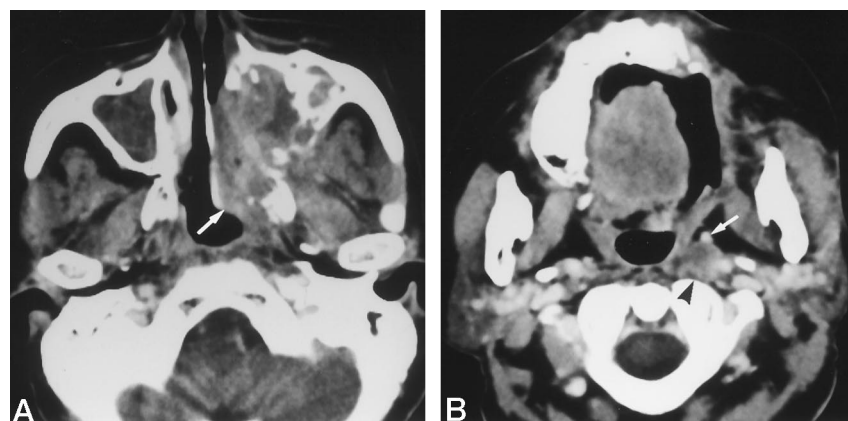


FIG 5. 59-year-old woman with mucoepidermoid carcinoma of the maxillary sinus (T3N0M0).

A, Contrast-enhanced axial CT scan shows recurrent tumor mass involving the nasopharyngeal region (arrow).

B, CT scan shows a  $12 \times 10$ -mm lateral retropharyngeal node, which may be metastatic because its diameter is more than 10 mm (arrowhead). The ascending pharyngeal artery (arrow) was displaced anteriorly.

conservative therapy may be associated with metastasis. On the other hand, four cases of nodal neck metastases were treated with radical neck dissection or lymphadenectomy. This raises a question as to whether surgical intervention to the neck region may affect the occurrence of metastasis.

The lateral retropharyngeal node metastases were found within 3.5 to 9 months after completion of neck treatment, as seen in the Table. In two cases, bilateral retropharyngeal nodes were involved, one ipsilateral and two contralateral to the primary site; in three cases, lateral retropharyngeal node metastases were observed on the same side as the nodal metastases to the deep neck. This suggests that retropharyngeal node metastases are frequently associated with metastases to other nodes.

An analysis of the routes of metastasis in carcinomas of the upper gingiva and maxillary sinus shows that the lymphatics of the upper gingiva, hard palate, and soft palate should be taken into consideration. The lymphatics of these areas may flow into the lateral retropharyngeal nodes via two different routes, according to the observations of Rouviere (1). One is an anterior route, which traverses the incisive canal and nasal fossa, runs posteriorly to anastomose with the lymphatics of the soft palate, and terminates in the lateral retropharyngeal nodes. The other is a posterior route, which passes the inner side of the dental arch, namely the hard palate, connects with the lymphatics of the soft palate, and terminates in the lateral retropharyngeal node. In addition, the collecting vessels of the upper gingiva are partly



Clinical characteristics and disease course in five patients with lateral retropharyngeal node (LRPN) metastasis

Case	Age (y)/Sex	Primary Site (TNM)	Initial Treatment (P/N)	Side of LRPN Metastasis (P/N)	Months to LRPN Metastasis after Treatment (P/N)	Months to Death after Diagnosis of LRPN Metastasis	Cause of Death
1	72/F	Gingiva (rT2N0M0)	(S) + S + RT/ (bilateral ND, 7 y ago)	Opposite /(-)	5/(-)	2.5	LRPN disease (bleeding)
2	92/M	Gingiva (T2N0M0)	RT + chemo/ lymphadenectomy	Opposite/same	4/3.5	5	LRPN disease (cachexia)
3	51/M	Gingiva (rT1N2cM0)	S + 2nd S + C/ bilateral ND	Both/same	8/8	7.5	Liver metastasis
4	66/M	Sinus (T3N1M0)	C + RT + S/upper ND	Both/same	9/9	2.5	Systemic distant metastases
5	59/F	Sinus (T3N0M0)	S + C/...	Same /...	13 /...	5	Primary tumor (intracranial invasion)

Note.—LRPN indicates lateral retropharyngeal node; P/N, to primary tumor/to cervical nodes; RT, radiation therapy; C, chemotherapy; S, surgery; ND, neck dissection.

crossed, as crossing posterior paths were reported in 50% of the hard and soft palates observed by Rouviere and his group (1) and thus may receive the lymphatics from the opposite side.

According to these anatomic observations, carcinomas of the upper gingiva and maxillary sinus in our series may have metastasized to the lateral retropharyngeal nodes. In case 1, tumor was found only in the residual hard palate, and it may have spread into the lateral retropharyngeal nodes of the contralateral side via crossing paths and a posterior route.

The lymphatic drainage of the lateral retropharyngeal node is as follows: each lateral retropharyngeal node gives off one or two large efferent trunks, which terminate in a lateral node of the internal jugular chain (1). Tumor may spread into the retropharyngeal node via the efferent trunks retrogradely if the direction of lymphatic flow is altered by a surgical procedure or obstructed by a neck tumor. In a recent article, it was pointed out that the retrograde lymphatics from deep neck metastases could be the cause of lateral retropharyngeal node metastasis in pharyngeal tumors (11). In our cases 2, 3, and 4, recurrence was not observed at the primary sites, but the nodal neck metastases were found on the same side as the lateral retropharyngeal node metastases. Thus, metastases to the node may have occurred by this mechanism in these cases. In case 5, there was no evidence of metastatic nodal neck disease except for a positive lateral retropharyngeal node. However, the recurrent tumor involved the superior part of the maxillary sinus, the ethmoidal sinus, and the anterolateral part of the nasopharynx. The afferent vessels of the lateral retropharyngeal node issue chiefly from the nasopharynx (1); thus, the node may have been involved via the afferent vessels of its own from these sites in this case only.

### Conclusion

Metastases to lateral retropharyngeal nodes may occur via an unusual lymphatic flow of the upper

gingiva to the node or by retrograde lymphatic flow caused by neck dissection or metastatic lymph nodes in the deep neck that obliterate the usual drainage pathway. Metastasis to a lateral retropharyngeal node may have a strong correlation with poor prognosis. Careful observation using sectional imaging may lead to detection of the lesion early in the follow-up period.

### References

1. Rouviere H. *Anatomy of the Human Lymphatic System*. English edition. Ann Arbor, MI: Edwards Brothers; 1938:16–18
2. Som PM, Bergeron RT. *Head and Neck Imaging*. 2nd ed. St Louis: Mosby-Year Book; 1991:419
3. Dillon WP, Miller EM. *Cervical soft tissue*. In: Newton TH, Hasso AN, Dillon WP, eds. *Computed Tomography of the Head and Neck*. New York: Raven Press; 1988:11.1–11.52
4. Som PM. *Lymph nodes of the neck*. *Radiology* 1987;165:593–600
5. Mancuso AA, Harnsberger HR, Muraki AS, Stevens MH. *Computed tomography of cervical and retropharyngeal lymph nodes: normal anatomy, variants of normal, and applications in staging head and neck cancer, I: normal anatomy*. *Radiology* 1983;148:709–714
6. Mancuso AA, Harnsberger HR, Muraki AS, Stevens MH. *Computed tomography of cervical and retropharyngeal lymph nodes: normal anatomy, variants of normal, and applications in staging head and neck cancer, II: pathology*. *Radiology* 1983;148:715–723
7. Mancuso AA. *Cervical lymph node metastasis: oncologic imaging and diagnosis*. *Int J Radiat Oncol Biol Phys* 1983;10:411–423
8. Mancuso AA, Hanafee WN. *Computed Tomography and Magnetic Resonance Imaging of the Head and Neck*. 2nd ed. Baltimore, MD: Williams & Wilkins; 1985:186
9. Davis WL, Harnsberger HL, Smoker WRK, Watanabe AS. *Retropharyngeal space: evaluation of normal anatomy and diseases with CT and MR imaging*. *Radiology* 1990;174:59–64
10. Ballantyne AJ. *Significance of retropharyngeal nodes in cancer of the head and neck*. *Am J Surg* 1964;108:500–504
11. McLaughlin MP, Mendenhall WM, Mancuso AA, et al. *Retropharyngeal adenopathy as a predictor of outcome in squamous cell carcinoma of the head and neck*. *Head Neck* 1995;17:190–198
12. Hasegawa Y, Matsuura H. *Retropharyngeal node dissection in cancer of the oropharynx and hypopharynx*. *Head Neck* 1994;16:173–180