This information is current as of October 12, 2024.

Technique for arterial-phase contrast-enhanced three-dimensional MR angiography of the carotid and vertebral arteries.

H Isoda, Y Takehara, S Isogai, H Takeda, M Kaneko, A Nozaki, Y Sun and T K Foo

AJNR Am J Neuroradiol 1998, 19 (7) 1241-1244
http://www.ajnr.org/content/19/7/1241

AJNR Am J Neuroradiol 19:1241–1244, August 1998

Technique for Arterial-Phase Contrast-Enhanced Three-Dimensional MR Angiography of the Carotid and Vertebral Arteries

Haruo Isoda, Yasuo Takehara, Satoshi Isogai, Hiroyasu Takeda, Masao Kaneko, Atsushi Nozaki, Yi Sun, and Thomas K. F. Foo

Summary: Our goal was to evaluate whether contrast-enhanced three-dimensional MR angiography using the MR Smartprep technique would enable us to obtain arterial-phase MR angiograms of the carotid and vertebral arteries. The study included 35 patients with suspected lesions of the neck in whom the MR Smartprep technique was used for MR angiography performed with a 1.5-T superconducting system. The tracker volume was placed primarily in the middle part of the right common carotid artery. The imaging volume was placed in a coronal direction to include the carotid and vertebral arteries from the aortic arch to the skull base. A centric phase-ordering scheme was used. Imaging times were 20 to 38 seconds for 14 patients and 11 to 16 seconds for 21 patients. By using a smaller tracker volume and an imaging time of less than 16 seconds, we were able to achieve a 100% successful triggering rate and to delineate selectively arterial-phase carotid and vertebral arteries with almost no venous contamination. Contract-enhanced 3-D MR angiography with the MR Smartprep technique was useful for showing arterial-phase carotid and vertebral arteries selectively.

Recent advances in contrast-enhanced MR angiographic techniques using a very short TR allow the acquisition of three-dimensional (3-D) volumes in less than 30 seconds (1–4). It is critical to capture the optimal imaging time after injection of a contrast bolus in order to acquire a good arterial-phase image, because the image contrast on a contrast-enhanced MR angiographic study is dependent on the concentration of contrast material in the blood at the time of the acquisition.

MR Smartprep (GE Medical Systems, Milwaukee, WI) is a new technique for detecting the bolus arrival by monitoring signal intensity from the tracking volume placed on the vessel of interest and automatically initiating acquisition of contrast-enhanced studies (5). Clinical application of this technique and its usefulness for 3-D MR angiography of the aorta have been reported (6).

Our goal was to evaluate whether contrast-enhanced 3-D MR angiography using the MR Smartprep technique would allow us to obtain arterial-phase MR angiograms of the carotid and vertebral arteries.

Methods

The MR Smartprep technique (5, 6) consists of a tracking sequence and an imaging sequence. The tracking volume can be placed over the vessel of interest independent of the imaging volume on a scout view (Fig 1). Upon initiation of the scan, the tracking sequence continuously monitors the MR signal from the vessel of interest (Fig 2). Once the signal in the tracking volume increases beyond a preset threshold (owing to the arrival of a bolus of contrast material) (Fig 2), the imaging acquisition is automatically triggered and the 3-D MR angiogram is acquired. By using a centric k-space view-ordering scheme in the phase-encoding direction (5), this technique is most sensitive to the maximum signal enhancement in the carotid and vertebral arteries produced by the first-pass bolus (7). We expected the MR Smartprep technique to reduce the overlapping of venous structures, thus enabling us to evaluate carotid and vertebral arteries more easily.

The subjects consisted of 12 patients in the initial phase of the study, 15 patients in the second phase, and eight patients in the latest phase. All 35 patients were thought to have neck lesions and were imaged in a supine position. A total of 20 mL of gadodiamide hydrate (Omniscan) was infused via the antecubital vein by hand at a rate of approximately 2 to 4 mL/s followed immediately by a 20- to 50-mL saline flush at 2 to 4 mL/s by a radiologist in the imaging room.

Imaging was performed using a 1.5-T superconducting MR system with a head and neck vascular coil or a body coil. After obtaining transaxial scout images, sagittal images were acquired along the vessels of interest. A tracker volume (20 × 4 × 4 cm) was placed in the proximal portion of the innominate artery or aortic arch in the initial phase of the trial and a tracker volume (2 × 2 × 2 cm to 4 × 2 × 2 cm) was placed in the middle part of the right common carotid artery in both the second and latest phases of the trial (Fig 1). To ensure that the tracking volume had maximum sensitivity to the

Received June 27, 1997; accepted after revision November 17.
Presented at the annual meeting of American Society of Neuroradiology, Toronto, Canada, May 1997.
From the Department of Radiology, Hamamatsu University School of Medicine, Hamamatsu, Japan (H.I., Y.T., S.I., H.T., M.K.); GE Yokogawa Medical Systems, Tokyo, Japan (A.N.); and GE Medical Systems, Milwaukee, WI (Y.S., T.K.F.F.).
Address reprint requests to Haruo Isoda, MD, Department of Radiology, Hamamatsu University School of Medicine, 3600 Handa-cho, Hamamatsu 431–3192 Japan.

© American Society of Neuroradiology

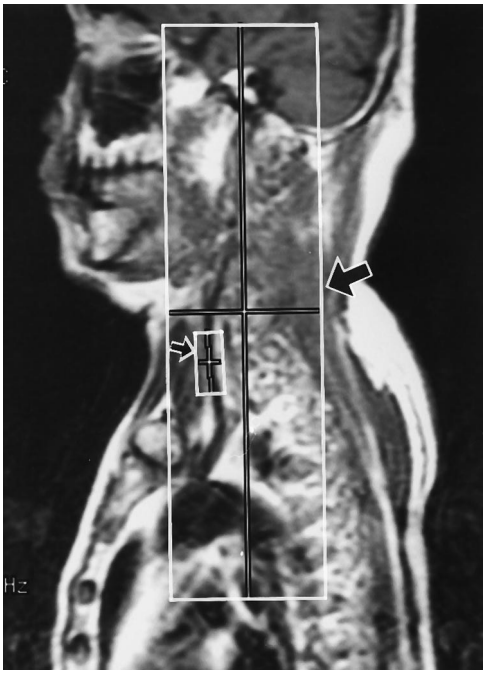

FIG 1. Illustration of the positioning of the tracking and imaging volumes on a sagittal scout image. The tracker volume (4 × 2 × 2 cm) is placed at the middle portion of the right common carotid artery (*small arrow*). The imaging volume is placed in a coronal direction and includes the carotid and vertebral arteries from the aortic arch to the skull base (*large arrow*).

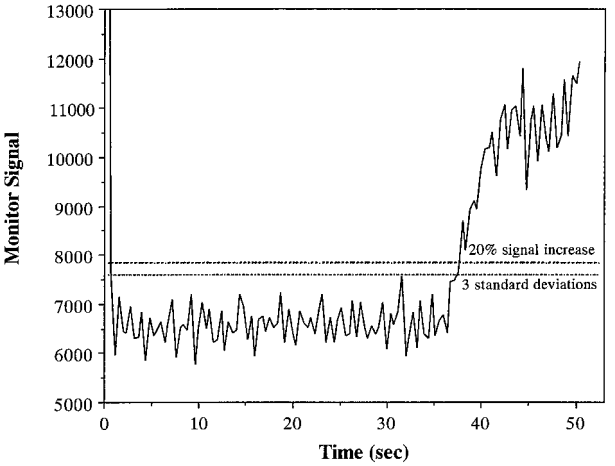

FIG 2. Representative signal intensity–time plot. Orthogonal section-selective gradients for the 90° and 180° radio-frequency pulses define a rectangular volume of interest. Only spins from within this volume were refocused with the 180° radio-frequency pulse and returned a spin echo. Although data can be generated for every tracking-sequence TR of 20 milliseconds, every 20 data points were averaged together for an effective tracking temporal resolution of 400 milliseconds per output point. The threshold levels of 3 SD from the mean and a 20% rise in signal intensity over the mean are shown. When a change in signal intensity (caused by arrival of contrast medium) beyond the threshold levels was detected, the intersequence process generator switched from the 20-millisecond spin-echo tracking sequence to the 3-D radio-frequency phase-spoiled gradient-echo imaging sequence.

passage of the contrast bolus, we needed to know the exact coordinates of the vessels of interest. The pulse sequence continuously monitored the MR signal from the volume of interest. Two thresholds were predetermined: one was set at 2 or 3 SD from the mean and the other at a 15% or 20% increase in signal intensity over baseline (Fig 2). The 3-D MR angiographic sequence was triggered when the signal in the tracking volume passed both thresholds.

On the sagittal scout view, the imaging volume was placed in a coronal direction to include the carotid and vertebral arteries from the aortic arch to the skull base (Fig 1). Three-dimensional spoiled gradient-echo imaging was performed with a 1-second delay after Smartprep triggered the arrival of the contrast bolus into the tracking region. In the initial phase of the trial, the imaging parameters were as follows: TR/TE/excitations, 6.2–7.4/1.4–1.5/1; flip angle, 40°; number of sections, 20 to 40; section thickness, 1.5 to 5.0 mm; field of view (FOV), 24 to 32 cm; bandwidth, 31.3 kHz; matrix, 256 × 128; imaging time, 16 to 38 seconds. The centric phase-ordering scheme was used, which is most sensitive to early image contrast enhancement produced by the arrival of the contrast bolus (7). In the second phase of the trial, zero-filled interpolation processing (ZIP) became available and was applied in the section direction to double the number of reconstructed partitions, and in the in-plane direction to increase the apparent spatial resolution (8). ZIP thus helped reduce the imaging time from 30 or 40 seconds to about 15 seconds while maintaining the effective number of sections. The imaging parameters in the second phase were as follows: TR/TE/excitations, 6.2–7.9/1.4–1.6/0.75–1; flip angle, 30°; number of sections, 18 to 32 (effective number of sections, 36 to 64); section thickness, 2.0 to 5.0 mm (effective section thickness, 1.0 to 2.5 mm); FOV, 19 × 9.5 cm to 32 × 32 cm; bandwidth, 31.3 kHz; matrix, 256 × 128; imaging time, 11 to 26 seconds. In the last phase of the trial, a spectrally selective inversion-recovery fat-suppression pulse also became available and was applied to suppress signal from the adipose tissue. However, imaging time increased somewhat, from 13 seconds to 16 seconds, owing to the time needed to apply the fat-suppression pulse. The imaging parameters were as follows: TR/TE/excitations, 6.2–7.9/1.4/0.75; flip angle, 30°; number of sections, 18 to 32 (effective number of sections, 36 to 62); section thickness, 4.0 to 6.0 mm (effective section thickness, 2.0 to 3.0 mm); FOV, 19 × 9.5 cm to 28 × 21 cm; bandwidth, 31.3 kHz; matrix, 256 × 128 to 256 × 160; imaging time, 13 to 20 seconds. Depending on the anatomic coverage required, the section thickness was increased when necessary to ensure that the imaging volume included the origin of the innominate artery, the left common carotid artery, the left subclavian artery from the aortic arch, and the vertebral arteries at the level of C1. Imaging times were 31 to 38 seconds for eight patients in the initial phase of the trial, 20 to 26 seconds for five patients (two patients in the initial phase, two in the second phase, and one in the latest phase), 15 to 16 seconds for nine patients (two in the initial phase and seven in the latest phase), and 11 to 13 seconds for 13 patients in the second phase.

MR angiograms were reconstructed with the maximum-intensity projection technique by rotating the viewing angle every 8° to 15° from the anteroposterior direction along the head-foot axis of the body.

Two experienced radiologists ascertained the success rate of the MR Smartprep technique in triggering MR angiography by evaluating all images to determine whether they selectively delineated arterial-phase carotid and vertebral arteries with almost no overlapping venous structures.

Results

MR angiography was triggered by the MR Smartprep technique in 11 (92%) of 12 patients in the initial phase with a tracker volume of 20 × 4 × 4 cm. The MR Smartprep succeeded in triggering angiography in all 23 patients (100%) in the second and

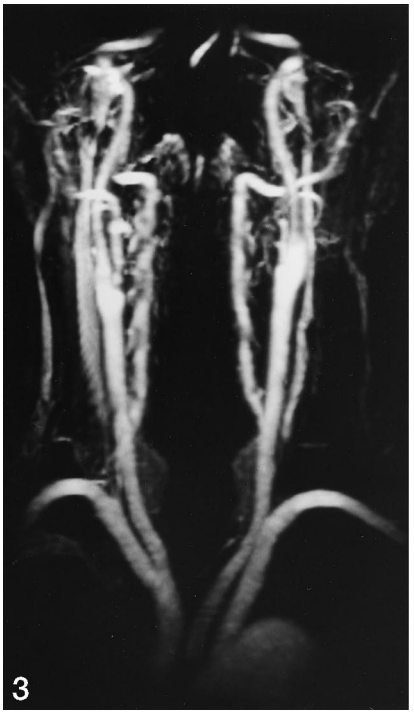

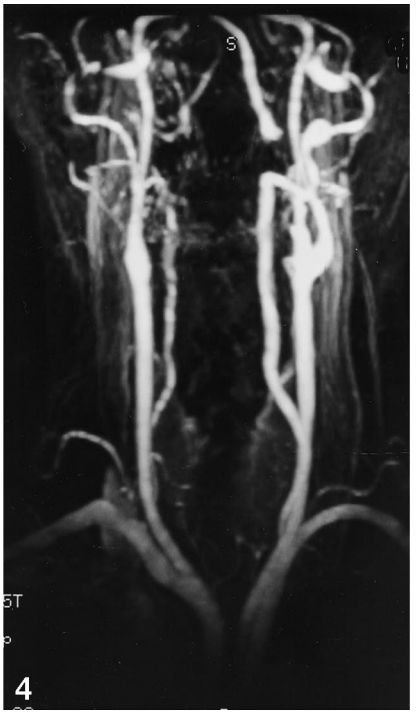

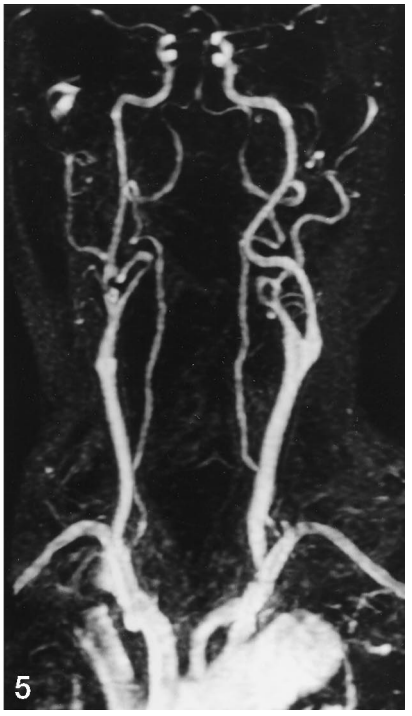

FIG 3. Contrast-enhanced 3-D MR angiogram obtained with the MR Smartprep technique. Parameters included TR/TE/excitations, 7.4/1.6/1; flip angle, 40°; number of sections, 40; section thickness, 1.5 mm; FOV, 24 × 24 cm; bandwidth, 31.3 kHz; matrix, 256 × 128; imaging time, 38 seconds; and a head and neck vascular coil. It is impossible to evaluate the arteries owing to excessive coincidental venous enhancement. Proximal parts of the innominate artery, the left common carotid artery, and the left subclavian artery are not clearly shown owing to weak sensitivity in this part of the head and neck vascular coil.

Fig 4. Contrast-enhanced 3-D MR angiogram obtained with the MR Smartprep technique. Parameters included TR/TE/excitations, 6.6/1.4/1; flip angle, 40°; number of sections, 40; section thickness, 2 mm; FOV, 26 × 26 cm; bandwidth, 31.3 kHz; matrix, 256 × 128; imaging time, 34 seconds; and a head and neck vascular coil. Although the MR angiogram shows apparent venous structures, the arteries have a stronger signal intensity than the veins and the arterial structures are fully visible.

Fig 5. Contrast-enhanced 3-D MR angiogram obtained with the MR Smartprep technique. Parameters include TR/TE/excitations, 6.2/1.4/0.75; flip angle, 30°; number of sections, 18 (effective number of sections, 36); section thickness, 5 mm (effective section thickness, 2.5 mm); FOV, 30 × 22 cm; bandwidth, 31.3 kHz; matrix, 256 × 128; imaging time, 11 seconds; ZIP; and a body coil. The contrast-enhanced 3-D MR angiogram with a shorter imaging time selectively delineates arterial-phase carotid and vertebral arteries with almost no overlapping venous structures. Note clear visibility of the proximal parts of the innominate artery, the left common carotid artery, and the left subclavian artery due to the use of the body coil (compare with Figs 3 and 4).

latest phases, using a tracker volume of 2 × 2 × 2 cm to 4 × 2 × 2 cm.

Regarding the evaluation of the MR angiograms by two observers, we found no significant difference in interobserver variability by Wilcoxon signed rank test; one patient in whom the trigger failed was excluded in this evaluation. The MR angiograms acquired in the initial phase with imaging times of 31 to 38 seconds selectively revealed arteries in 12.5% of the cases and showed the venous structure with higher signal intensity in 25% to 50% of the cases (Figs 3 and 4). In five MR angiograms acquired with imaging times of 20 to 26 seconds, arteries were selectively shown in 40% of the cases; in the other 60% of the cases, venous structures were visible but had lower signal intensity. In 92% to 100% of 21 patients in the second and latest phases of the trial, the MR angiograms acquired with imaging times of 11 to 16 seconds showed the arterial-phase carotid and vertebral arteries almost selectively, with practically no venous contamination (Fig 5).

No differences were found between evaluations of MR angiograms acquired with and without fat suppression.

Discussion

MR angiography of carotid and vertebral arteries is more difficult than that of the abdominal aorta (3). One reason is because of the rapid transit time through the cerebral vasculature. Another is that there are less contrast differences between the arteries and the veins, because the blood-brain barrier prevents extravasation of contrast material. This is why we need to start acquiring data using centric k-space ordering with optimal delay after injection of contrast medium to evaluate the carotid and vertebral arteries without overlapping veins.

In the MR Smartprep technique used in this study, the tracker sequence continuously monitors the MR signal from the vessels of interest. The signal from this region increases owing to the passage of contrast material in the arteries, and once the signal reaches the preset thresholds, the pulse sequence automati-

cally begins acquiring the imaging volume. Therefore, this technique could be used to match the center of k-space at MR angiography to the period of maximum effect of the first-pass bolus for the carotid and vertebral arteries. It could also be used to reduce the overlapping of venous structures and lead to the evaluation of carotid and vertebral arteries more easily.

By using a smaller tracker volume and about 15 seconds of imaging time in the second and latest phases of the trial, we were able to achieve a 100% successful triggering rate and to delineate selectively arterial-phase carotid and vertebral arteries without venous contamination. We believe that arterial-phase contrast-enhanced 3-D MR angiography of the carotid and vertebral arteries using the MR Smartprep technique is very useful. The technique enabled the acquisition of the 3-D data set in significantly shorter time as compared with conventional 3-D time-of-flight (TOF) MR angiography, which typically takes 15 minutes or more. Another advantage of this technique is that it may be used to delineate slow flow, vortex, and back flow due to the T1 shortening effect of the paramagnetic agents and short TE. This technique is expected to be useful in helping to correctly evaluate the carotid bifurcation. Conventional 3-D TOF MR angiography, on the other hand, is not good at visualizing this flow.

On the basis of our experience with this MR angiographic technique in the evaluation of carotid and vertebral arteries, we found several areas in which care must be taken. It is important to select a receiver coil (such as a head coil, a head and neck vascular coil, or a body coil) with regard to the patient's bodily structure and to the vessels of interest. For a screening test of the carotid and vertebral arteries from the aortic arch to the skull base, the head and neck vascular coil is recommended. Because its sensitivity around the arch is somewhat weak, the body coil is recommended for the accurate evaluation of the proximal parts of the innominate, common carotid, and left subclavian arteries (Figs 3–5). The tracker volume should be accurately placed at the vessels of interest. The imaging volume should be extended in the ventrodorsal direction enough to include the tortuous proximal innominate artery and the left common carotid artery and vertebral arteries at the C1 level. In the evaluation of carotid and vertebral arteries, the imaging time should be kept within approximately 15 seconds. The row of k-space should be filled from the center (centric ordering). To obtain high-resolution MR angiograms and to reduce the imaging time, ZIP is necessary in the section and in-plane directions. Fat suppression is not necessary for delineating carotid and vertebral arteries, because of relatively less adipose tissue around the neck. Although fat suppression may be useful for some patients, a longer imaging time is inevitable owing to the extra pulse needed for fat suppression. One recommended imaging protocol is as follows: a head and neck vascular coil or body coil, depending on bodily structure and the vessels of interest; in-plane ZIP; section ZIP; TR/TE/excitations, 6.2/1.4/0.75; flip angle, 30°; number of sections, 28 (effective number of sections, 56); section thickness, 4.0 to 5.0 mm (effective section thickness, 2.0 to 2.5 mm); FOV, 28 × 21 cm; bandwidth, 31.3 kHz; matrix, 256 × 128; no fat suppression; imaging time, 15 seconds; delay between trigger and image acquisition, 1 second; and centric ordering of k-space.

Conclusion

Contrast-enhanced 3-D MR angiography with the MR Smartprep technique was useful in showing arterial-phase carotid and vertebral arteries selectively from the aortic arch to the skull base within approximately 15 seconds.

References

1. Isoda H, Ushimi T, Masui T, et al. **Clinical evaluation of pulmonary 3-D time-of-flight MRA with breath holding using contrast media.** *J Comput Assist Tomogr* 1995;19:911–919
2. Earls JP, Rofsky NM, DeCorato DR, Krinsky GA, Weinreb JC. **Breath-hold single-dose gadolinium-enhanced three-dimensional MR aortography: usefulness of a timing examination and MR power injector.** *Radiology* 1996;201:705–710
3. Levy RA, Prince MR. **Arterial-phase three-dimensional contrast-enhanced MR angiography of the carotid arteries.** *AJR Am J Roentgenol* 1996;167:211–215
4. Prince MR, Narasimham DL, Stanley JC, et al. **Breath-hold gadolinium-enhanced MR angiography of the abdominal aorta and its major branches.** *Radiology* 1995;197:785–792
5. Foo TKF, Saranathan M, Prince MR, Chenevert TL. **Automated detection of bolus arrival and initiation of data acquisition in fast, three-dimensional, gadolinium-enhanced MR angiography.** *Radiology* 1997;203:275–280
6. Prince MR, Chenevert TL, Foo TKF, Londy FJ, Ward JS, Maki JH. **Contrast-enhanced abdominal MR angiography: optimization of imaging delay time by automating the detection of contrast material arrival in the aorta.** *Radiology* 1997;203:109–114
7. Maki JH, Prince MR, Londy FJ, Chenevert TL. **The effects of time varying intravascular signal intensity and k-space acquisition order on three-dimensional MR angiography image quality.** *J Magn Reson Imaging* 1996;6:642–651
8. Du YP, Parker DL, Davis WL, Cao G. **Reduction of partial-volume artifacts with zero-filled interpolation in three-dimensional MR angiography.** *J Magn Reson Imaging* 1994;4:733–741