AJNR

This information is current as of October 12, 2024.

# MR in a patient with Zellweger syndrome presenting without cortical or myelination abnormalities.

J A Stone and M Castillo

*AJNR Am J Neuroradiol* 1998, 19 (7) 1378-1379
http://www.ajnr.org/content/19/7/1378.citation

# LETTER

## MR in a Patient with Zellweger Syndrome Presenting without Cortical or Myelination Abnormalities

We read with interest the recent paper by Barkovich and Peck describing MR features of Zellweger syndrome (ZS) (1). All six patients in their series had impaired myelination, diffusely abnormal cortical gyri, and germinolytic cysts on MR imaging. Specifically, these abnormalities consisted of diminished myelination, microgyria (particularly in the frontal and perisylvian regions), pachygyria (primarily perirolandic and occipital regions), and germinolytic cysts in the caudothalamic grooves. A marked variation in the extent and appearance of these abnormalities was observed in all the six patients. Indeed, we believe that this spectrum of abnormalities may even include patients in whom only one of the above-mentioned abnormalities is present.

We recently encountered a patient in whom no cortical abnormalities or impaired myelination were present. Germinolytic cysts, however, were evident. She had a prenatal sonogram at 33 weeks of gestation with questionable hydrocephalus, but was the product of an uncomplicated vaginal delivery. At birth, she was floppy and unresponsive with low Apgar scores. Distinct facial features included an elongated forehead with hypoplastic supraorbital ridges, a large anterior fontanelle with widely split sutures, large palpebral fissures, and a small nose and ears. Bilateral clubbed feet were also present. The child soon developed generalized seizures with baseline slowing and multifocal spikes during the resting state. Chest and abdomen radiographs demonstrated stippled epiphyses in the humeri, femurs, and at the anterior aspect of the ribs. Abdominal sonogram showed bilateral renal cortical cysts, and echocardiography revealed a large bidirectional shunt of both the ductus arteriosus and at the fossa ovale. Skin biopsy for fibroblast culture and serologic studies demonstrated elevation of long chain fatty acids, elevated pipecolic acid, and a decrease in plasmalogen biosynthesis compatible with ZS. Electron microscopy was not done. MR imaging of the brain showed bilateral germinolytic cysts (Fig 1A). The cortex appeared normal and myelination was judged age-appropriate (Figs 1B and C).

We are not aware of other cases of ZS that exclude cortical or myelination abnormalities. It is, however possible, that because we obtained the MR study during the first week of life, these abnormalities had not yet become obvious. Nevertheless, Barkovich and Peck found typical abnormalities in all of their patients during the neonatal period. Similar imaging abnormalities may also be seen in patients with pseudo-Zellweger syndrome, but most of them occur in the cerebellum (2). The

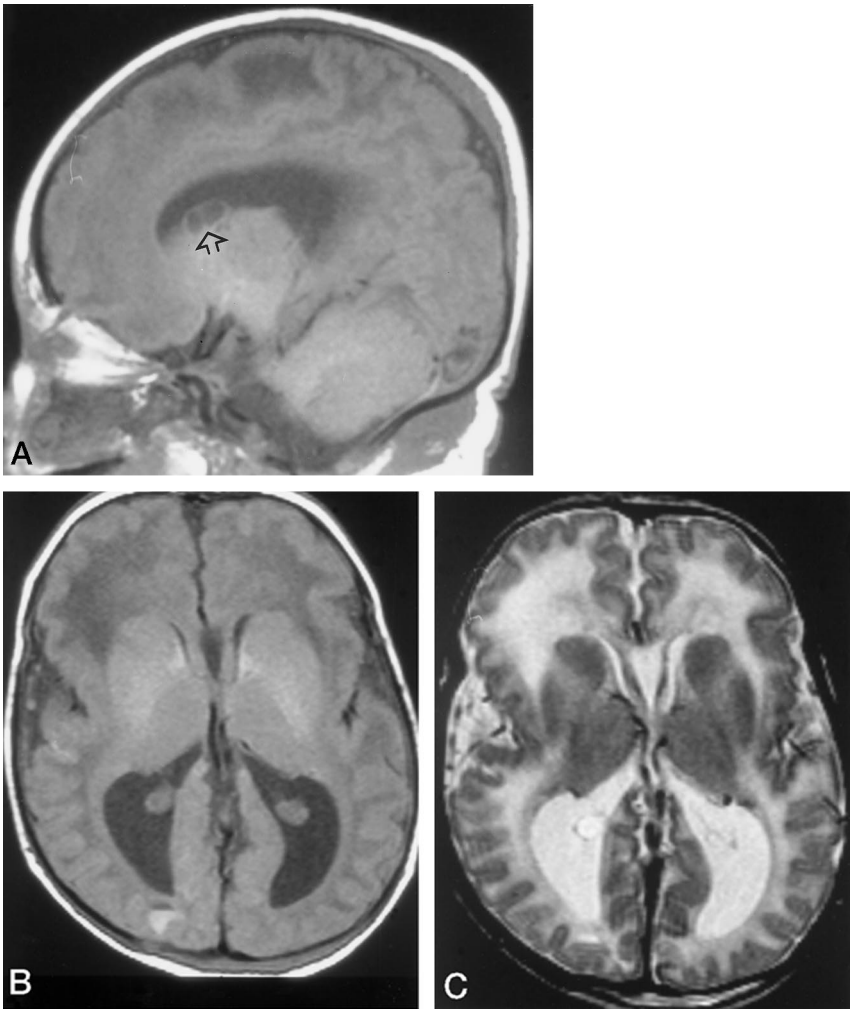


FIG 1. MR imaging in a patient with Zellweger syndrome.

*A*, Left parasagittal T1-weighted image (600/15/2 [TR/TE/NEX]) shows germinolytic cysts (*arrow*).

*B*, Axial T1-weighted image (600/15/2) shows normal brightness in posterior limbs of both internal capsules, reflecting adequate myelination at this level. The source for the dilatation of the atria and occipital horns of the lateral ventricles (colpocephaly) was not clear. The corpus callosum was present but thin. The reason for the small right occipital hemorrhage was also not clear.

*C*, Axial T2-weighted image (4000/93/1) at similar level as *B* shows relative low-signal intensity in posterior limbs of the internal capsules and along the optic radiations, appropriate myelination milestones for age. The appearance of the cortex is normal.

presence of peroxisomes on electron microscopy establishes the diagnosis of pseudo-ZS. Electron microscopy was not done in our case nor in the cases reported by Barkovich and Peck. Other disorders that may be clinically confused with ZS are neonatal adrenoleukodystrophy and infantile Refsum disease. The former lacks facial dysmorphism (which was present in our patient); the latter heralds with hepatomegaly and jaundice (not present in our patient) and a later onset of neurological symptoms. Neither entity is generally associated with renal cysts or chondrodysplasia. We believe that follow up imaging in patients with ZS may not be necessary once the diagnosis is established. The prognosis is dismal and the life-span very short.

Jeffrey A. Stone, M.D.
Mauricio Castillo, M.D.
*University of North Carolina at Chapel Hill*
*Chapel Hill, NC*

## References

1. Barkovich AJ, Peck WW. **MR of Zellweger Syndrome.** *AJNR Am J Neuroradiol* 1997;18:1163–1170
2. Goldfischer S, Collins J, Rapin I, et al. **Pseudo-Zellweger syndrome: deficiencies in several peroxisomal oxidative activities.** *J Pediatr* 1986;108:25–32

*Reply*

I welcome the opportunity to reply to Dr. Stone's and Castillo's letter about a patient with a clinical diagnosis of Zellweger syndrome but a normal MR scan. The patient that they describe seems to, indeed, have Zellweger syndrome. Careful analysis of the images that they supply, however, shows that the MR scan of this neonate is not completely normal. The interpretation of MR images of developmental malformations is often quite difficult because of the subtleties of the findings. In this particular case, the gyral pattern is abnormal, with too many gyri, many of which have abnormally shallow sulci. The normal orbital gyri, which should be seen on images at this level, are not normally formed. The Sylvian fissures are not normally formed; in particular, the right Sylvian fissure is dysplastic without normal frontal or temporal opercularization. In addition, the calcarine gyri are dysplastic, probably contributing to the appearance of colpocephaly. Another factor adding to the colpocephaly is that the splenium of the corpus callosum is either missing or abnormally thin. Some abnormal T1 and T2 shortening is seen immediately subjacent to the cortex in both frontal lobes, which probably represents neurons that have not completely migrated to the cortex. The caudate heads are too big and the lentiform nuclei too small, suggesting developmental abnormalities in the lateral ganglionic eminence, the germinal zone for the neurons that compose the deep gray matter nuclei. Finally, the stripe of short T1 and T2 relaxation time around the occipital horns is unlikely to be myelin because the optic radiations do not myelinate until about the third postnatal month (1–3). Because these areas appear isointense to the cortex, I would suggest that they are more likely to be a layer of heterotopic neurons.

A. James Barkovich
*Department of Radiology*
*University of California, San Francisco*

## References

1. Rorke LB, Riggs HE. *Myelination of the brain in the newborn.* Philadelphia, PA: Lippincott, 1969:28
2. Yakovlev PI, Lecours AR. **The myelogenetic cycles of regional maturation of the brain.** In: Minkowski A, ed. *Regional development of the brain in early life.* Oxford, UK: Blackwell; 1967:3–70
3. Brody BA, Kinney HC, Kloman AS, Gilles FH. **Sequence of central nervous system myelination in human infancy. I. An autopsy study of myelination.** *J Neuropath Exp Neurol* 1987;46:283–301