

Are your **MRI contrast agents** cost-effective?

Learn more about generic **Gadolinium-Based Contrast Agents**.



FRESENIUS
KABI

caring for life

AJNR

Primary intracranial meningeal and spinal hemangiopericytoma: radiologic manifestations.

D R Osborne, P Dubois, B Drayer, M Sage, P Burger and E R Heinz

AJNR Am J Neuroradiol 1981, 2 (1) 69-74

<http://www.ajnr.org/content/2/1/69>

This information is current as of May 3, 2024.

Primary Intracranial Meningeal and Spinal Hemangiopericytoma: Radiologic Manifestations

D. R. Osborne¹
P. Dubois¹
B. Drayer¹
M. Sage¹
P. Burger²
E. R. Heinz¹

Meningeal hemangiopericytomas are rare but aggressive tumors. All eight patients in this series developed recurrences, three with distant metastases. In six patients a lytic destructive lesion of bone was evident. CT scans in three patients demonstrated diffusely enhancing lesions. No tumor calcification was present. In five of six patients angiography was characterized by multiple irregular tumor vessels, an intense prolonged blush, and the absence of early draining veins. Differentiation of these tumors from meningiomas is discussed.

Hemangiopericytoma is a rare vascular tumor deriving from capillaries and pericytes [1-4]. Although it is a well established entity clinically and histologically, its occurrence in the intracranial meninges and spine has been controversial and, until recently, disputed [5-7]. Earlier investigators classified hemangiopericytomas as angioblastic variants of meningioma [5-7]. They are now considered separate both clinically and histologically [6, 8-12]. Hemangiopericytomas of the intracranial meninges and spine have a high rate of recurrence after primary therapy, occasionally metastasize, and tend to occur in a younger group of patients than do meningiomas [6-8, 11, 13, 14]. This report evaluates the radiologic findings in cases of primary hemangiopericytomas of the intracranial meninges and spine and investigates those features which may allow radiologic differentiation from meningioma.

Materials and Methods

Clinical and radiologic findings of eight cases of histologically proven hemangiopericytomas of the intracranial meninges and spine referred to Duke University Medical Center over a 20 year period were reviewed. Histologic diagnosis was by the Section of Neuro-pathology, Duke University Medical Center.

Results

All patients had an extraaxial mass. There were six patients with intracranial meningeal hemangiopericytomas, four supratentorial and two in the posterior fossa. The two lumbosacral spinal tumors presented with extradural masses (table 1).

On plain film examination, six of the patients had a lytic cranial or spinal lesion due to bone destruction (fig. 1A). None of the tumors generated a sclerotic bone response, and no tumor calcification was demonstrated.

A diffusely enhancing tumor was present in all patients who had had CT (figs. 2A, 3A, 3B and 4A). In one of these patients, bolus-contrast-enhanced rapid-sequence CT demonstrated areas of vascular pooling and variable matrix enhancement (fig. 2B) not seen on the conventional-enhanced examination. Tumor calcification was not seen.

Received July 22, 1980; accepted after revision September 9, 1980

¹Department of Radiology, Duke University Medical Center, Durham, NC 27710. Address reprint requests to D. R. Osborne, Box 3808.

²Department of Pathology, Duke University Medical Center, Durham, NC 27710.

AJNR 2:69-74, January/February 1981
0195-6108/81/0021-0069 \$00.00
© American Roentgen Ray Society

TABLE 1: Radiologic Findings in Hemangiopericytomas of the Intracranial Meninges and Spine

Case No. (Age, Gender)	Primary Site	Plain Film	CT, Scintigraphy, or Myelography	Angiography	Clinical Course
1 (54, M)	R occipital meninges	Destructive lesion R occipital bone	CT: diffusely enhancing peripheral right occipital tumor	Dense persistent tumor blush; no e.d.v.; Supply: middle meningeal and occipital arteries	...
	Recurrence	...	CT: diffusely enhancing tumor inferior surface tentorium	Irregular peripheral tumor vessels; dense persistent tumor blush; no e.d.v.; Supply: superior cerebellar, posterior vertebral meningeal arteries	Recurrence inferior surface of tentorium at 3 years
2 (32, M)	R occipital meninges	Destructive lesion R occipital bone	CT: diffusely enhancing posterior fossa tumor	Irregular peripheral tumor vessels. Dense persistent tumor blush; no e.d.v.; venous pooling; Supply: meningeal and posterior inferior cerebellar arteries	Pulmonary metastases at 9 years; posterior fossa occipitocervical recurrence at 18 years
3 (43, F)	Foramen magnum	Eroded foramen magnum	CT: diffusely enhancing posterior fossa tumor	Dense persistent tumor blush; no e.d.v.; Supply: meningeal and posterior inferior cerebellar arteries	Lytic metastasis L clavicle at 1 year; recurrence tentorium at 2 years
4 (35, F)	L middle cranial fossa floor	Destructive lesion, floor middle cranial fossa and petrous apex	...	Dense persistent tumor blush; Supply: meningeal artery	Recurrence middle cranial fossa at 2 years
5 (55, F)	L parietal meninges	Lytic lesion L parietal bone	Radionuclide scan: tumor uptake	Dense persistent tumor blush; no e.d.v.; Supply: meningeal, superficial temporal and occipital arteries	Recurrence L parietal region at 7 years
6 (47, F)	R sphenoidal ridge	Normal	Radionuclide scan: tumor uptake	Dense persistent tumor blush; Supply: middle meningeal and middle cerebral arteries	Local recurrence and subarachnoid seeding at 1 year
7 (38, F)	Sacrum	Lytic lesion sacrum	Myelogram: L5-S1-S2 extradural tumor	...	Local recurrence at 6 years
8 (43, F)	Lumbosacral junction	Normal	Myelogram: Lumbosacral extradural tumor	...	Pulmonary metastases

Note.—e.d.v. = early draining veins.

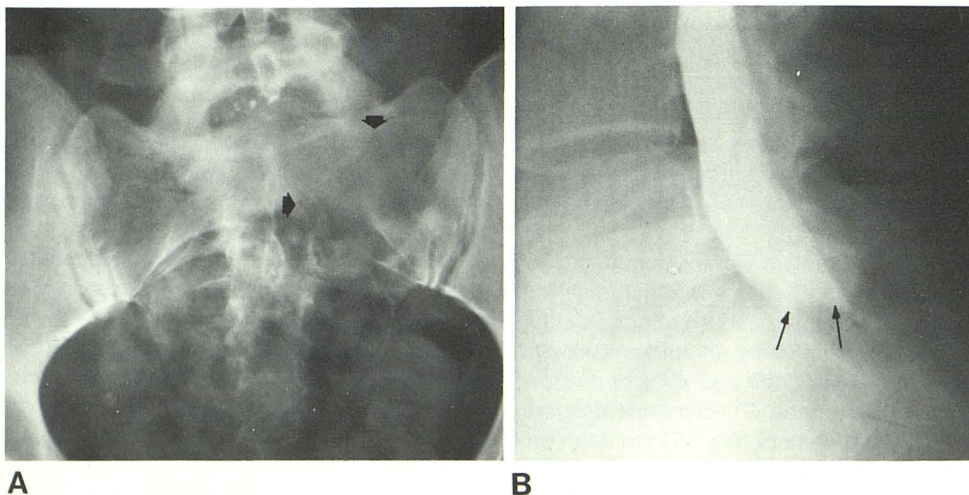


Fig. 1.—Case 7. Spinal hemangiopericytoma. A, Lytic lesion of left side of sacrum (arrows). B, Myelogram. Extradural mass effect on sacral subarachnoid sac (arrows).

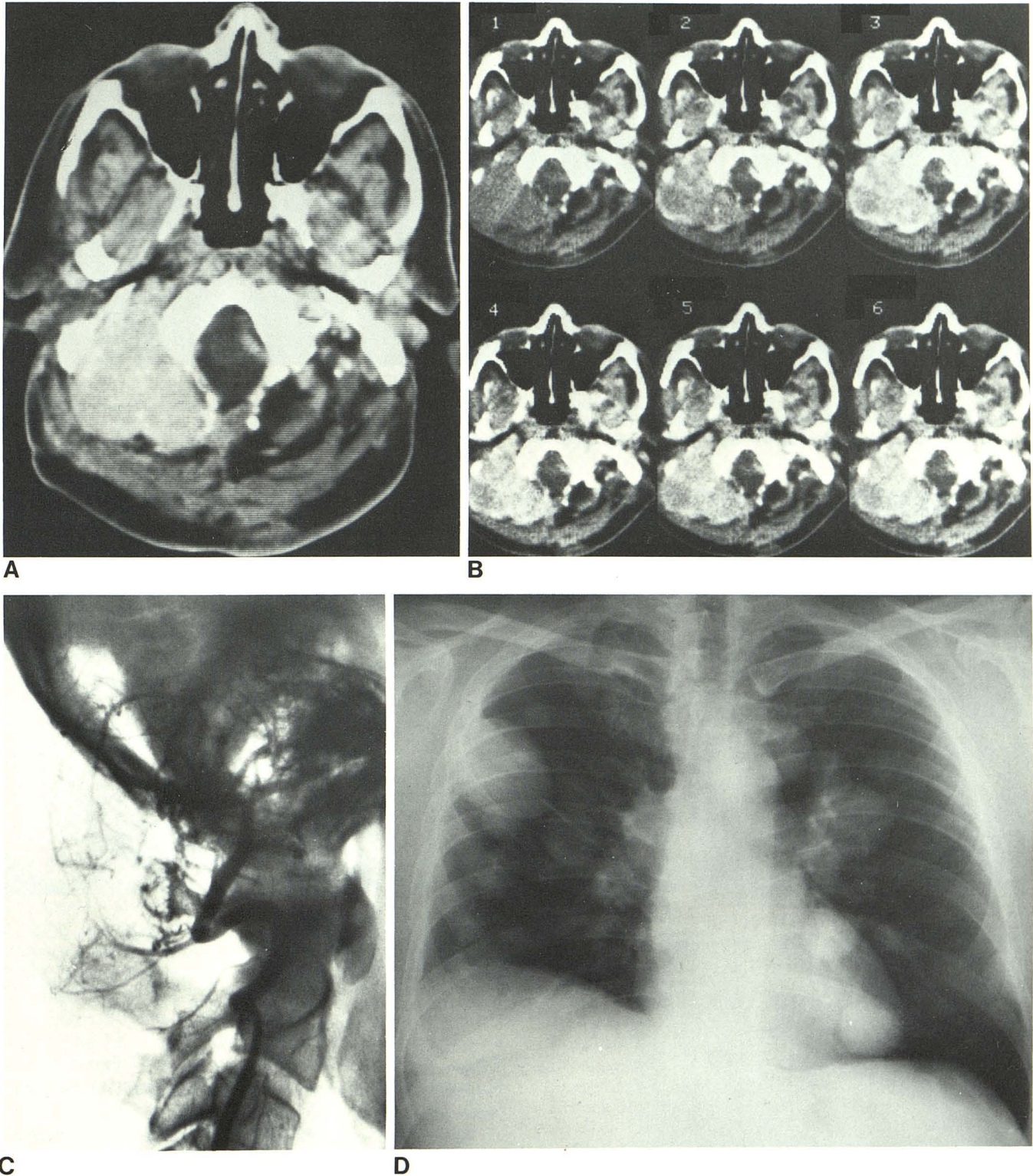


Fig. 2.—Case 2. Occipitocervical hemangiopericytoma. **A**, CT scan. Diffusely enhancing tumor, occipitocervical region. No calcification. **B**, Bolus contrast-enhanced rapid sequence CT. Serial scans of 4.8 sec duration, 1

sec apart. Vascular pooling, confirmed angiographically, and variable tumor matrix enhancement. **C**, Vertebral angiogram, arterial phase. Large irregular tumor vessels. **D**, Chest film. Pulmonary metastases.

Angiography demonstrated a highly vascular extraaxial mass with multiple irregular, predominantly peripheral early filling tumor vessels but no early draining veins (figs. 2C and 4B). In five of the six patients with angiography there was

persistent and dense tumor blush (figs. 4C and 4D). Vascular pooling of contrast material was present in one patient. The blood supply to the tumors was from branches of the meningeal arteries, but in four instances an additional supply

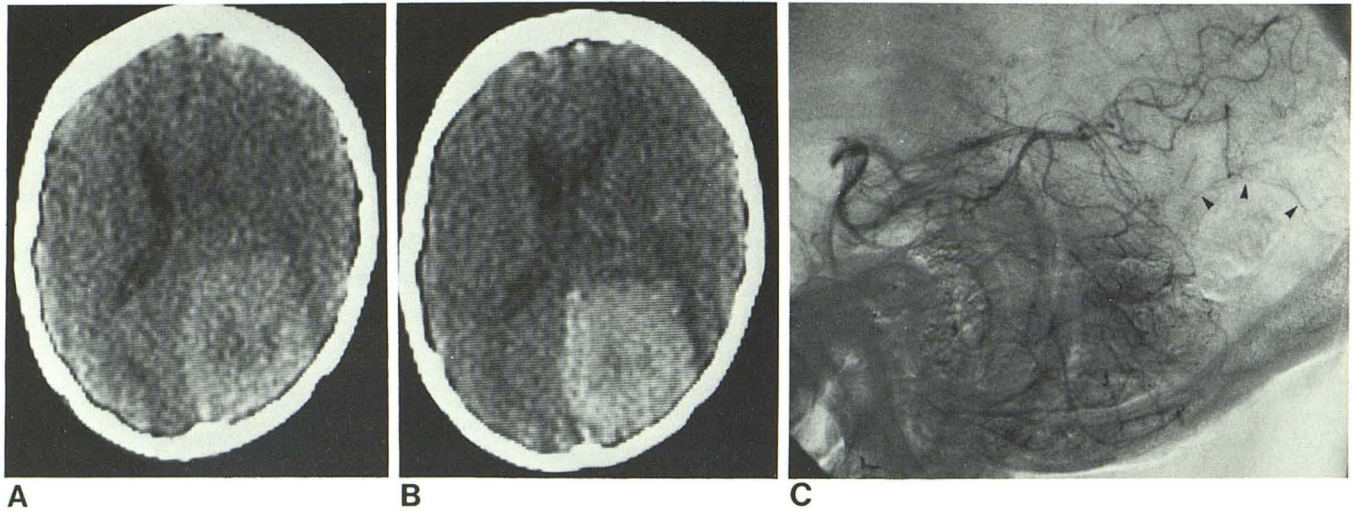


Fig. 3.—Case 1. Right occipital supratentorial hemangiopericytoma. **A**, Unenhanced CT scan. Tumor demonstrated by rounded area of slightly increased attenuation. **B**, Tumor enhancement with intravenous contrast. **C**,

Vertebral angiogram. Capsular branches from calcarine branch of posterior cerebral artery cap lesion (*arrowheads*). No tumor stain demonstrated on vertebral angiograms, but was present on external carotid study.

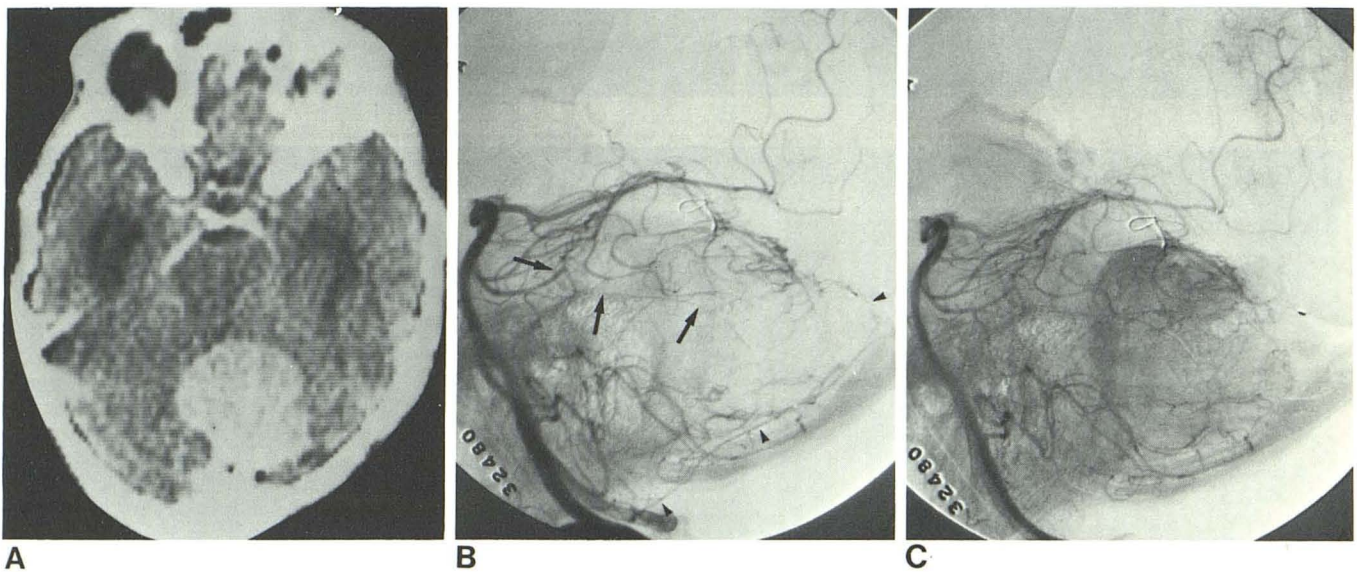


Fig. 4.—Case 1. Tentorial recurrence posterior fossa. **A**, Enhanced CT scan. **B**, Left vertebral angiogram, early arterial phase. Enlargement of posterior meningeal artery (*arrowheads*) which supplies periphery of tumor posterosuperiorly, while branches of superior cerebellar artery (*arrows*) supply tumor "capsule" anteriorly. **C** and **D**, Left vertebral angiogram, late arterial phase. Tumor blush. No early draining veins.

from either an intracranial internal carotid or vertebral artery was demonstrated (fig. 4B).

The two patients with spinal tumors had their extradural masses demonstrated at myelography (fig. 1B).

Surgery was the initial treatment in the eight patients, curative resection being attempted in five. Tumor recurrence developed in all eight, from as early as 1 year to as late as 18 years after surgery. Recurrence was local in four, adjacent to but not at original site in four, and in three patients distant metastases developed in the lungs and skeleton (fig. 2D).

Discussion

Stout and Murray [1, 2] coined the term hemangiopericytoma to describe a soft tissue neoplasm in which there are pericytic tumor cells tightly packed in and around capillaries and lymphatics. Reports of this tumor occurring intracranially and in the spine are very infrequent [6–8, 13]. There is one case report of a primary tumor involving the choroid plexus of a lateral ventricle [15]; in all others, the location has been primarily in the intracranial and spinal meninges. Kernohan and Uihlen [8] reported on 26 hemangiopericytomas to emphasize their distinct histologic features and high recurrence rate after primary treatment. Kruse [7] noted recurrence in six of eight cases he reported, while Goellner et al. [13], reviewing the Mayo Clinic experience (26 cases), found a recurrence rate of 80% and metastases in 23%. The aggressive nature of the tumor is a feature that further differentiates the hemangiopericytoma from meningiomas, even hemangioblastic meningiomas [11, 14] and is confirmed again in our study. In the spine, reports of primary hemangiopericytomas are even less frequent, but here also recurrences are common [7, 16–18]. Recurrence may be delayed and indolent. One of our patients (case 2) developed pulmonary metastases 9 years after primary resection of his occipital tumor. These metastases have been present untreated a further 9 years, at the end of which time two local recurrences of the occipital tumor have developed.

Radiologic analyses of the meningeal hemangiopericytomas is scant. Plain film examination has not been specifically addressed in previous reviews. In six of our patients there was a lytic bony lesion. No patient had a tumor that generated a sclerotic bone response. Lytic cranial or vertebral lesions have been noted incidentally and mentioned in case report summaries in six other cases [7, 17, 19].

Marc et al. [20] reported the angiographic findings in five intracranial hemangiopericytomas. They described multiple irregular feeding vessels, an intense "fluffy" stain, lack of early draining veins, and a prolonged tumor circulation. There was a dual arterial supply from meningeal arteries and branches of the internal carotids. They believed that the angiographic architecture was sufficiently different to allow a highly probable diagnosis of hemangiopericytoma. Our cases support their view; further, the angiographic architecture in their series and ours is similar to that described for hemangiopericytoma occurring elsewhere in the body [3, 19]. In six of our patients who had had angiography, the tumor was supplied primarily from meningeal vessels as befits a tumor of the meninges, but a dual arterial supply was present in four of these. In three of these (cases 1–3) the intracranial internal carotid or vertebral supply was most marked on the angiographic examination of the tumor recurrence. Tumor spread in these three patients was adjacent to but not at the site of the original tumor. In one patient (case 6) subarachnoid seedings were observed at operation. This is the probable mode of spread of tumor in cases 1–3 and is the most likely explanation for the dual arterial supply.

The appearance of an intracranial meningeal hemangiopericytoma on CT examination has not been reported pre-

viously. The unenhanced study demonstrated the tumor as an area of slightly increased attenuation in one patient, but in the other two there was no more than evidence of mass effect. Our three cases displayed a homogeneously enhancing tumor after contrast material; in one of these, bolus-contrast-enhanced rapid-sequence CT demonstrated venous pooling and a variable matrix enhancement.

No tumor calcification was seen in our series on the plain film examination or on CT in the three patients who had had this study. It has occasionally been reported in hemangiopericytomas elsewhere in the body, although never with an intracranial or spinal lesion.

Differentiation of hemangiopericytoma from meningioma is important because of the aggressive nature of hemangiopericytoma. Although the intracranial and spinal origin of both tumors is similar, a lytic cranial or spinal lesion, absent tumor calcification, and consistent angiographic features should raise the suspicion of hemangiopericytoma in a young patient. Careful histologic analysis is necessary, however, before any firm differentiation can be made.

REFERENCES

1. Stout AP, Murray MR. Hemangiopericytoma: a vascular tumor featuring Zimmermann pericytes. *Ann Surg* 1942;116:26–33
2. Stout AP. Tumors featuring pericytes. *Lab Invest* 1956;5:217–223
3. Angervall L, Kindbolm LG, Neilsen JM, Stener B, Svendsen P. Hemangiopericytoma. A clinicopathologic, angiographic and microangiographic study. *Cancer* 1978;42:2412–2427
4. Enzinger FM, Smith BH. Hemangiopericytoma. An analysis of 106 cases. *Hum Pathol* 1976;7:61–82
5. Cushing HW, Eisenhardt L. *Meningiomas*. Springfield, IL: Thomas, 1938:43–45, 785
6. Pitkethly DT, Hardman JM, Kempe LG, Earle KM. Angioblastic meningiomas. A clinical study of 81 cases. *J Neurosurg* 1970;32:539–544
7. Kruse F. Hemangiopericytoma of the meninges (angioblastic meningioma of Cushing and Eisenhardt). Clinicopathologic aspects and follow up studies in 8 cases. *Neurology* 1961;11:771–777
8. Kernohan JW, Uihlen A. *Sarcomas of the brain*. Springfield, IL: Thomas, 1962:108–119, 154–169
9. Lolova I, Kamenova M. Hemangiopericytoma of the brain: histological and histochemical study of four cases. *J Neurosurg* 1973;39:636–641
10. Popoff NA, Malinin TI, Rosomoff HL. Fine structure of intracranial hemangiopericytoma and angiomatous meningioma. *Cancer* 1974;34:1187–1197
11. Jellinger K, Slowik F. Histological subtypes and prognostic problems in meningiomas. *J Neurol* 1975;208:279–298
12. Pena CE. Intracranial hemangiopericytoma: ultrastructural evidence of its leiomyoblastic differentiation. *Acta Neuropathol (Berl)* 1975;33:279–284
13. Goellner JR, Laws ER, Soule EH, Okazaki H. Hemangiopericytoma of the meninges—Mayo Clinic Experience. *Am J Clin Pathol* 1978;70:375–653
14. Skullerud K, Loken AC. The prognosis in meningiomas. *Acta Neuropathol (Berl)* 1974;29:337–344
15. McDonald JV, Terry R. Hemangiopericytoma of the brain. *Neurology (Minneap)* 1967;11:497–502
16. Pitlyk PJ, Dockery MB, Miller RH. Hemangiopericytoma of the

- spinal cord. *Neurology* (Minneap) **1965**;15:649-653
17. Harris DJ, Fornasier VL, Livingston KE. Hemangiopericytoma of the spinal canal. *J Neurosurg* **1978**;49:914-920
 18. Schirger A, Uihlen A, Parker HL, Kernohan JW. Hemangiopericytoma recurring after 26 years; report of a case. *Proc Mayo Clin* **1958**;33:347-352
 19. Yaghmai I. Angiographic manifestations of soft tissue and osseous hemangiopericytomas. *Radiology* **1978**;126:653-659
 20. Marc JA, Takei Y, Schechter MM, Hoffman JC. Intracranial hemangiopericytomas. Angiography, pathology and differential diagnosis. *AJR* **1975**;125:823-832
 21. Sutton D, Pratt AE. Angiography of hemangiopericytoma. *Clin Radiol* **1967**;18:324-329