

Are your **MRI contrast agents** cost-effective?

Learn more about generic **Gadolinium-Based Contrast Agents**.



FRESENIUS
KABI

caring for life

AJNR

Sequential CT Scanning after Neonatal Intracerebral Hemorrhage

Leland Albright and Richard Fellows

AJNR Am J Neuroradiol 1981, 2 (2) 133-137

<http://www.ajnr.org/content/2/2/133>

This information is current as
of May 15, 2024.

Sequential CT Scanning after Neonatal Intracerebral Hemorrhage

Leland Albright¹
Richard Fellows²

Sequential computed tomographic scans were obtained in 41 neonates surviving intracerebral hemorrhage and in 41 comparable neonates without hemorrhage. Hemorrhages were present in only the parenchyma in five patients in both parenchyma and ventricles in 22, and in only the ventricles in 14. No patient exhibited progression of the initial hemorrhage on subsequent scans. Parenchymal hemorrhages were followed by areas of parenchymal hypodensity in 30%. The size of the mitral parenchymal hemorrhage did not correlate with the size of the subsequent hypodense areas. Intraventricular hemorrhages were small in 36%, moderate in 28%, and extensive in 36%. Clinically significant hydrocephalus developed in 32% of the patients and did not correlate with the extent of the intraventricular hemorrhage. Periventricular hypodensity was present at some time in 95% of neonates who bled and was present in 85% of the scans at 30–60 days of age. In the neonates without intracerebral hemorrhages, periventricular hypodensity was present in 57.5%. The hypodensity is thought due to leukomalacia, which may predict subsequent neurologic sequelae better than the severity of the hemorrhage or the development of hydrocephalus.

Of infants with birth weights of less than 1,500, 40%–70% are shown by computed tomography (CT) to have intracerebral hemorrhages, either intraventricular, parenchymal, or both [1–3]. Because of advances in neonatal care, increasing numbers of infants are surviving intracerebral hemorrhages, but are reported to have a high likelihood of severe neurologic sequelae [4, 5]. There are few clinical criteria to determine whether an infant surviving hemorrhages will have neurologic deficits or psychomotor retardation. However, in a small number of patients, the severity of hemorrhage on CT scans has correlated with neurologic sequelae [6].

CT scans obtained soon after hemorrhage have been well described, but there are few reports of morphologic changes by sequential imaging [3]. We studied intracerebral bleeding with sequential CT scans for two reasons: (1) to determine the frequency of postintraventricular hemorrhage hydrocephalus as a baseline for subsequent therapeutic efforts and (2) to determine morphologic changes that may be correlated with subsequent neurologic development.

Materials and Methods

During a 2 year period, CT scans were obtained with an EMI 5005 scanner in all neonates admitted to the neonatal intensive care nursery with birth weights less than 1,500 g or a clinical history indicative of intracerebral hemorrhage, as soon as the neonate's clinical condition permitted transportation to the scanner. Scans were evaluated on 41 infants who survived CT-documented bleeding for at least 28 days. Gestational ages were less than 32 weeks in 16 patients, 32–36 weeks in 15, and greater than 36 weeks in 10. The initial scans were obtained within the first 7 days postpartum in 34 of these neonates and at 8–24 days in the other seven. Subsequent scans were obtained at irregular intervals until they were normal, static, or an operation was required. A total of 153 scans from the 41

Received March 27, 1980; accepted after revision October 10, 1980

¹Department of Surgery, Division of Neurological Surgery, University of Louisville School of Medicine, Louisville, KY 40292.

²Department of Radiology, NORTONS-CHILDREN'S HOSPITALS, Louisville, KY 40202. Address reprint requests to R. Fellows.

This article appears in March/April 1981 *AJNR* and May 1981 *AJR*.

AJNR 2:133–137, March/April 1981
0195–6108/81/0022–0133 \$00.00
© American Roentgen Ray Society

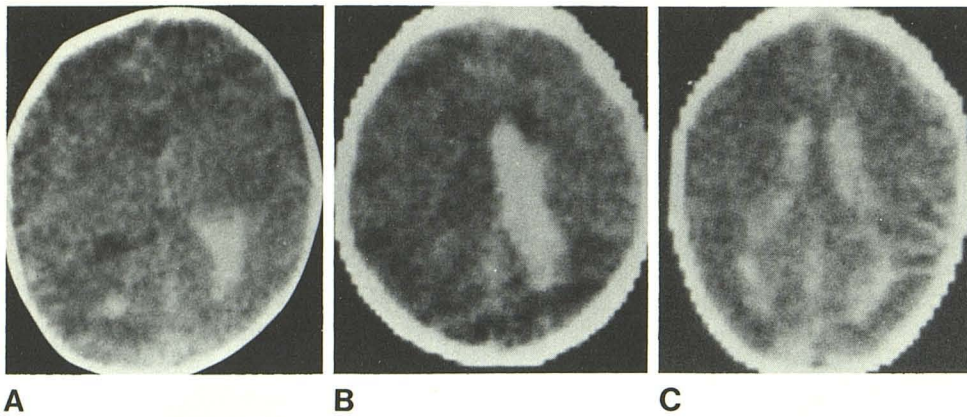


Fig. 1.—Small (A), moderate (B), and large (C) intraventricular hemorrhages. Hemorrhagic fluid occupied less than 30% of ventricular volume in small hemorrhage, 30%–65% in moderate, and more than 65% in large. In B, periventricular germinal matrix hemorrhage is also seen.

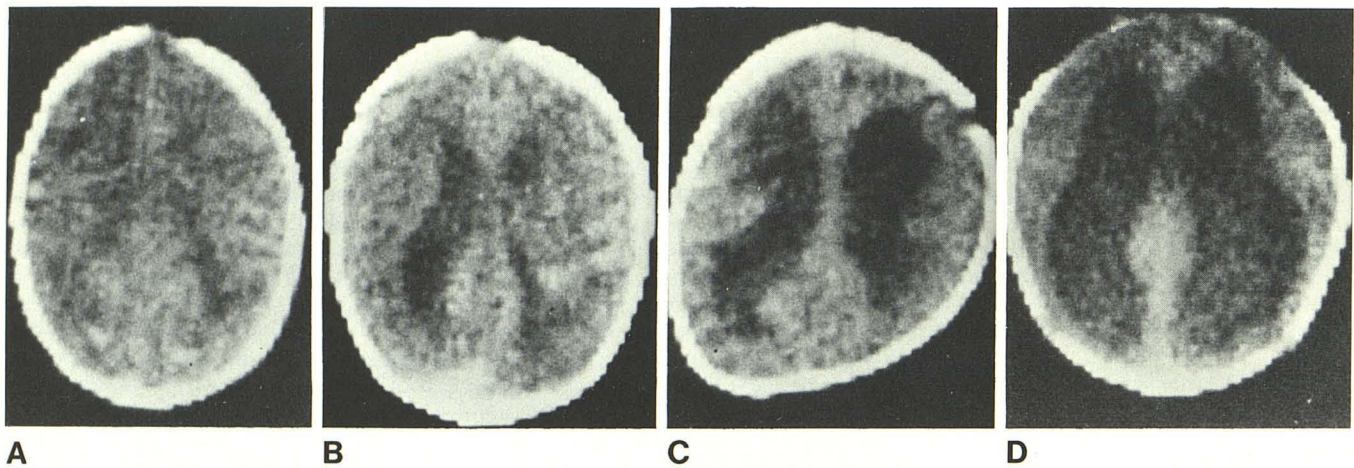


Fig. 2.—Ventricular size graded as normal (A), mildly enlarged (B), moderately enlarged (C), or markedly enlarged (D).

neonates was studied (average, 3.7 scans/patient). All neonates with intraventricular hemorrhage were treated with daily lumbar punctures to remove hemorrhagic cerebrospinal fluid.

We also reviewed the CT scans selected randomly of 41 neonates without intracerebral hemorrhage admitted to the neonatal intensive care unit during the study period. Criteria for scanning were comparable to those used for children with bleeding. Gestational ages were less than 32 weeks in 10 patients, 32–36 weeks in 10, and greater than 36 weeks in 21. Initial scans were obtained within the first 7 days after birth in 18 and within the first 2 weeks in 33. Follow-up scans were obtained in 12 of these, usually within 3 weeks after the first scan.

Scans were reviewed conjointly by the authors to determine the size and location of intracerebral hemorrhages, the extent of ventriculomegaly, and the presence of periventricular hypodensity. Most scans were reviewed conjointly on two occasions to assure uniform grading. Parenchymal hemorrhages were measured in two dimensions and the measurements corrected to obtain actual dimensions. Intraventricular hemorrhage was graded as small if hemorrhagic fluid occupied less than 30% of the ventricular volume, moderate if that fluid occupied 30%–65% of the ventricular volume, and large if it occupied over 65% (fig. 1). Ventricular size was graded as normal or as mildly, moderately, or markedly enlarged (fig. 2).

Periventricular hypodensity was evaluated by characterizing the extent and distribution of decreased cerebral density and was graded as absent, mild, moderate, or marked (fig. 3). Periventricular

hypodensity was only evaluated on scans of a quality sufficient to assess these density changes.

Results

Intraparenchymal hemorrhage, usually of the germinal matrix, was present in 27 neonates; it was only in the parenchyma in five and in both parenchyma and ventricles in 22. Parenchymal hemorrhage was in the periventricular germinal matrix in 24 cases, in the occipital lobes in two, and in the cerebellum in one. Three of the 27 patients with parenchymal hemorrhages had two separate hemorrhagic foci visible on the initial scan. None of the patients during the study period had recurrent bleeding or additional loci of bleeding on subsequent scans. Hemorrhages varied in size from 4.7×4.7 mm to 51.7×14.1 mm. Parenchymal hemorrhages often cleared slower than accompanying intraventricular hemorrhages. Clearance of the parenchymal hemorrhage was followed in eight of 27 neonates by areas of persistently decreased density probably representing loss of parenchyma (fig. 4). There was no correlation between the size of the parenchymal hemorrhage and the size of the subsequent area of hypodensity. Parenchymal hemorrhages of 20×15 mm often produced no residual area of hypodensity.

Fig. 3.—Sequential periventricular hypodensity changes. Moderate bifrontal (A), diffuse with obliteration of ventricular outline (B), and moderate right hemispheric and mild left frontal (C). All scans were obtained at similar baseline angles.

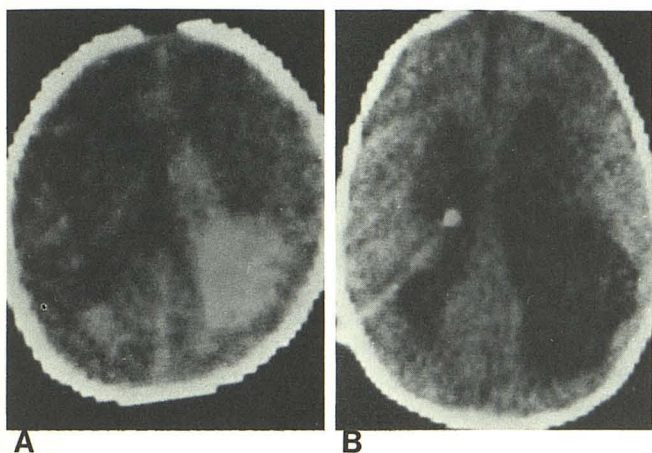
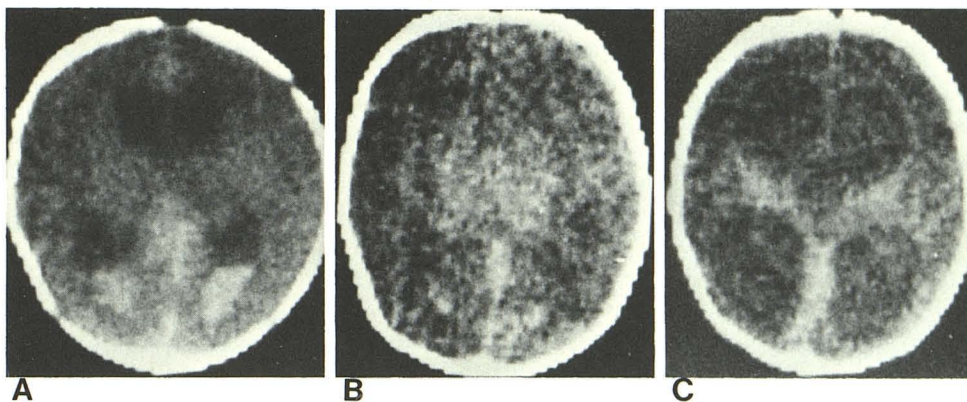


Fig. 4.—A, Left parietal parenchymal hemorrhage with intraventricular extension. B, Subsequent left parietal atrophy-porencephaly.

Intraventricular bleeding occurred in 36 neonates; it was associated with parenchymal bleeding in 22 and alone in 14. It was mild in 13 neonates, moderate in 10, and severe in 13. The time necessary for clearance of the hemorrhage fluid from the ventricles was dependent on the severity of the initial hemorrhage: ventricular fluid cleared within 7–9 days after a small hemorrhage and within 12–14 days after an extensive hemorrhage. The relation between severity of bleeding and subsequent ventricular size are shown in table 1.

The initial ventricular size was normal in 23 neonates mildly enlarged in 14, and moderately enlarged in four. it subsequently increased in 15, remained static in 21, and decreased in five (table 2). Most of the ventricular enlargement occurred at 7–21 days old. Although ventricle size increased in 15 patients, in only 13 patients was it necessary, because of excessive progressive ventriculomegaly or developing signs of intracranial hypertension, to introduce shunts. None of these 13 patients exhibited CT characteristics of cerebral atrophy. CT scans were obtained in nine patients after shunt insertion. The ventricles were reduced to normal size in six, to mildly dilated in two, and to moderately dilated in one.

Periventricular hypodensity was present on the initial scan

TABLE 1: Extent of Intraventricular Hemorrhage Related to Subsequent Ventricular Size

Extent of Hemorrhage	Subsequent Ventricular Size			Total
	Increased	Static	Decreased	
Absent	1	4	0	5
Small	6	6	1	13
Moderate	5	5	0	10
Large	3	7	3	13
Total	15	22	4	41

TABLE 2: Initial Ventricular Size Related to Subsequent Ventricular Size

Initial Size	Subsequent Size			Total
	Increased	Static	Decreased	
Normal	8	15	0	23
Slightly enlarged	5	4	5	14
Moderately enlarged	2	2	0	4
Total	15	21	5	41

in 31 of 41 patients surviving intracerebral hemorrhage and was present on subsequent scans in another eight patients. The periventricular hypodensity was initially mild in 22, moderate in six, and severe in three. Periventricular hypodensity appeared more extensive on scans 1–3 weeks after the initial scan, with the involved areas becoming larger or showing progressively decreasing attenuation values in 22. Resolution of hypodensity was prolonged. It was present on 22 of 26 scans obtained at 30–60 days of age and on eight of 10 scans obtained after 60 days of age (fig. 5). Focal areas of hypodensity progressed to areas of porencephaly in two patients.

In the group of neonates without intracerebral hemorrhages, the ventricles were of normal size on the initial scan in all patients. Hydrocephalus subsequently developed in two. Periventricular hypodensity was present in 23 of the 40 patients who had adequate quality scans. It was graded as mild in 14, moderate in seven, and severe in two. Its distribution was similar to that of neonates with bleeding (i.e., frontal in 45%, both frontal and parieto-occipital in

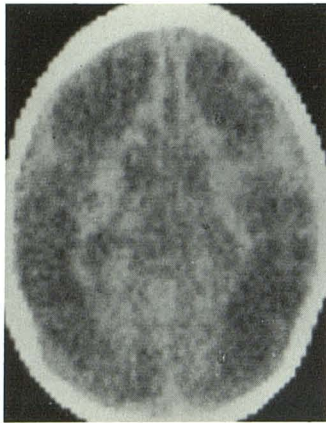


Fig. 5.—7-month-old patient. Diffuse hypodensity.

33%, parieto-occipital in 8%, and diffuse in 15%). The mean gestational age of neonates with mild hypodensity was 35.8 weeks; it was 36.6 weeks for those with moderate and 34 weeks for the two with severe hypodensity. The Rolandic fissure area was relatively unaffected in both the group with and the group without bleeding. Only 12 neonates in this group had subsequent scans, usually obtained within 3 weeks after the first scan. The hypodensity was either larger or lower in attenuation values in seven of the 12.

Discussion

The value of CT scans for the diagnosis of neonatal intracerebral hemorrhage and posthemorrhagic hydrocephalus has been well demonstrated. CT scans often demonstrate unsuspected bleeding or ventriculomegaly that is unaccompanied by an increase in the occipito-frontal circumference [3, 6, 7]. Computed tomographic scans have two advantages over air ventriculography: (1) they avoid the artifactual enlargement of the ventricles that occurs after installation of air and (2) they avoid the risk of porencephaly at the site of ventricular puncture.

Burstein et al. [1] used CT scans to prospectively study 100 premature infants during the first week of life. He found intracerebral hemorrhage of varying severity in 44 and intraventricular hemorrhage of varying severity in 34. In his series, none of the 10 neonates with intraventricular hemorrhage developed hydrocephalus if the ventricles were initially normal, although four of the neonates died. Eight of the nine surviving children with initial ventriculomegaly developed hydrocephalus. Our data suggested a correlation between initial ventriculomegaly and the later development of hydrocephalus; hydrocephalus necessitating shunting developed in six of 23 (26%) children with initially normal ventricles, five of 14 (36%) of those with mild ventriculomegaly, and in two of four (50%) infants with moderate ventriculomegaly.

Ventricular enlargement did not correlate well with the severity of the intracerebral bleeding. Enlargement occurred in six of 13 (46%) of those with mild, in five of 10 (50%) of those with moderate, and in three of 13 (23%) of those with severe hemorrhages. Lack of correlation between the de-

gree of hemorrhage and the development of hydrocephalus has been observed previously [8].

The percentage of infants who developed hydrocephalus after intraventricular hemorrhage is lower in our series than in other reports. Two percent of our patients developed progressive ventricular enlargement of signs of increased intracranial pressure and required a cerebrospinal fluid shunt. Krishnamoorthy et al. [9] found hydrocephalus in four of six patients and Meyer et al. [10] in 14 of 21 patients. The lower incidence of hydrocephalus is not attributable to milder degrees of bleeding in this series since moderate or severe bleeding was present in 64% of the neonates. We do not attribute the lower incidence of hydrocephalus in our study to the removal of hemorrhagic cerebrospinal fluid via lumbar punctures. In our experience, about 40% of neonates with bleeding lack communication of air between the lumbar subarachnoid space and ventricles and should not benefit from removal of hemorrhagic lumbar cerebrospinal fluid.

Periventricular hypodensity was found with approximately equal frequency and severity in neonates with or without bleeding. Although some hypodensity may be attributable to immature myelination, two factors suggest that it often represents periventricular leukomalacia. First, hypodensity worsened on subsequent scans on 54% of neonates with bleeding and in 58% of those without, and was often evident on scans 2–5 months postpartum; hypodensity should have regressed as myelination proceeded. Second, the distribution of hypodensity is comparable to that of periventricular leukomalacia in autopsy series [5]. Decreased CT attenuation values were not interpreted as edema because of persistence on CT scans at 30–60 days of age and absence of mass effects.

Sonography has been used recently to detect germinal matrix hemorrhages and ventriculomegaly in premature infants [11]. Sonography avoids the neonatal irradiation required for CT but has two limitations: (1) it does not accurately evaluate periventricular leukomalacia unless the periventricular leukomalacia has progressed to the point of porencephaly and (2) it does not demonstrate that hemorrhagic fluid has cleared sufficiently for shunt insertion. We agree with Burstein et al. [1] that CT scans should be obtained in all neonates less than 1,500 g and, in centers without sonographic equipment, it should be repeated until the infants are stable, or until treatment is needed. In centers with both CT and sonographic scanning, CT scans at 3 and 6 months of age may demonstrate white matter changes of possible prognostic significance.

The spectrum of periventricular leukomalacia evident in autopsy specimens was characterized by Banker and Larroche [12] in 1962. Grossly, periventricular leukomalacia initially produces foci of coagulation necrosis that are often asymmetrical, most commonly anterior to the frontal horn, at the lateral corners of the lateral ventricles, and at the lateral surfaces of the occipital horns. Periventricular leukomalacia has been attributed to a localized failure of perfusion (i.e., ischemia) in the periventricular border zones between ventriculopedal circulations [4, 5]. It has not been attributed to generalized hypoxia because the lesions are

pathologically characteristic of infarction and because areas characteristically damaged by hypoxia (cerebellar cortex and hippocampus) are normal.

A CT spectrum of periventricular hypodensity was also present, ranging from a unilateral, frontal, mild decrease in density to bilateral, diffuse, markedly decreased densities that extended to the cortical surfaces. It thus appears that the term *periventricular* is a misnomer, since CT scans demonstrate that the involvement extends for significant distances away from the periventricular regions. Lee et al. [3] evaluated CT scans in 21 neonates with bleeding. Seven of their 10 patients with serial scans demonstrated periventricular low attenuation values.

We believe that the predominant pathophysiology is white matter ischemia, which may cause periventricular leukomalacia alone, or may induce cerebral hypertension, with rupture of periventricular vessels [13]. The frequent occurrence of periventricular hypodensity in critically ill neonates without intracranial hemorrhage is in accord with this hypothesis.

The sequential CT scans demonstrate a spectrum of hemorrhagic, ventricular, and white matter changes. In a small number of patients, neurologic outcome has correlated with the severity of parenchymal hemorrhage seen on CT scans [6]. We predict that subsequent neurologic sequelae will correlate better with areas of prolonged periventricular hypodensity and areas of parenchyma damaged by the germinal matrix hemorrhage than with severity of bleeding or development of hydrocephalus. Thus, CT scan characteristics augment the neonatal signs currently used to predict cerebral palsy [14].

REFERENCES

- Burstein J, Papile L, Burstein R. Intraventricular hemorrhage and hydrocephalus in premature newborns: a prospective study with CT. *AJR* 1979;132:631-635
- Papile LA, Burstein J, Burstein R, Koffler H. Incidence and evolution of subependymal and intraventricular hemorrhage: a study of infants with birth weights less than 1500 gm. *J Pediatr* 1978;92:529-534
- Lee BCP, Grassi AE, Schechner S, Auld PAM. Neonatal intraventricular hemorrhage: A serial computed tomography study. *J Comput Assist Tomogr* 1979;3:483-490
- Armstrong D, Norman MG. Periventricular leukomalacia with neonates. *Arch Dis Child* 1974;45:367-375
- DeReuck J, Chatta AS, Richardson EP. Pathogenesis and evolution of periventricular leukomalacia in infancy. *Arch Neurol* 1972;27:229-236
- Krishnamoorthy KS, Shannon DC, DeLong GR, Todres ID, Davis KR. Neurologic sequelae in the survivors of neonatal intraventricular hemorrhage. *Pediatrics* 1979;64:233-237
- Volpe JJ, Pasternak JF, Allan WC. Ventricular dilation preceding rapid head growth following neonatal intracranial hemorrhage. *Am J Dis Child* 1977;131:1212-1215
- Korobkin R. The relationship between head circumference and the development of communicating hydrocephalus in infants following intraventricular hemorrhage. *Pediatrics* 1975;56:74-77
- Krishnamoorthy KS, Fernandez RA, Momose KJ, et al. Evaluation of neonatal intracranial hemorrhage by computerized tomography. *Pediatrics* 1977;59:165-172
- Meyer GA, Grausz JP, Browning CA, Claspey J. Intraventricular hemorrhage and post hemorrhagic hydrocephalus in premature infants; a follow up study. *American Association of Neurologic Surgeons Annual Meeting, 1979. Scientific manuscripts*. Chicago: AANS, 1979: 125-126
- Pape KE, Cusick G, Houang MTW, et al. Ultrasound detection of brain damage in preterm infants. *Lancet* 1979;1:1262-1264
- Banker BQ, Larroche JC. Periventricular leukomalacia of infancy: a form of neonatal anoxic encephalopathy. *Arch Neurol* 1962;7:386-410
- Pape KE, Wigglesworth JS. *Hemorrhage, ischemia and the perinatal brain*. Philadelphia: Lippincott, 1979:144-146
- Nelson KB, Ellenberg JH. Neonatal signs as predictors of cerebral palsy. *Pediatrics* 1979;64:225-232