

Are your **MRI contrast agents** cost-effective?

Learn more about generic **Gadolinium-Based Contrast Agents**.



FRESENIUS
KABI

caring for life

AJNR

Iatrogenic embolization: complication of pediatric cerebral angiography.

H Pettersson, C R Fitz, D C Harwood-Nash, S Chuang and E Armstrong

AJNR Am J Neuroradiol 1981, 2 (4) 357-361

<http://www.ajnr.org/content/2/4/357>

This information is current as of May 3, 2024.

Iatrogenic Embolization: Complication of Pediatric Cerebral Angiography

Holger Pettersson¹
Charles R. Fitz
Derek C. F. Harwood-Nash
Sylvester Chuang
Edward Armstrong

Fourteen cases of inadvertent iatrogenic embolization of cerebral vessels occurring in a consecutive series of 3,731 angiographies in infants and children were studied. The incidence of embolization (0.9% of all patients and 0.4% of all angiographic examinations) was about the same as has been reported in adults, but the clinical consequences were much milder, only one patient having documented transient neurologic symptoms. Also the angiographic appearance of the emboli differed from those described in adults. These differences may in part be due to the technique (general anesthesia with hyperventilation) but also to different reactions towards ischemia and to different types of emboli in children.

The serious complications of cerebral angiography are injuries to the central nervous system, and an important cause of these is embolization from the catheterization procedure. While this has been thoroughly investigated in adults [1-7], only a few reports concern young adults [8], and none concern children. We report a study of inadvertent embolization during cerebral angiography in infants and children.

Materials and Methods

Our subjects emanate from a series of angiographic examinations of 3,731 cerebral vessels in 1,581 consecutive patients (2.4 vessels/patient) at The Hospital for Sick Children, Toronto, during a 9½ year period. There were 743 girls and 838 boys, ages 2 days to 18 years (mean, 8.0 years).

During the study period, all angiographic examinations were reviewed by a group of one to three staff neuroradiologists and one or two fellows before reporting. All radiologic signs of complications were recorded in a special file. After the procedure, the patients were observed at the postanesthetic room for the first 6 hr, and after that on the ward. All adverse effects observed were recorded and reported to the department of radiology.

The distribution of arteries examined is given in table 1. With very few exceptions the examinations were performed under general anesthesia with controlled ventilation. The patients were hyperventilated to get a P_{CO_2} of about 30 mm Hg, resulting in an optimal yet safe blood flow for the angiographic examination [9].

Most patients had a femoral puncture (table 1), using the Seldinger technique after which a catheter was guided under fluoroscopic control into the artery of interest. In a small number of cases when a carotid artery could not be catheterized or the femoral artery could not be punctured, a direct needle puncture was performed, the contrast material being injected through the needle. The vertebral artery was never directly punctured. In five cases a retrograde brachial injection was performed after cut-down on the brachiocephalic artery.

Polyethylene catheters (B-D Hanafée), shaped in the department, were used for the first 4 years, after which preformed polyethylene (Cook) catheters were used. The diameter depended on the size of the patient: less than 10 kg, 3.0 French; 10-20 kg, 4.1 French; greater than 20 kg, 5.1 French.

The contrast medium used was Hypaque 60%. Each injection consisted of 1.5-8 ml

Received December 2, 1980; accepted after revision February 11, 1981.

¹ All authors: Department of Radiology, Division of Special Procedures, The Hospital for Sick Children, 555 University Ave., Toronto, Ontario, Canada M5G 1X8. Address reprint requests to H. Pettersson.

AJNR 2:357-361, July/August 1981
0195-6108/81/0204-0357 \$00.00
© American Roentgen Ray Society

depending on the size of the patient and the vessel. The injections were performed with a volume-rate monitored pressure injector. During the catheterization maneuver, the catheter was flushed every

1–2 min with heparinized saline, and between the angiographic series in the same artery the flushing was performed with contrast medium via the pressure injector.

Of the 1,581 patients, cerebral angiography was performed by an experienced staff neuroradiologist in 707 (44%) and by a fellow under staff supervision in 874 (56%).

All cases of iatrogenic embolization were collected. To avoid omitting any cases that were not recorded in the file, all the reports of the angiographic examinations were reviewed, and the cases in which an inadvertent embolization might have occurred were noted. Their radiographs, clinical charts, and complications file records were studied to select those in whom an inadvertent iatrogenic embolization could be established according to the following criteria: (1) partial or total occlusion of one or more branches of intracerebral vessels in one angiographic series but not in the previous or following and (2) occlusion in the first and following angiographic series in an area from which the patient had no previous symptoms, and in which no other pathologic changes were seen.

The charts thus selected were scrutinized for clinical signs and symptoms and laboratory data before, during, and after the angiographic procedure. All patients in whom embolization had occurred had been extensively examined by a neurologic consultant both in the postanesthetic room and later on the ward.

TABLE 1: Type of Examination and Vessels Examined in 1,581 Patients

Technique/Vessel	No. Examined (%) (n = 3,731)
Femoral catheterization:	
Right internal carotid	1,255 (33.6)
Right common carotid	18 (0.4)
Left internal carotid	1,238 (33.2)
Left common carotid	13 (0.3)
Right external carotid	61 (1.6)
Left external carotid	59 (1.6)
Right vertebral	220 (5.9)
Left vertebral	834 (22.4)
Retrograde brachial catheterization:	
Right brachial artery	4 (0.1)
Left brachial artery	1 (0)
Direct puncture:	
Right carotid	10 (0.2)
Left carotid	18 (0.4)

TABLE 2: Cases in Which Accidental Cerebral Embolization Occurred

Vessel Injected/Case No.	Age, Gender	Site of Emboli	Radiologic Appearance		Final Diagnosis
			Occlusion	Change Between Two Angiographic Series	
Right internal carotid:					
1	3 weeks, F	One angular branch of middle cerebral	Partial	Yes	Hydrocephalus
2	9 years, F	One branch of anterior cerebral	Total	No	Meningitis
3	6 years, F	One posterior temporal branch of middle cerebral	Total	Yes	Seizures
Left internal carotid:					
4	7 years, F	Two, posterior branches of middle cerebral	Partial	Yes	Old clots from arteriovenous malformation
5	11 years, F	Two frontoparietal branches of middle cerebral	Partial	?	Migraine
6	5 years, F	One frontoparietal branch of middle cerebral	Partial	Yes	Meningitis
7	10 years, F	Two posterior branches of middle cerebral	Total	No	Migraine
8	6 years, F	One anterior temporal branch of middle cerebral plus middle cerebral itself	Total; partial	Yes	Seizures
9	10 years, M	One precentral branch of middle cerebral	Total	Yes	Seizures
Left vertebral:					
10	1 week, F	One left posterior cerebral; multiple in branches of left posterior cerebral	Partial; total	Yes; yes	Encephalocele
11	6 years, M	One right posterior cerebral; one left posterior cerebral	Partial; partial	Yes; yes	Sagittal stenosis
12	9 years, M	One branch of superior cerebellar	Total	Yes	Brain tumor
13	10 years, M	Multiple posterior branches of left posterior cerebral	Total	No	Seizures
Right external carotid:					
14	14 years, M	Three branches of middle cerebral; origin of superior thyroid artery	Total; total	?	Parathyroid adenoma

Note.—There were no clinical signs of embolization, except in case 14, which had transient signs.

Results

A summary of the patients and the vessels with iatrogenic embolization is presented in table 2. It occurred in 14 children, 0.9% of all patients and 0.4% of all angiographic examinations. There were 32 vessels examined in nine girls and five boys, ages 1 week to 14 years (mean, 7.8 years) (2.3 vessels/patient). In each, the embolization occurred only in the branches of one of the major vessels. A staff radiologist performed five of the examinations and a fellow performed nine. The duration of the total examination, including all vessels studied, was 0.5–2.9 hr (mean, 1.7 hr).

The distribution of vessels affected, compared with the total frequency of examination of each vessel in general, is given in table 3. A comparison between some angiographic procedure data obtained in all the patients and the 14 with embolism is presented in table 4.

The radiologic appearance of the embolized cerebral vessels varied (table 2). Of the nine cases in which the catheter tip had been positioned in the internal carotid artery, the emboli appeared in different small branches of the middle cerebral artery of the same side in eight cases and in branches of the anterior cerebral artery in one case. In the patient who had iatrogenic embolization of the superior thyroid artery, the emboli appeared in branches of the middle cerebral artery. Of the four cases in which the catheter tip had been placed in the left vertebral artery, the emboli appeared in the area of the left or right posterior cerebral arteries in three cases and in the area of the superior cerebellar artery in one. Total occlusion occurred in 50% of the vessels involved by the embolus with delayed flow or retrograde filling of the branches distal to the point of occlusion. In six of the 14 patients the blood flow across the embolized area improved in subsequent angiograms during the same examination, since the embolus partially dissolved and moved peripherally. In three patients the

emboli had disappeared totally (fig. 1). In the other five cases there was either no change in the angiographic appearance between the series or any change was impossible to recognize. In no case did the embolus extend or the blood flow deteriorate from the immediate postembolization angiographic series to the next.

In the 13 cases in which general anesthesia was used, no neurologic disturbance whatsoever due to the embolization could be detected, either immediately or at follow-up (0–10 years). One patient (case 14) was examined under sedation and local anesthesia. He suddenly developed partial left-sided facial paresis and weakness of the left hand during contrast medium injection in the right superior thyroid artery. The angiogram revealed a large thrombus at the origin of the superior thyroid artery. A subsequent angiographic series in the right internal carotid artery revealed occlusion of three branches of the middle cerebral artery, with disturbed peripheral circulation. The neurologic disturbances were much less pronounced 2 hr after the examination and had totally disappeared 24 hr later.

Discussion

It was not possible to review all radiologic examinations since most of the radiographs from the first years were unavailable. However, because all examinations were reviewed by several experienced radiologists before reporting, and signs of complications were recorded in a special file, the way in which our cases were collected was mainly prospective. Thus we believe the true frequency of inadvertent embolization is accurately reported.

The frequency of inadvertent embolization varies greatly in different reports, depending on different ways of collecting the cases and on different definitions of the complication [5, 10]. Our frequency of 0.9% of the patients and 0.4% of examined vessels is about the same as that reported in 1977 by Olivecrona [5] from adult material also collected prospectively.

It is striking that all but one embolus from a carotid artery injection involved the middle cerebral branches. This agrees with the 1962 experimental observations of Luessenhop et al. [3], and reflects the flow pattern of the cerebral arteries. Widening of the vessels distal to the occlusion observed by Cronquist et al. [1] was not confirmed, probably because of the hyperventilation technique we used.

TABLE 3: Distribution of Vessels Embolized Compared with Frequency of Examination of Each Vessel

Vessel	No. Examined (%) (n = 3,731)	No. Embolized Vessels (% of Total)
Right internal carotid	1,255 (34)	3 (21)
Left internal carotid	1,238 (33)	6 (43)
Left vertebral	834 (22)	4 (29)
Right external carotid	61 (2)	1 (7)

TABLE 4: Comparison of Data in All Patients Examined and in Patients with Emboli

Data	All patients (n = 1,581)	Patients with Emboli (n = 14)
No. boys (%)	848 (53)	5 (36)
No. girls (%)	743 (47)	9 (64)
Age range	2 days to 18 years (mean, 8.0 years)	1 week to 14 years (mean, 7.8 years)
No. vessels examined per patient	2.4	2.3
No patients examined by a fellow (%)	874 (55)	9 (64)
Examination time (hr)	mean, 1.4	0.5–2.9 (mean 1.7)
Pco ₂ during examination (mm Hg)	mean, 30	19–44 (mean, 34)

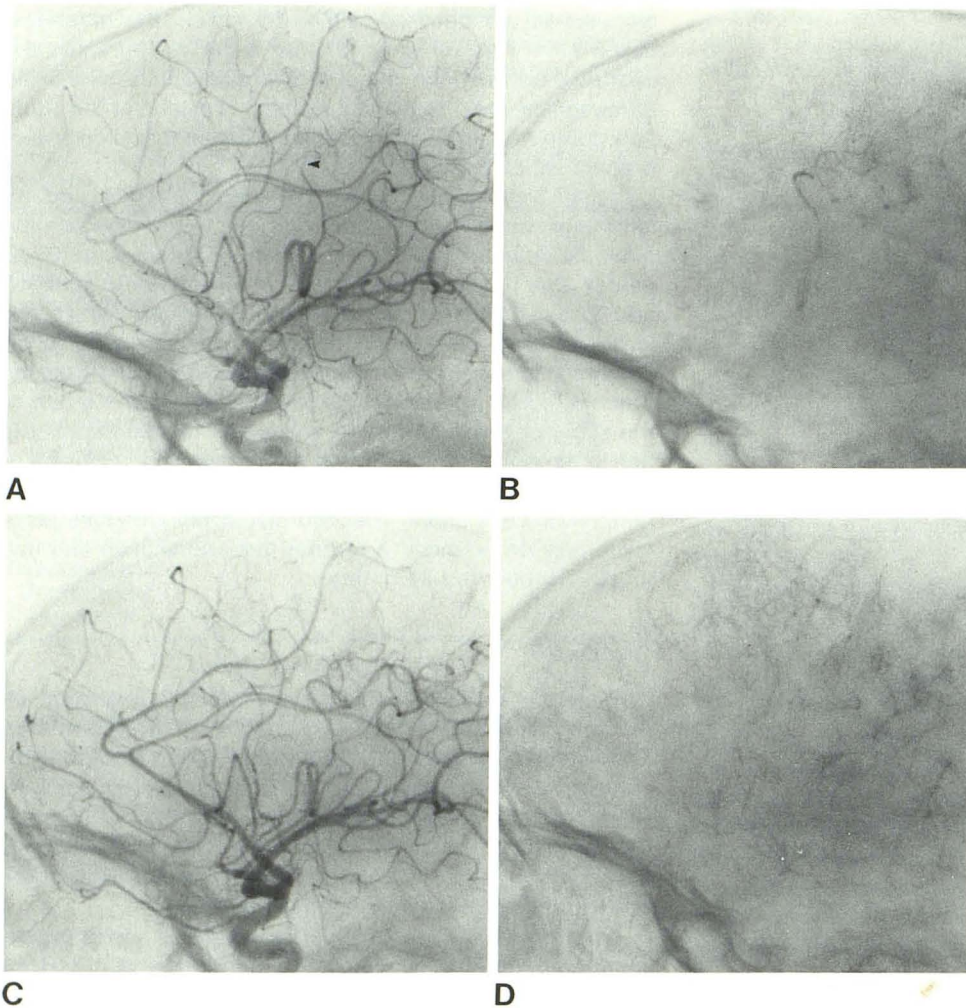


Fig. 1.—Case 9, prompt dissolution of embolus. **A**, Left internal carotid angiogram, first injection. Embolus in central branch of middle cerebral artery (*arrowhead*). **B**, Same series, capillary phase. Circulation is delayed in branches distal to occlusion. **C** and **D**, 10 min later. Embolus has resolved and blood flow is normal.

The clinical symptoms were strikingly mild, much milder than in adult cases on record, in which severe neurologic sequelae [2] and even death [5] have been reported. However, the lack of immediate neurologic symptoms may be partly an illusion due to the general anesthesia; the symptoms may disappear by the time the patients are free from anesthetic effect. The only child observed to have neurologic impairment was examined under local anesthesia and sedation.

But there is also a significant difference between reported adult series and the present series concerning the outcome of the accident. One of the explanations for this may be the hyperventilation with increased oxygen tension within the brain tissues. In many of the present cases the blood flow in the embolized area improved from one angiographic series to the next, performed only a few minutes later, and it is possible the increased oxygen tension induced by the hyperventilation was enough to protect the brain tissues during the period of ischemia. There may also be more rapid development of collateral circulation in children than in adults. In some reports of embolization in adults with manifest hemiparesis and ensuing death, cholesterol-crystal emboli have been revealed at autopsy [5]. In children, most of

the emboli are probably fibrin clots from within the distal catheter that rapidly diminish, as exemplified in figure 1.

From tables 2 and 4 it is clear that there was no direct relation between the frequency of embolization and the size of the patient (and thus also the size of the catheter). Table 4 shows an increased incidence of emboli in the left carotid artery, which is more difficult to catheterize than the right. There is also an increased incidence in the left vertebral artery, which is a vessel easy to catheterize. However, none of these differences in incidence is statistically significant (according to chi-square test), and thus there is no direct relation between the difficulty of catheterization of the vessels and the frequency of embolization, contrary to what has been described in adults [5]. An explanation of this may be that the emboli caused by athermatous plaque do not occur in children.

The mean duration of the angiographic procedure was slightly longer in the complication series than the average within the whole material examined during the study period. The relative incidence of inadvertent embolization was also slightly higher for the less experienced radiologists, as reported in adult series [8]. However these differences, as well as the difference between the incidence of boys and

girls affected, were not statistically significant (according to chi-square test). In our material there was no predilection for a specific disease or signs or symptoms among the patients in which emboli occurred.

Inadvertent embolization during cerebral angiography occurs with about the same frequency in children as in adults. However, the immediate or permanent clinical consequences are much less significant in children. This difference may be partly due to the technique of examination under general anesthesia with hyperventilation, but also to a different pattern of reaction toward ischemia. Moreover, the type of emboli may differ between children and adults.

REFERENCES

1. Cronquist S, Efsing HO, Palacios E. Embolic complications in cerebral angiography with the catheter technique. *Acta Radiol [Diagn] (Stockh)* **1970**;10:97-107
2. Huckman MS, Shenk GT, Neems RL, Tinor T. Transfemoral cerebral arteriography versus direct percutaneous carotid and brachial arteriography: a comparison of complication rates. *Radiology* **1979**;132:93-97
3. Luessenhop AJ, Gibbs M, Velasquez AC. Cerebrovascular response to emboli. *Arch Neurol* **1962**;3:264-272
4. Mani RL, Eisenberg RL, McDonald Jr EJ, Pollock JA, Mani JR. Complications of catheter cerebral angiography: analysis of 5000 procedures. I. Criteria and incidence. *AJR* **1978**;131:861-865
5. Olivecrona H. Complication of cerebral angiography. *Neuroradiology* **1977**;14:175-181
6. Takahasi M, Kamanami H. Complications of catheter cerebral angiography. *Acta Radiol [Diagn] (Stockh)* **1972**;13:248-258
7. Zatz JM, Tonnona AM. Cerebral emboli complicating cerebral angiography. *Acta Radiol [Diagn] (Stockh)* **1966**;5:621-630
8. Mani RL, Eisenberg RL, McDonald Jr EJ, Pollock JA, Mani JR. Complications of catheter cerebral angiography: analysis of 5000 procedures. III. Assessment of arteries injected, contrast medium used, duration of procedure and age of patient. *AJR* **1978**;131:871-874
9. Harwood-Nash DC, Fitz CR. *Neuroradiology in infants and children*. St. Louis: Mosby, **1976**:334-335
10. Mani RL, Eisenberg RL, McDonald Jr EJ, Pollock JA, and Mani JR. Complications of catheter cerebral angiography: analysis of 5000 procedures. II. Relation of complication rates to clinical and arteriographic diagnoses. *AJR* **1978**;131:867-869