

Are your **MRI contrast agents** cost-effective?

Learn more about generic **Gadolinium-Based Contrast Agents**.



FRESENIUS
KABI

caring for life

AJNR

Alcohol Ablation of Symptomatic Vertebral Hemangiomas

Mayank Goyal, Nalin K. Mishra, Aseem Sharma, Shailesh B. Gaikwad, B. K. Mohanty and Sanjiv Sharma

AJNR Am J Neuroradiol 1999, 20 (6) 1091-1096

<http://www.ajnr.org/content/20/6/1091>

This information is current as of April 18, 2024.

Alcohol Ablation of Symptomatic Vertebral Hemangiomas

Mayank Goyal, Nalin K. Mishra, Aseem Sharma, Shailesh B. Gaikwad, B. K. Mohanty, and Sanjiv Sharma

BACKGROUND AND PURPOSE: Many therapeutic techniques have been used for the treatment of symptomatic vertebral hemangiomas (SVH), and each has its own limitations. Our objective was to evaluate the therapeutic efficacy of alcohol ablation for treating these lesions.

METHODS: Fourteen patients with SVH were treated by injection of absolute alcohol into the lesion via the percutaneous transpedicular route under CT guidance. Symptoms before treatment included neurologic deficit in 13 patients and debilitating pain in one. All patients underwent preprocedural MR imaging. All patients had clinical and MR imaging follow-up (14 patients at 48–96 hours and 2 months; six at 9–15 months). Results were divided into excellent (resumption of work, alleviation of pain), good (significant improvement), and failure of treatment categories on the basis of subjective assessment of clinical improvement. Clinical improvement/deterioration was correlated with MR-revealed changes.

RESULTS: All patients showed transient deterioration of neurologic status after alcohol ablation. Subsequently, excellent results were seen in five patients and eight were in the good category. One patient in whom treatment failed also developed a complication (paravertebral abscess). Four of the eight patients with good results had preprocedural cord changes. Total follow-up ranged from 5 to 31 months, with 11 patients showing stable improvement. One patient developed recurrent hemangioma within a month. Another patient became symptomatic after initial good response, secondary to the collapse of the involved vertebral body. Good correlation was found between clinical improvement and reduction of epidural soft-tissue masses on MR images. Cord signal alteration seen on MR images in four treated patients, however, did not show any change after treatment.

CONCLUSION: Alcohol ablation is an effective management option for symptomatic vertebral hemangiomas. Although encouraging results were seen in almost 86% of our patients, a longer follow-up period still is needed to assess the stability of improvement. Potential complications include vertebral collapse and infection.

Vertebral hemangiomas are common, benign vascular tumors of the spine seen in almost 10% of the general population (1). Despite this wide prevalence, they are a rare cause of morbidity, with the majority of lesions remaining asymptomatic. A small percentage of hemangiomas, however, do become symptomatic, and present with back pain or features of neural compression (1–3). The progression of asymptomatic to symptomatic hemangioma

is rare, and was noted in only 3.4% of patients in one series (3).

Symptomatic vertebral hemangiomas (SVH) are difficult to treat, and many therapeutic options, including surgery, radiotherapy, arterial embolization, and injection of methylmethacrylate into hemangiomatous vertebra, have been used for their treatment. We report our experience with treating SVHs by CT-guided percutaneous alcohol injection.

Received in original form July 31, 1998; accepted after revision January 28, 1999.

From the Department of Neuroradiology (M.G., N.K.M., A.S., S.B.G.), Cardiac-radiology (S.S.), and Radiation Oncology (B.K.M.), All India Institute of Medical Sciences, New Delhi 110 029 India.

Address reprint requests to Nalin K. Mishra, MD, Professor and Head, Department of Neuroradiology, All India Institute of Medical Sciences, New Delhi 110 029 India.

© American Society of Neuroradiology

Methods

Fourteen patients with SVH formed this study, and their presenting symptoms are listed in Table 1. All patients underwent MR imaging prior to the procedure not only to confirm the diagnosis and assess the extent of the epidural soft-tissue component of the hemangioma, but also to determine the presence of cord changes, and develop baseline study. The MR scans were performed on a 1.5-T superconducting magnet. Standard T1-weighted spin-echo (450–600/15/3 [TR/TE/NEX]) and T2-weighted fast spin-echo (3800–5000/90/1) im-

TABLE 1: Results of CT-guided alcohol ablation in patients with SVH

| Patient | Age (y)/ Sex | Symptoms | Site | Result | Cord Changes On MR | | Follow-up Duration (months) | Post Procedural Course |
|---------|-----------------|--------------------------------|------|--------|-----------------------|------|-----------------------------------|--|
| | | | | | Pre | Post | | |
| 1 | 35/F | PP | D10 | E | - | - | 31 | Stable |
| 2 | 59/M | PP, constipation | L2 | G | + | + | 11 | Stable |
| 3 | 15/M | Severe pain | L2 | E | - | - | 25 | Stable |
| 4 | 23/M | PP, pain | L3 | G | - | - | 21 | Stable |
| 5 | 35/M | PP, constipation, hesitancy | D7* | G | + | + | 25 | Recurrence 1 m later, patient underwent laminectomy and transarterial embolization, doing well subsequently |
| 6 | 36/M | PP, constipation | L1 | G | + | + | 12 | Stable |
| 7 | 32/M | PP | D6 | E | - | - | 13 | Stable |
| 8 | 45/F | PP | D12 | E | - | - | 23 | Stable |
| 9 | 38/M | PP | D6* | E | - | - | 15 | Stable |
| 10 | 22/F | PP, pain | D12* | F | + | NA | 5 | Procedure abandoned due to contrast extravasation during test injection; patient developed paravertebral abscess and underwent surgery |
| 11 | 28/M | PP | L1 | G | + | + | 12 | Stable |
| 12 | 32/M | PP, pain | D6 | G | - | - | 9 | Patient developed symptomatic vertebral collapse 5 m following procedure, underwent surgery |
| 13 | 30/F | PP | D6 | G | - | - | 8 | Stable |
| 14 | 23/M | PP | L3 | G | - | - | 7 | Stable |

Note.—M, male; F, female; D, dorsal vertebra; L, lumbar vertebra; PP, paraparesis; E, excellent; G, good; F, failure of treatment; Pre, before treatment; Post, after treatment.

* Multiple hemangiomas.

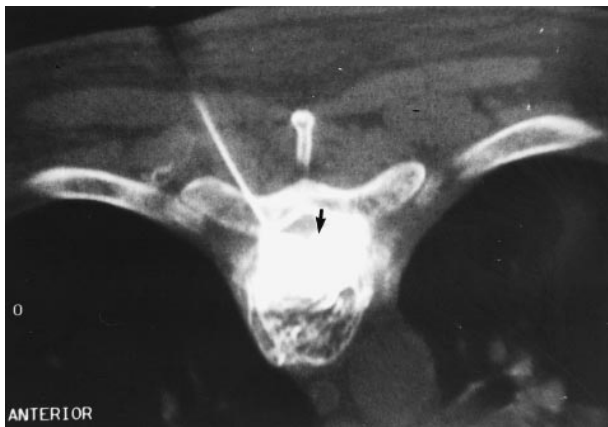

FIG 1. Axial CT scan at the level of the maximal epidural soft-tissue component of the hemangioma taken during injection of contrast medium through the needle positioned into the vertebral body. Note the excellent opacification of the epidural soft tissue on either side of midline (arrow).

ages were taken in the sagittal and axial planes through the region of interest. A whole-spine study also was conducted to look for additional lesions. Diagnosis was based on typical signal characteristics of the lesions on MR images (hyperintensity on both T1- and T2-weighted MR images) in thirteen patients. One patient with atypical characteristics on MR images had undergone CT-guided biopsy of the vertebral lesion for establishing the diagnosis. Indication for intervention was progressive paraparesis in thirteen patients, and severe debilitating pain in one. All patients had extraosseous extension of the hemangioma.

An informed consent was taken from all the patients. The patients were started on oral steroids (prednisone 4–6 mg, 6 hourly) 48 hours prior to the procedure. All patients received 25 mg pentazocine intramuscularly for analgesia during the procedure. The patients were imaged in a prone position on the CT table and CT scanning (4-mm section, 4-mm feed) was

performed through the relevant vertebra in a plane parallel to the end plates. Subsequently, 2-mm sections were taken through the pedicle to choose the safest site for needle placement. Under aseptic conditions, and after giving local anesthesia (Xylocaine 2%), an 18-gauge, 10-cm-long lumbar puncture needle was inserted manually in a direction allowing access to the hemangiomatous cavity through the pedicle.

When the needle was satisfactorily positioned, 8 mL of diluted nonionic iodinated contrast (iohexol 300) was injected slowly through the needle, while CT was performed in the dynamic mode through the area of the maximal epidural soft-tissue hemangiomatous component (Fig 1). This was done to enable visualization of the opacified soft-tissue component, and to exclude extravasation of contrast agent into the retroperitoneal, pleural space, paraspinous muscles, or into a vascular channel. In case the opacification of the extradural soft-tissue component was inadequate or incomplete, a second needle was inserted in the same manner as the first needle through the other pedicle. The procedure was abandoned if there was extravasation (Fig 2).

After a satisfactory test injection, 10–15 mL of absolute alcohol was injected through the needle slowly. The injection, a blind procedure, was continuous, and the rate was based on subjective assessment of the opacification rate as well as clearing of contrast agent from the epidural soft-tissue mass at the time of its injection. Patients were observed in the hospital over the next few days, and were discharged and advised to refrain from heavy lifting. All patients were kept on a regular clinical and MR follow-up schedule. Follow-up MR scans were performed between 48 and 96 hours, and subsequently 2 months after intervention. Depending on clinical follow-up and results of the second MR examination, a third follow-up MR examination was performed between 9 and 15 months.

The success of the procedure was evaluated on the basis of subjective assessment of clinical improvement. Near-complete alleviation of symptoms with resumption of work and activities of daily living was termed an excellent result. Significant improvement in neurologic symptoms was classified as a good result. Presence of a complication, lack of significant improvement, or both was considered failure of treatment.

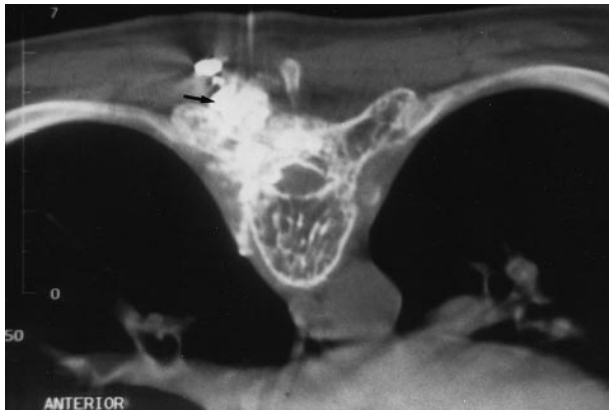

FIG 2. Axial CT scan obtained similarly in another patient shows extravasation of contrast into the paraspinal muscles (arrow) and pleural cavity. The procedure was abandoned at this stage.

Clinical improvement/deterioration was also correlated with the corresponding decrease/increase of an epidural soft-tissue hemangiomatous component on MR imaging. The follow-up MR examinations were evaluated with respect to the appearance/disappearance of cord changes, and changes in the imaging characteristics of the lesion itself. Loss of height of the vertebral body, when present, also was documented.

In patients with failure of treatment, alternative modes of treatment such as surgery or transarterial embolization were performed. None of the patients were subjected to reinjection of alcohol.

Results

The presenting complaints and results of clinical assessment and MR imaging follow-up are summarized in Table 1. The ages of the patients ranged from 15 to 59 years, with a mean of 36.9 years. Ten were men, and four were women. The duration of symptoms at the time of presentation ranged from 2 months to 1 year. Three patients had multiple hemangiomas; however, in all these, only one

of the lesions showed an extradural soft-tissue component. Hence, only one was treated. Eight of the treated lesions were in the dorsal spine, and six were in the lumbar spine.

In five patients, hyperintense signal was observed within the cord on T2-weighted images at the level of the SVH (Fig 3). In six patients, injection of contrast material through the needle satisfactorily opacified the extradural component, whereas insertion of a second needle through the other pedicle was deemed necessary in the other eight. Of these eight, two patients still showed incomplete opacification of the epidural hemangioma. In all but one patient, alcohol was injected in the hemangiomatous cavity inside the vertebral body. In one patient, both needles did not progress beyond the pedicle, and alcohol was injected in the hemangioma within the pedicle itself.

The procedure was abandoned in one patient because of extravasation of contrast material into the pleural cavity and paraspinal muscles. It was planned to reschedule the procedure at a later date; however, the patient developed a large paravertebral abscess that required urgent drainage. As was the practice with all successful procedures, this patient was also not given postprocedural antibiotics.

All patients showed transient neurologic deterioration, in the form of worsening paraparesis, lasting up to 5 days after the procedure. The patients were continued on oral steroids during this time. Subsequently, five patients showed excellent improvement, with near-complete alleviation of symptoms, whereas seven showed significant improvement. The improvement continued for up to 14 months after the procedure. One patient showed significant clinical improvement in the initial 3 weeks, but then deteriorated rapidly. This patient had shown unusual features on MR images, and the

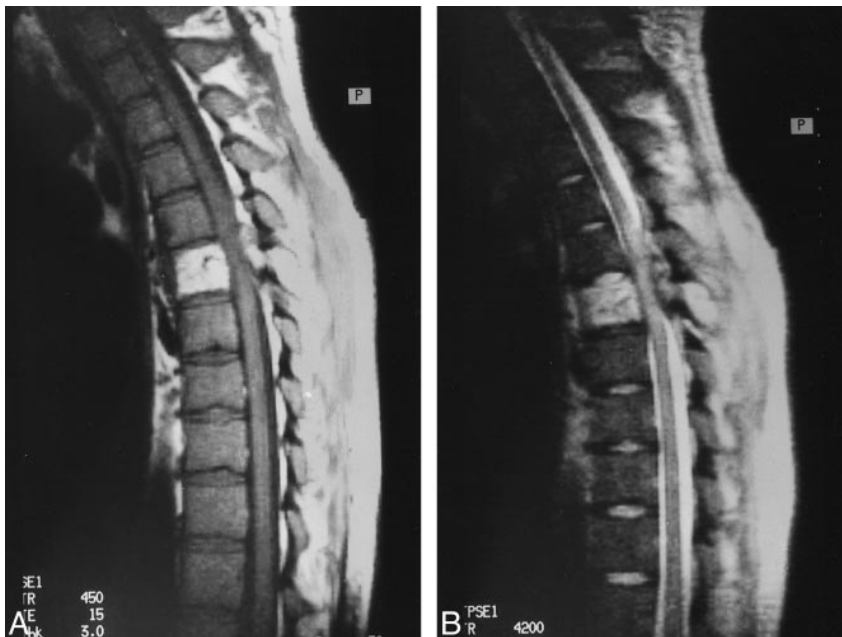

FIG 3. A 35-year old man who presented with paraparesis. T1- (A) (450/15/3, [TR/TE/excitations]) and T2-weighted (B) (4200/90/1) sagittal MR images show a typical hemangioma at midthoracic level. The posterior elements also are involved, and the spinal canal is compromised. Note the presence of hyperintense signal within the spinal cord on the T2-weighted image.

diagnosis of hemangioma was made after biopsy. The patient was subjected to transarterial embolization using Polyvinyl alcohol (Ivalon, Ingenor, France). The procedure was uneventful, and the patient showed significant clinical improvement. In view of the multiplicity of lesions, unusual imaging characteristics, and clinical behavior, the patient was also given low-dose radiotherapy locally. The total clinical follow-up ranged from 5 to 31 months. One patient showed deterioration 5 months after the procedure (after showing good initial response) secondary to collapse of the involved vertebra. MR imaging done in this patient had revealed a vertebral hemangioma involving the entire vertebral body and extending into both the pedicles and into adjacent soft tissue. Alcohol ablation was performed by injecting a total of 30 mL of absolute alcohol into the hemangiomatous cavity, using a bipedicular approach. This patient underwent surgery for relieving the cord compression and for spinal stabilization. Histopathologic analysis revealed evidence of osteonecrosis in the resected bone.

None of the patients showed any appreciable change in MR signal characteristics of the lesions or in the extent of soft-tissue involvement early after the procedure. In the MR examination conducted at 2 months, all 12 patients (the patient with complications and an alternative form of therapy excluded) showed significant reduction in the extradural soft-tissue component (Fig 2). The four patients who had shown cord changes prior to the procedure (one patient with cord changes had a complication and the procedure was abandoned), continued to show these changes after successful treatment, and all had good (not excellent) clinical outcomes. Although there was a reduction in soft-tissue involvement in two patients, there was still obvious compression of the spinal cord. Three patients showed reduction in the signal intensity of the treated lesion on both T1- and T2-weighted images. The remaining nine patients did not show any appreciable change on the follow-up MR images. Follow-up studies revealed loss of height of the involved vertebral body in three of the patients. Of these, only one showed clinical deterioration caused by vertebral-body collapse.

Discussion

Vertebral hemangiomas are not true neoplasms but congenital vascular malformations (3–5). Although they are most often incidental findings on MR images, rarely they may present with back pain or symptoms of neural compression (1–3). On CT, vertebral hemangiomas are seen as lucent areas separated by bony trabeculae (polka dot appearance) (1, 6). Appearance on MR images depends on the fat content of the lesion. The lesions are typically hyperintense on both T1- and T2-weighted sequences (Fig 3). Nonetheless, hemangiomas with atypical appearance on MR images (with hypointensity on T1- and hyperintensity on T2-

weighted images) also are seen (1). These hemangiomas have a more aggressive clinical course, and are more often symptomatic (1, 7). Other imaging features associated with symptomatic vertebral hemangiomas include involvement of posterior elements, breaks in cortical margins, expansion of the vertebral elements, soft-tissue attenuation of the lesion on CT scan, lack of fatty signal on MR images, significant contrast enhancement on CT and MR images, and presence of epidural extension of soft tissue (1, 7). In our experience, all patients showed presence of an epidural soft-tissue mass, and most of the other findings, such as break in cortical margin, were present. In 13 of the 14 patients, the lesions were hyperintense on both T1- and T2-weighted sequences, and the diagnosis was made easily. In only one patient were the lesions hypointense on T1- and hyperintense on T2-weighted images, and a CT-guided biopsy was required to establish the diagnosis.

Therapeutic options available for SVH include surgery, transarterial embolization, radiotherapy, and injection of methylmethacrylate into the hemangiomatous cavity (3, 4, 8). Surgical resection carries with it the risk of profuse hemorrhage, incomplete resection, and prolonged convalescence (3, 9, 10). Recent literature suggests that preoperative percutaneous injection of methyl methacrylate, N-butyl cyanoacrylate, or both into the SVH may be useful (11,12). Nonetheless, the literature is still scant on this point. Transarterial particulate embolization occludes the feeding vessels, but does not destroy the hemangioma, because an intervening capillary bed separates the feeding arteries from the hemangioma (13–17). Spinal cord infarction is a potential complication; additionally, reflux of the particulate material into the intercostal or lumbar arteries is associated with severe pain (17). In cases of residual or recurrent disease, a second attempt often is not possible because feeding arteries have been occluded. Radiotherapy is moderately effective; however, the effects are delayed, which may cause irreversible damage to the spinal cord. Radionecrosis of the spinal cord remains a risk (18–20).

The technique of percutaneous alcohol ablation first was described by Heiss et al (21). They described the results of this procedure initially in two patients with SVH, and 2 years later presented the results of a total of seven patients (22). Our technique was similar to their technique, with minor variations. We attached significance to opacification of the epidural soft tissue during the test injection, and inserted a second needle in case the opacification was inadequate (Fig 1). Heiss et al (21, 22) injected 10 mL of alcohol in increments of 2 mL every 10–15 minutes. In contrast, we injected 10–15 mL of absolute alcohol continuously at a rate subjectively decided by the rate of opacification and clearing of contrast material from the epidural soft tissue, as seen on CT images taken in dynamic mode during the test injection. We felt that

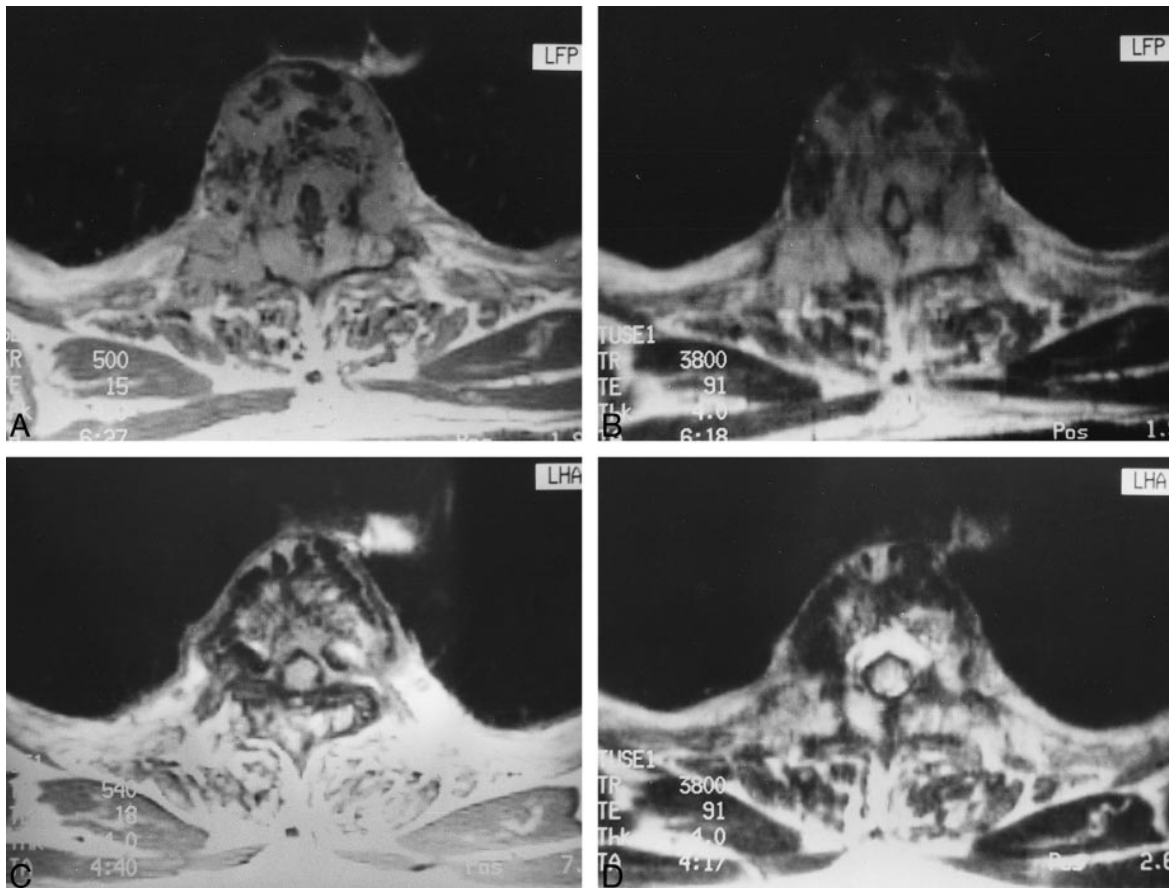


FIG 4. Sequential MR images of a 35-year old woman with SVH who underwent an uneventful alcohol ablation of the lesion. Pre-procedural T1-weighted (A) (500/15/3) and T2-weighted (B) (3800/91/1) axial images at the level of the lesion show the hemangioma with a large epidural soft-tissue component causing compression of the spinal cord. Follow-up T1-weighted (C) (540/18/3) and T2-weighted images (D) (3800/91/1) after an interval of 2 months show a dramatic reduction of soft-tissue hemangiomatous involvement. Note the change in signal in the vertebral-body hemangioma on the follow-up MR images (C and D).

continuous injection of alcohol would lead to better distribution of alcohol in the hemangiomatous cavity, with less chances of obliteration of the hemangioma in the immediate vicinity of the needle tip. For this particular reason, we did not use contrast injection to assess the obliteration of hemangioma, as done by Heiss et al.

Our success rate of 85% is comparable to that achieved by other therapeutic techniques. Using radiotherapy, Yang et al achieved improvement in 72% of patients of symptomatic vertebral hemangiomas who presented with paraplegia (18). Similarly, success rates of 70–90% have been reported in the literature with surgery alone or a combination of surgery and radiotherapy (3). Although the therapeutic efficacy of alcohol ablation in our study appears to be adequate, the duration of follow-up of our patients is too preliminary to assess the long-term results of the procedure.

The complications associated with the procedure included infection and vertebral collapse. None of our patients received antibiotic prophylaxis for the procedure. The only patient who developed infection had shown extravasation of contrast material into the paraspinal tissues, and alcohol was not in-

jected. As nonionic contrast medium itself is an excellent culture medium for microorganisms, we posit that antibiotic prophylaxis should be provided in such patients (23).

Three of our patients showed loss of height of the vertebral body in the follow-up studies. In two of these patients, no clinical symptoms correlated to this imaging finding. Heiss et al (21, 22) have reported symptomatic collapse of the vertebral body in two of their patients at follow-up. Areas of osteonecrosis were reported in one of our patients who underwent surgery after vertebral collapse. Heiss et al also observed this finding in their patients who developed vertebral collapse after alcohol ablation. Vertebral collapse in almost 20% of the patients certainly is a cause for concern. Although we can not conclude that collapse occurred secondary to alcohol ablation, keeping in view the evidence of osteonecrosis in the resected vertebrae, it is possible that alcohol may weaken the vertebral body by causing necrosis in the supporting bony trabeculae. It may be worthwhile to inject methyl methacrylate into the vertebral body by the technique described by Cotten et al (11), when the size of the epidural soft-tissue mass has reduced. The

alteration of the circulation, and hence, the distribution of methyl methacrylate, may pose a problem.

All of our patients showed transient deterioration of neurologic status after the procedure. Neither the literature on alcohol ablation nor on preoperative methyl methacrylate injection has described this. Because all of our patients were given steroids empirically, no conclusion can be drawn on the role of steroids.

After alcohol ablation, the MR signal characteristics of hemangiomas did not change in any consistent pattern. In the majority of our cases, no significant change was noticed in the intensity of hemangiomas. In three cases, the signal intensity of the treated lesion decreases on both T1- and T2-weighted MR images (Fig 4). In all these patients, the changes were not observed on the MR scans obtained within the first few days after treatment. The cause of these changes is unclear, but possibly is related to the fibrosis induced by alcohol. Decrease in the soft-tissue component of the hemangioma was well-delineated on the follow up MR scans (Fig 4). The potential of alcohol injection to shrink hemangiomatous volume is a significant advantage of this form of therapy over methylmethacrylate injection. The latter forms a dense cast of the hemangiomatous cavity, and therefore is unsuitable for treating those lesions presenting because of neural compression produced by the hemangioma (3, 21).

Of the eight patients who had good results at follow-up, four had shown preprocedural spinal cord changes on MR images, which persisted after the procedure. This may signify irreversible cord damage. Of the other four, three are still continuing to show improvement.

We did not have any patient with multiple hemangiomas who required treatment for more than one hemangioma. Our technique appears to be suitable for treating multiple lesions. It should be noted, however, that chances of vertebral collapse may increase if resultant osteonecrosis leads to spinal weakening at two levels.

Conclusion

Significant improvement can be achieved in almost 85% of symptomatic vertebral hemangiomas by using CT-guided alcohol ablation. Nonetheless, the follow-up performed in our study is still too preliminary to draw any conclusions about long-term efficacy. In view of evidence of vertebral collapse in almost 20% of these patients, it may be worthwhile to study the use of methyl methacrylate to strengthen the vertebral body once the soft-tissue hemangiomatous component has been ablated by alcohol.

References

- Colombo N, Berry I, Nieman D. **Vertebral tumors.** In: Meneloff C, ed. *Imaging of Spine and Spinal Cord.* New York, NY: Raven Press; 1992;445-489
- Djindjian M, Nguyen J-P, Gason A, Pavlovitch J-M, Poirier J, Awad IA. **Multiple vertebral hemangiomas with neurological signs: case report.** *J Neurosurg* 1992;76:1025-1028
- Fox MW, Onofrio BM. **The natural history and management of symptomatic and asymptomatic vertebral hemangiomas.** *J Neurosurg* 1993;78:36-45
- Mirra JM. **Vascular tumors.** In: Mirra JM, ed. *Bone Tumors: Clinical, Radiologic, and Pathologic Correlations.* Vol 2. Philadelphia, PA: Lea & Febiger; 1989;1335-1478
- Gray F, Gherardi R, Benhaïem-Sigaux N. **[Vertebral hemangiomas: definitions, boundaries, anatomic-pathologic aspects.]** *Neurochirurgie* 1989;35:267-269
- Gordon Sze. **Neoplastic diseases of the spine and spinal cord.** In: Atlas SW, ed. *Magnetic Resonance Imaging of the Brain and Spine.* 2nd ed. Philadelphia, PA: Lippincott-Raven; 1996;1339-1386
- Laredo JD, Assouline E, Gelbert F, Wybier M, Merland JJ, Tubiana JM. **Vertebral hemangiomas: fat content as a sign of aggressiveness.** *Radiology* 1990;177:467-472
- Jayakumar PN, Vasudev MK, Srikanth SG. **Symptomatic vertebral hemangioma: endovascular treatment of 12 patients.** *Spinal Cord* 1997;35:624-628
- Ryoppy S, Poussa M, Heiskanen O, Leijala M, Peltola K. **Resection of a vertebral hemangioma—operation under deep hypothermia and circulatory arrest.** *J Bone Joint Surg Am* 1990; 72:1245-1249
- Hemmy DC, McGee DM, Amburst FH, Larson SJ. **Resection of vertebral hemangioma after preoperative embolization: case report.** *J Neurosurg* 1977;47:282-285
- Cotten A, Dearmond H, Cortet B, et al. **Preoperative percutaneous injection of methyl methacrylate and N-butyl cyanoacrylate in vertebral hemangiomas.** *AJNR Am J Neuroradiol* 1996; 17:137-142
- Ide C, Gangi A, Rimmelin A, et al. **Vertebral hemangiomas with spinal cord compression: the place of preoperative percutaneous vertebroplasty with methyl methacrylate.** *Neuroradiology* 1996;38:585-589
- Graham JJ, Yang WC. **Vertebral hemangioma with compression fracture and paraparesis treated with preoperative embolization and vertebral resection.** *Spine* 1984;9:97-101
- Hekster REM, Luyendijk W, Tan TI. **Spinal-cord compression caused by vertebral hemangioma relieved by percutaneous catheter embolization.** *Neuroradiology* 1972;3:160-164
- Gross CE, Hodge CH Jr, Binet EF, Kricheff II. **Relief of spinal block during embolization of a vertebral body hemangioma: case report.** *J Neurosurg* 1976;45:327-330
- Smith TP, Koci T, Mehringer CM, et al. **Transarterial embolization of vertebral hemangioma.** *J Vasc Interv Radiol* 1993;4: 681-685
- Picard L, Bracard S, Roland J, Moreno A, Per A. **[Embolization of vertebral hemangiomas: techniques, indications, and results.]** *Neurochirurgie* 1989;35:289-293, 305-308
- Yang ZY, Zhang LJ, Chen ZX, Hu HY. **Hemangioma of the vertebral column: a report of twenty-three patients with special reference to functional recovery after radiation therapy.** *Acta Radiol Oncol* 1985;24:129-132
- Faria SL, Schlupp WR, Chiminazzo H Jr. **Radiotherapy in the treatment of vertebral hemangiomas.** *Int J Radiat Oncol Biol Phys* 1985;11:387-390
- Eisenstein S, Spiro F, Browde S, Allen CM, Grobler L. **The treatment of a symptomatic vertebral hemangioma by radiotherapy.** *Spine* 1986;11:640-642
- Heiss JD, Doppman JL, Oldfield EH. **Brief report: relief of spinal cord compression from vertebral hemangiomas by intralesional injection of absolute ethanol.** *N Engl J Med* 1994;331: 508-511
- Heiss JD, Doppman JL, Oldfield EH. **Treatment of vertebral hemangioma by intra-lesional injection of absolute ethanol: letter.** *N Engl J Med* 1996;334:1340
- Dawson P, Becker A, Holton JM. **The effect of contrast media on the growth of bacteria.** *Brit J Radiol* 1983;56:809-815