

Are your **MRI contrast agents** cost-effective?

Learn more about generic **Gadolinium-Based Contrast Agents**.



FRESENIUS
KABI

caring for life

AJNR

MR Characteristics of Muslin-Induced Optic Neuropathy: Report of Two Cases and Review of the Literature

M. Tariq Bhatti, Chad A. Holder, Nancy J. Newman and Patricia A. Hudgins

This information is current as of April 18, 2024.

AJNR Am J Neuroradiol 2000, 21 (2) 346-352
<http://www.ajnr.org/content/21/2/346>

Case Report

MR Characteristics of Muslin-Induced Optic Neuropathy: Report of Two Cases and Review of the Literature

M. Tariq Bhatti, Chad A. Holder, Nancy J. Newman, and Patricia A. Hudgins

Summary: Muslin-induced optic neuropathy is a rarely reported but important cause of delayed visual loss after repair of intracranial aneurysms. Most of the previously reported cases were published before the introduction of MR imaging. We describe the clinical features and MR appearance of two cases of delayed visual loss due to “muslinoma,” and compare them with the 21 cases reported in the literature.

An accepted neurosurgical alternative for the repair of nonclippable intracranial aneurysms is reinforcement of the aneurysm wall with a variety of materials, including muslin (cotton gauze) (1–5). Although in many cases the aneurysm is successfully stabilized, in rare cases an excessive inflammatory reaction can lead to functional compromise of adjacent structures (6–18). The occurrence of an optic neuropathy or chiasmal syndrome in this setting has been described by a variety of terms, including muslin-induced optochiasmatic arachnoiditis, gauze granuloma, gauzoma, and muslinoma. Although 21 cases of muslin-associated optic neuropathy have been reported, the MR imaging characteristics were noted in only four articles, of which two included contrast-enhanced MR images and none described follow-up imaging (8, 11, 13, 15) (Table 1). Because only one case was published in the radiologic literature (8), many radiologists may not be familiar with this diagnosis. All previously reported cases occurred within 24 months of muslin wrapping. We describe two patients with delayed visual loss due to muslinoma who presented 54 and 48 months, respectively, after repair of paraophthalmic artery aneurysms with muslin wrapping and correlate the neuroimaging findings

with clinical outcome. One patient had follow-up MR imaging.

Case Reports

Neuro-ophthalmologic evaluation and MR imaging were performed in two patients who presented with delayed visual loss after muslin wrapping of unclippable intracranial aneurysms. Clinical evaluation was performed by two experienced neuro-ophthalmologists. MR imaging consisted of sagittal T1-weighted spin-echo (SE) (500/13/2 [TR/TE/excitations]) sequences, axial T2-weighted gradient and spin-echo (GRASE) (5000/100/3) sequences, and axial fluid-attenuated inversion-recovery (FLAIR) (7000–8000/120–130/1–2, TI = 2200) whole brain images, followed by 3-mm-thick axial and coronal T1-weighted SE (450–500/13–20/2) images through the orbits and sella before and after intravenous administration of gadolinium chelate, including fat-suppressed images. On the basis of the clinical and imaging findings, one patient received no specific treatment and the other was treated with a course of corticosteroids. Both patients had serial visual field testing. One patient had follow-up MR imaging. Since the decision was made to treat both patients conservatively, the diagnosis of muslinoma was based on the imaging findings and on the subsequent clinical course.

The 21 previously reported cases of muslin-associated optic neuropathy were reviewed to determine the time interval to presentation, the sex of the patient, the imaging technique used and the findings (in particular whether a mass was present), the treatment and the response to treatment, and the final clinical outcome. Complete information was not available in all cases. Five cases of intracranial muslinoma were excluded from this analysis owing to absence of optic neuropathy, although they are included for completeness in Table 1.

Case 1

A 33-year-old woman had sudden onset of a severe headache and vomiting. A CT study revealed subarachnoid and intracerebral hemorrhage. A four-vessel cerebral angiogram showed a right supraclinoid internal carotid artery (ICA) aneurysm distal to the origin of the ophthalmic artery. A frontal craniotomy was performed and after removal of the anterior clinoid process, the aneurysm was thought to be surgically unclippable; therefore, the aneurysm was wrapped with muslin and coated with cyanoacrylate glue. Coil embolization of the aneurysm was subsequently performed, and success was confirmed by postoperative angiography.

The patient did well for 4½ years, when she noticed an inferior visual field defect in the right eye associated with pain with eye movement. Neuro-ophthalmologic examination revealed a visual acuity of 20/25 in each eye. There was a 1.5 log unit right relative afferent pupillary defect (RAPD); a quantitative clinical measure of optic nerve function), indicating right optic nerve dysfunction. The optic nerves appeared normal on funduscopy examination. The right visual field showed

Received November 9, 1998; accepted after revision August 30, 1999.

From the Departments of Ophthalmology (M.T.B., N.J.N.), Radiology (C.A.H., P.A.H.), Neurology (N.J.N.), and Neurosurgery (N.J.N.), Emory University School of Medicine, Atlanta, GA.

Supported in part by a departmental grant (ophthalmology) from Research to Prevent Blindness, New York, NY, and by NIH CORE grant #P30-EYO 6360.

Address reprint requests to Chad A. Holder, MD, Department of Radiology/Neuroradiology/B-115, Emory University School of Medicine, 1364 Clifton Rd, NE, Atlanta, GA 30322.

Table 1: Muslinoma: summary characteristics of visual and nonvisual deficits

References	Delay from Surgery to Onset of Symptoms (mo)	Sex	Optic Neuropathy	Treatment: Outcome	Imaging Technique	Mass
Carney and Oatey (6)						
Case 1	7	F	Y	None: improved	CT	N
Case 2	1	F	Y	None: improved	CT	N
Case 3	1	F	Y	None: improved	CT	N
Repka et al (16)	2	F	Y	Steroids (2X): improved; surgery: improved	CT	Y
Tomsak (17)	24	F	Y	Steroids (2X): improved; surgery and steroids: stabilized	CT	N
Marcus et al (12)	4	F	Y	Steroids: worsened; surgery and steroids: worsened; cyclophosphamide: improved	CT	N
Chambi et al (7)						
Case 1	10	F	Y	Surgery: worsened	CT	Y
Case 2	6	F	Y	None: improved	CT	Y
Case 3	16	F	N (CN III)	None: improved	CT	Y
Case 4	1	F	N	Abx and antiseizure: improved	CT	Y
Case 5	17	F	N	Abx: improved	CT	Y
Case 6	3	F	Y	None: stabilized	CT	Y
Haisa et al (9)	18	F	Y	Surgery and steroids: stabilized	CT	Y
McFadzean et al (13)						
Cases 1–5	*	M (n = 2) F (n = 3)	Y (n = 5) N (CN III)	Steroids: improved (n = 3), worsened (n = 1)* Surgery and steroids (n = 1)*	CT (n = 3) MR (n = 2)	N (n = 5)*
Onoue et al (14)	5	F	N (CN III)	Surgery: improved	CT	Y
Felsberg et al (8)	6	F	Y	Surgery: improved	CT and MR	Y
Prabhu et al (15)						
Case 1	4	F	Y	Steroids: stabilized	MR	Y
Case 2	3	F	Y	None: stabilized	CT	N
Kirrollos et al (10)						
Case 1	18	F	Y	Surgery: stabilized	CT	Y
Case 2	24	F	Y	Surgery: worsened	CT	Y
Lee et al (11)	24	F	Y	Surgery and steroids: improved then worsened	CT and MR	Y
Vishteh et al (18)	8	M	N	Surgery:*	MR	Y
Bhatti et al (present article)						
Case 1	54	F	Y	None: improved	MR	Y
Case 2	48	F	Y	Steroids: improved	MR	Y

Note.—Abx indicates antibiotics; NA, not available; None, no treatment.

* Limited information.

a dense inferonasal defect (Fig 1A–C). Westergren erythrocyte sedimentation rate, angiotensin converting enzyme, syphilis serology, and antinuclear antibodies were all negative or normal.

MR imaging revealed an enhancing mass at the right supraclinoid ICA, in the region of the coiled aneurysm (Fig 1D–H). The mass was somewhat lobulated but fairly well circumscribed, and showed predominantly solid enhancement surrounding a central nonenhancing hypointense area, representing the coiled and wrapped aneurysm. A small amount of magnetic susceptibility artifact was present as a result of the coils. On the T2-weighted GRASE and FLAIR images, the mass was predominantly hypointense, with surrounding T2 hyperintensity in the adjacent brain parenchyma, consistent with vasogenic edema. A cerebral angiogram revealed coil packing with no residual aneurysmal filling (not shown). No treatment was recommended. Subsequently, the pain with eye movement resolved and the patient reported subjective improvement of her vision. Approximately 3 weeks later, visual acuity was 20/15 in the right eye and 20/20 in the left eye, with a 0.6 log unit right RAPD (indicating significant improvement) and subtle temporal pallor of the right optic nerve. The right visual

field showed a less dense inferonasal defect (Fig 1B). Three weeks later, visual acuity was 20/20 in both eyes with a 0.6 log unit right RAPD. The right visual field showed only a small inferonasal defect (Fig 1C).

Case 2

A 63-year-old woman was incidentally found to have a 7- to 8-mm left supraclinoid ICA aneurysm arising near the origin of the ophthalmic artery on an angiogram obtained to evaluate a right carotid bruit. At craniotomy, the aneurysm was discovered to be partially within the cavernous sinus and was thought to be surgically unclippable; therefore, it was wrapped with muslin.

Four years later, the patient noticed a gradual, painless decrease in vision in the left eye, which progressed over 8 months. Neuro-ophthalmologic examination revealed a visual acuity of 20/20 in the right eye and hand motions in the left eye, with a 0.6 log unit left RAPD, indicating left optic nerve dysfunction. The right optic nerve was normal, and there was

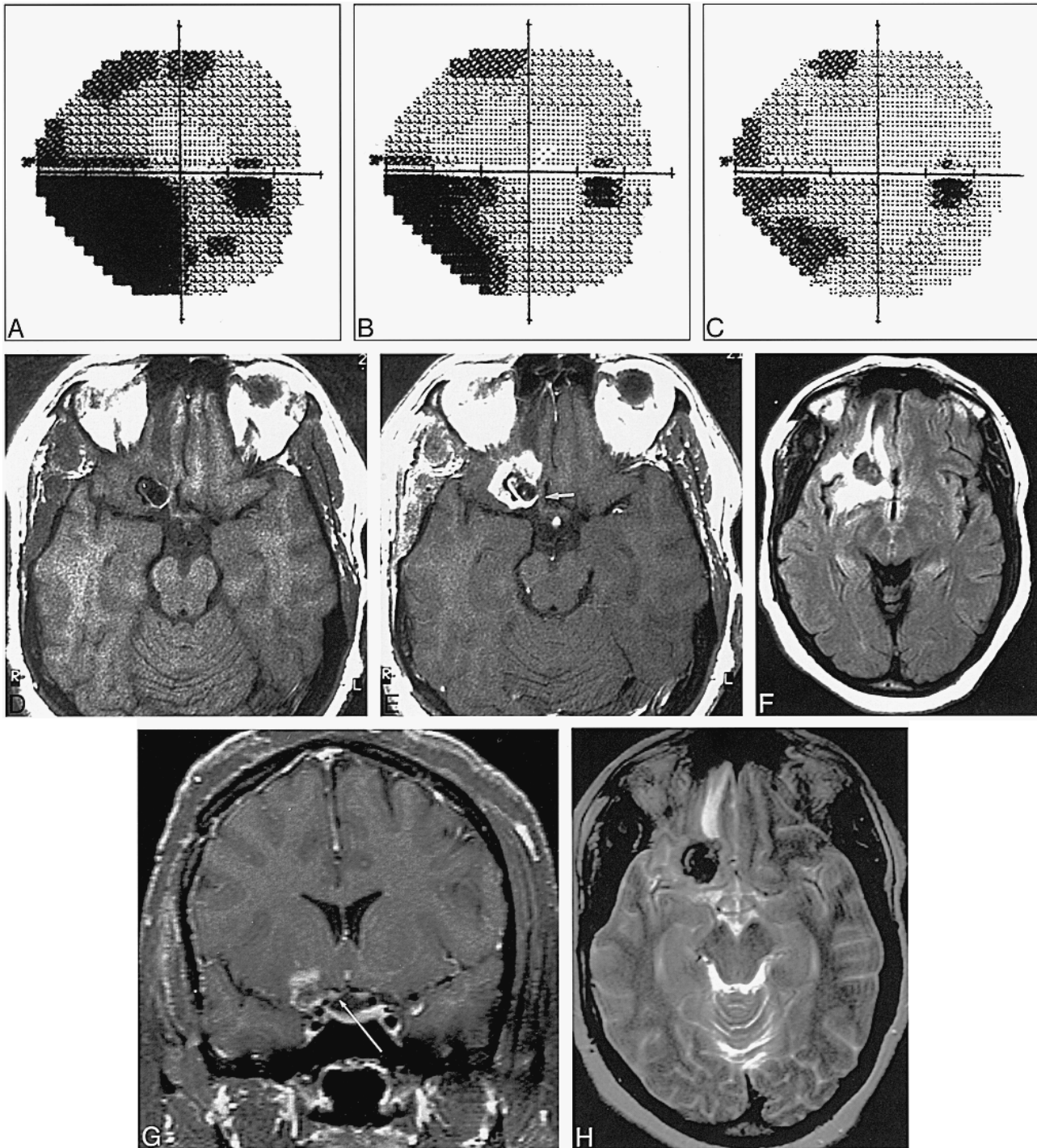


FIG 1. Case 1: 33-year-old woman with sudden onset of severe headache and vomiting.
 A, Right visual field at time of presentation shows a right inferior nasal field defect that is complete (dark black region).
 B and C, Right visual field 3 weeks (B) and 6 weeks (C) later shows spontaneous progressive improvement of the right inferonasal field defect.
 D and E, Noncontrast (D) and contrast-enhanced (E) axial T1-weighted SE images (450/20/2) show an enhancing inflammatory mass surrounding the previously coiled aneurysm. Note the adjacent right optic nerve (arrow, E).
 F, Axial FLAIR image (8000/120/2, TI = 2200) shows increased signal intensity, consistent with edema, in the adjacent brain parenchyma.
 G, Coronal T1-weighted SE image with fat suppression after IV administration of contrast material shows marked enhancement adjacent to the right optic nerve (arrow). Apparent hyperintensity of both optic nerves represents artifact related to technique, not enhancement, as other images showed no enhancement.
 H, Axial T2-weighted GRASE image (5000/100/3) shows the mass to be relatively uniformly and solidly hypointense rather than predominantly hyperintense with a hypointense rim, as would be expected with an abscess.

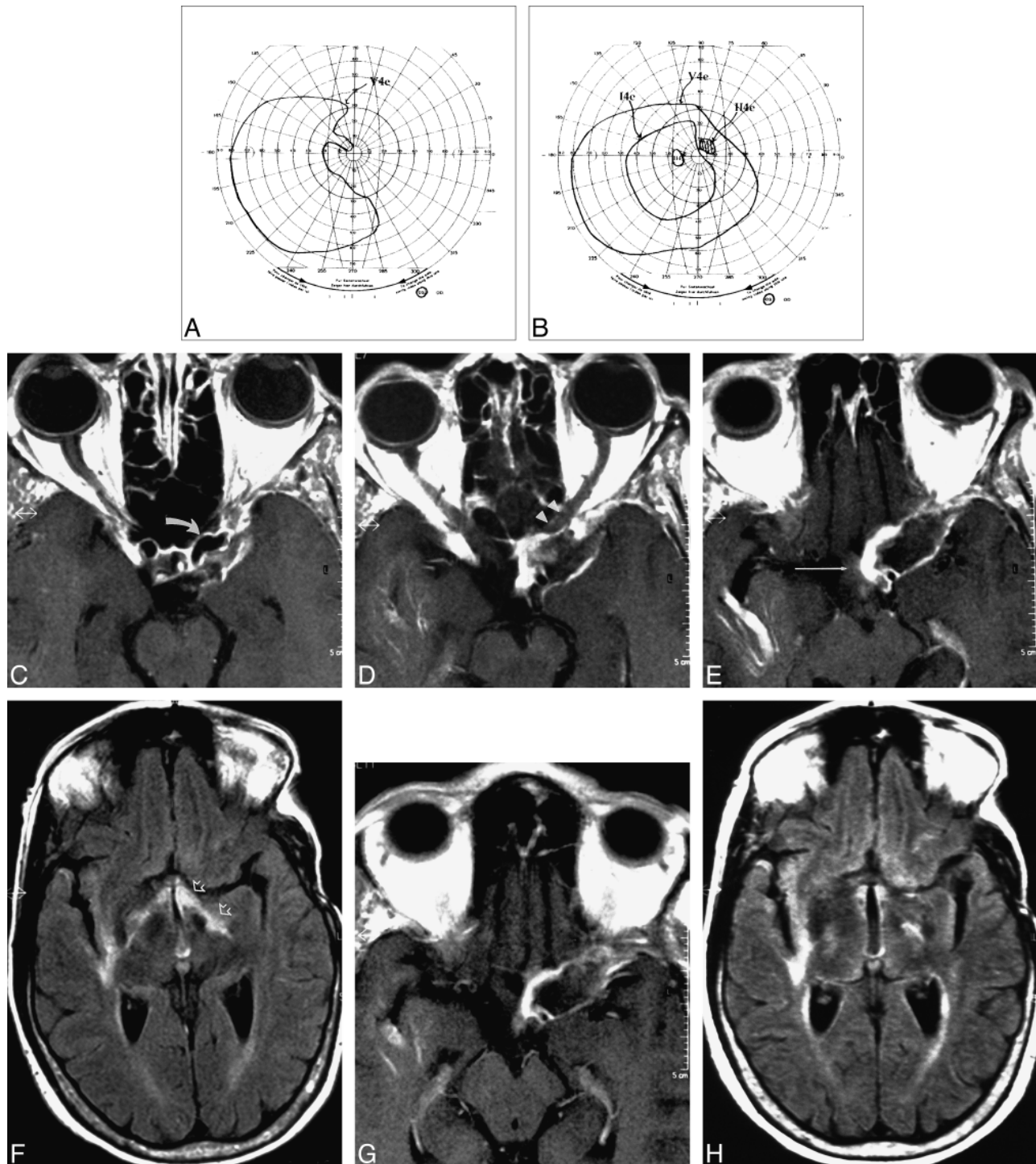


FIG 2. Case 2: 63-year-old woman with 7- to 8-mm left supraclinoid ICA aneurysm near origin of ophthalmic artery.

A, Left visual field at time of presentation shows a large nasal scotoma.

B, Left visual field approximately 2 months later (after 7 weeks of corticosteroid treatment) shows significant improvement, with a smaller nasal defect and a paracentral scotoma.

C–E, Contiguous contrast-enhanced axial T1-weighted SE (450/13/2) images show a flow void within the aneurysm (arrow, C) and a surrounding enhancing inflammatory mass that abuts the left optic nerve (arrowheads, D), chiasm (arrow, E), and tract. Note the incidental finding of a developmental venous anomaly in the right temporal lobe.

F, Axial FLAIR image (7000/130, TI = 2200) shows high signal intensity, consistent with edema, in the optic tracts, left greater than right (arrows). Increased signal intensity in the right subinsular region represents chronic microvascular ischemic changes, unrelated to the aneurysm.

G and H, Follow-up MR images 7 weeks later, after corticosteroid treatment. Contrast-enhanced axial T1-weighted SE image (G) shows a persistent enhancing mass, unchanged in size and still involving the left optic pathways. Axial FLAIR image (H) shows mild improvement in edema in the left optic tract.

diffuse pallor of the left optic nerve. The left visual field showed a large nasal scotoma involving fixation (Fig 2A and B).

MR imaging and MR angiography at this time showed a rim-enhancing mass in the left paraclinoid region (Fig 2C–F). A persistent flow void was noted within the wrapped aneurysm, located at the inferomedial aspect of the lesion. The mass was heterogeneously hypointense on T2-weighted GRASE images, with some areas of iso- and hyperintensity, but without a fluid collection to suggest an abscess. Compared with case 1, the enhancement was more peripheral and thinner, with a larger internal nonenhancing region. The enhancement was thickest medially, adjacent to the wrapped aneurysm. On T2-weighted GRASE and FLAIR images, hyperintensity was present in the optic chiasm and optic tracts, left greater than right, consistent with vasogenic edema. Otherwise, there was no surrounding parenchymal signal abnormality in the adjacent left frontal and temporal lobes, unlike case 1. Oral corticosteroids were instituted. On follow-up examination 2 months later, visual acuity was 20/25 in the right eye and 20/40 in the left eye, with a 0.3 log unit left RAPD. The left visual field showed significant improvement, with a smaller nasal defect and a paracentral scotoma (Fig 2B). A repeat MR examination continued to show a perianeurysmal enhancing lesion (Fig 2G and H), without significant change, despite the patient's significant clinical improvement.

Discussion

In certain situations, an intracranial aneurysm is not considered amenable to conventional surgical clipping, either because of its location or its anatomic configuration. An accepted alternative is reinforcement of the aneurysm wall by wrapping or coating it. A variety of materials have been suggested and used for this purpose, with varying success (1–3). Muslin has gained favor by some, and has been shown in experimental animal models to produce a dense, fibrotic scar, thereby strengthening the blood vessel wall (4). Sadasivan et al (5) concluded that cotton was the most suitable material for wrapping an aneurysm. Unfortunately, in some cases, the local fibrotic reaction created by muslin can extend beyond its intended location. This exuberant inflammatory response can lead to severe systemic and neurologic complications, including lethargy, fever, chills, headaches, seizures, visual disturbances, and hypothalamic-pituitary axis dysfunction (6, 7, 10).

Including our two cases, 23 cases of muslin-induced optic neuropathy have been reported in the literature. These cases are approximately evenly divided between those showing a mass (muslinoma) on cranial imaging studies (n = 12) and those with no mass (n = 11). In the absence of a discrete mass, the term optochiasmatic arachnoiditis may be applied. It is likely that these entities represent a spectrum of manifestations of the same process: a foreign body inflammatory reaction that may or may not become exuberant enough to form a mass identifiable at imaging. Because most of the previously reported patients only had CT studies, many with early-generation scanners, it is possible that this underestimates the number of cases that might have been found to have a mass had MR imaging been available.

Table 2: Summary of final treatment outcome of muslin-induced visual loss (23 cases)

Treatment	Outcome			
	Improved	Stabilized	Worsened	Unknown
None (n = 7)	5	2	0	...
Steroids only (n = 6)	4	1	1	...
Surgery only (n = 4)	1	1	2	...
Both (n = 6)	2*†	2‡	1§	1

* Repka et al (16): Successful initial response to steroids.

† Marcus et al (12): Final treatment with cyclophosphamide.

‡ Tomsak (17): Successful initial response to steroids.

§ Lee et al (11): Initial response to steroids with no subsequent benefit.

The histologic characteristics studied in selected cases share similar features: acute and chronic inflammatory cells, foreign body giant cells, and birefringent material surrounded by a fibrotic capsule (abscess) (7–11, 14). Only one case had positive findings at microbiological examination, yielding *Staphylococcus epidermidis* (10). Intraoperatively, a discrete mass with adhesive bands firmly adherent to adjacent structures has been observed in cases of muslinoma (7, 9, 11, 16).

The pathophysiological mechanism of visual loss remains speculative. Repka et al (16) believed that a combination of ischemia, compression, and inflammation contributed to the visual loss. Carney and Oatey (6) proposed that occlusion of small blood vessels by the inflammatory reaction caused ischemia to the optic nerve. McFadzean et al (13) concluded that the inflammatory response behaved as a space-occupying lesion, leading to compression. Marcus et al (12) described a case of optochiasmatic arachnoiditis that responded to cyclophosphamide and suggested a local Wegener's-like vasculitic process.

The natural history of muslinoma is unknown (Table 2). Spontaneous improvement, as in our first case, has been noted, but the likelihood is difficult to determine owing to the paucity of reported cases. In all three cases of optochiasmatic arachnoiditis reported by Carney and Oatey (6), symptoms spontaneously resolved or improved. Similarly, Chambi et al (7) identified two of seven cases with spontaneous improvement. Given the possibility of a multifactorial process that may be self-limited in certain individuals, the success rate of treatment is equally difficult to determine. Surgical exploration and lysis of adhesions, corticosteroids/immunosuppressants, antibiotics, and conservative observation have all been attempted with varying results (6–17). Visual symptoms have improved after corticosteroid administration in some cases (11, 13, 16, 17), but might have improved without them. In other cases, steroids were ineffective (9, 12, 15). In one patient, who initially responded to steroids, there was no improvement with subsequent retreatment (11), whereas in two other cases, recurrence after tapering of steroids was successfully treated

(16, 17). As for surgical intervention, results are varied, with symptomatic improvement reported in three cases (8, 11, 16), no significant improvement reported in three cases (9, 10, 11), and worsening of symptoms reported in two cases (10, 12).

One of the major clinical challenges is the recognition of muslin-induced optic neuropathy as the antecedent of delayed visual loss. Most cases in the literature were identified on CT studies (6, 7, 9, 10, 14, 16, 17). Frequently, the CT findings are normal (6, 12, 15) or become abnormal during the subsequent clinical course (7, 16). An enhancing space-occupying mass with areas of hypodensity may be evident. There are no pathognomonic CT features, emphasizing the difficulty of differentiating postsurgical changes from other causes of abnormal enhancing lesions, such as abscess (19).

Previous reports of the MR imaging appearance of muslin-induced optic neuropathy are limited, and none have included follow-up MR studies (8, 11, 13, 15). An irregular enhancing mass with areas of possible fluid accumulation at the site of previous aneurysm surgery has been documented. In one case, there was thickening of the optic chiasm (13).

Both our patients had a fairly well-defined mass with thick, irregular, peripheral enhancement, consistent with an active inflammatory process. The degree of enhancement was beyond the expected normal postoperative radiologic changes. There was also surrounding increased signal intensity on T2-weighted and FLAIR images, consistent with edema. The adjacent affected visual structures were clearly identifiable (Figs 1D–H and 2G and H). The differential diagnosis consisted of muslinoma versus abscess, with the elicited history of aneurysmal wrapping being critical for the proper diagnosis. In both cases, although abscess could not be entirely excluded, there were clinical and imaging features that made abscess less likely. In case 1, the enhancement was more solid than ringlike; in case 2, there was less edema than would be expected for an abscess. In both cases, but particularly in case 1, the hypointensity of the mass on T2-weighted images was atypical for abscess. In addition, neither of our patients was febrile. For these reasons, the decision was made to treat these lesions as muslinomas, rather than with antibiotics and/or surgical intervention. Although vision improved in both patients, the follow-up MR study performed in case 2 did not show the expected change in appearance of the enhancing mass, and continued to show an enhancing inflammatory mass, unchanged in size. However, the increased T2 signal intensity in the optic chiasm and left optic tract, consistent with edema, did improve on follow-up. This case demonstrates that significant clinical improvement may occur despite the lack of any dramatic change in neuroimaging findings.

Several unique features were present in our two cases of muslinoma. First, the acute presentation of a painful optic neuropathy in case 1 was reminiscent of an inflammatory process and mimicked an

acute retrobulbar optic neuritis. Second, the period of time from surgical repair of the aneurysm to initial presentation in both cases (54 months and 48 months, respectively) was longer than that in any other previously reported case. Finally, the lack of significant neuroimaging improvement after successful corticosteroid treatment in case 2 suggests that the clinical outcome may not directly correlate with the radiologic appearance. The significance of the fact that the vast majority (over 90%) of reported cases have been in women is unknown, but may reflect an autoimmune pathophysiology.

Conclusion

In a patient with a history of craniotomy who presents with optic neuropathy and an enhancing intracranial mass in the region of the surgical site, muslinoma should be considered in the differential diagnosis, even beyond the 2-year window during which all previously reported cases have presented. We believe that relatively solid hypointensity on T2-weighted images, if present, is helpful for distinguishing muslinoma from abscess. Careful clinical and neuroimaging follow-up is required in patients with muslin-induced optic neuropathy to better elucidate the natural history of the disease process and aid in the diagnosis and management of future cases.

References

- Cossu M, Pau A, Turtas S, Viola C, Viale GL. **Subsequent bleeding from ruptured intracranial aneurysms treated by wrapping or coating: a review of the long term results in 47 cases.** *Neurosurgery* 1993;32:344–347
- Mount LA, Antunes JL. **Results of treatment of intracranial aneurysms by wrapping and coating.** *J Neurosurg* 1975;42:189–193
- Pool JL. **Muslin gauze in intracranial vascular surgery.** *J Neurosurg* 1976;44:127–128
- Sachs E. **The fate of muscle and cotton wrapped about intracranial carotid arteries and aneurysms: a laboratory and clinicopathological study.** *Acta Neurochir* 1972;26:121–137
- Sadasivan B, Ma S, Dujovny M, Ho KL, Ausman JI. **Use of experimental aneurysms to evaluate wrapping materials.** *Surg Neurol* 1990;34:3–7
- Carney PG, Oatey PE. **Muslin wrapping of aneurysms and delayed visual failure: a report of three cases.** *J Clin Neuroophthalmol* 1983;3:91–96
- Chambi I, Tasker RR, Gentili F, et al. **Gauze-induced granuloma (“gauzoma”): an uncommon complication of gauze reinforcement of berry aneurysms.** *J Neurosurg* 1990;72:163–170
- Felsberg GJ, Tien RD, Haplea S, Osumi AK. **Muslin-induced optic arachnoiditis (“gauzoma”): findings of CT and MR.** *J Comput Assist Tomogr* 1993;17:485–487
- Haisa T, Matsumiya K, Yoshimasu N, Kuribayashi N. **Foreign-body granuloma as a complication of wrapping and coating an intracranial aneurysm.** *J Neurosurg* 1990;72:292–294
- Kirillos RW, Tyagi AK, Marks PV, van Hille PT. **Muslin induced granuloma following wrapping of intracranial aneurysms: the role of infection as an additional precipitating factor, report of two cases and review of the literature.** *Acta Neurochir (Wein)* 1997;139:411–415
- Lee AG, Cech DA, Rose JE, Goodman JC, Haykal HA. **Recurrent visual loss due to muslin-induced optochiasmatic arachnoiditis.** *Neuroophthalmology* 1997;18:199–204
- Marcus AO, Demakas JJ, Ross HA, Duick DS, Crowell RM. **Optochiasmatic arachnoiditis with treatment by surgical lysis of adhesions, corticosteroids and cyclophosphamide: report of a case.** *Neurosurgery* 1986;19:101–103

13. McFadzean RM, Hadley DM, McIlwaine GG. **Optochiasmal arachnoiditis following muslin wrapping of ruptured anterior communicating artery aneurysms.** *J Neurosurg* 1991;75:393-396
14. Onoue H, Abe T, Tashibu K, Suzuki T. **Two undesirable results of wrapping of an intracranial aneurysm.** *Neurosurg Rev* 1992; 15:307-309
15. Prabhu SS, Keogh AJ, Parekh HC, Perera S. **Optochiasmal arachnoiditis induced by muslin wrapping of intracranial aneurysms: a report of two cases and a review of the literature.** *Br J Neurosurg* 1994;8:471-476
16. Repka MX, Miller NR, Penix JO, Trant JH. **Optic neuropathy from the use of intracranial muslin.** *J Clin Neuroophthalmol* 1984;4:147-150
17. Tomsak RL. **Muslin optic neuropathy (letter).** *J Clin Neuroophthalmol* 1985;5:71
18. Vishteh AG, Apostolides PJ, Dean B, Spetzler RF. **Magnetic resonance image of postcraniotomy retained cotton or rayon.** *J Neurosurg* 1998;88:928
19. Epstein AJ, Russell EJ, Berlin L, et al. **Suture granuloma: an unusual cause of an enhancing ring lesion in the postoperative brain.** *J Comput Assist Tomogr* 1982;6:815-817