

Are your **MRI contrast agents** cost-effective?

Learn more about generic **Gadolinium-Based Contrast Agents**.



FRESENIUS
KABI

caring for life

AJNR

Intraoperative Sonographic Assessment of Graft Patency during Extracranial-intracranial Bypass

Behnam Badie, Fred T. Lee Jr., Myron A. Pozniak and Charles M. Strother

AJNR Am J Neuroradiol 2000, 21 (8) 1457-1459

<http://www.ajnr.org/content/21/8/1457>

This information is current as of April 18, 2024.

Intraoperative Sonographic Assessment of Graft Patency during Extracranial-intracranial Bypass

Behnam Badie, Fred T. Lee, Jr., Myron A. Pozniak, and Charles M. Strother

Summary: Extracranial-intracranial (EC-IC) bypass may be necessary to facilitate treatment of unclippable posterior circulation fusiform aneurysms. Although intraoperative digital subtraction angiography (DSA) allows assessment of graft patency, this technique, because of difficulties inherent in performing selective catheterization and angiography in the operating room, has limitations. Duplex sonography, in contrast, is easily performed, and provides information regarding graft patency and blood flow direction during EC-IC bypass procedures. This latter information proved useful in determining the time of parent artery occlusion after two EC-IC bypass procedures performed for treatment of a fusiform midbasilar artery aneurysm.

Successful endovascular treatment of patients with an unclippable aneurysms and poor collateral circulation may be facilitated by the creation of an extracranial-intracranial (EC-IC) bypass. Because direct inspection of the graft is not a reliable predictor of graft patency, intraoperative digital subtraction angiography (DSA) is often used for assessment. Because of constraints inherent to performing DSA in the operating room environment (patient's position, difficulty in performing selective arterial catheterizations, and limited ability to achieve visualization of small and complex vascular structures lying deep in the operative field), adequate angiographic examination may be impossible. The use of duplex sonography offers an alternative method for evaluating graft patency and hemodynamics. Although this technique is often used to assess vessel patency during clipping of aneurysms or EC-IC bypass procedures, its value in determining the timing of parent artery occlusion after EC-IC bypass for treatment of fusiform aneurysms has not been reported (1).

Case Report

A 38-year-old man developed acute headaches, dysarthria, left hearing loss, and right hemiparesis. CT, MR imaging, and

Received January 26, 2000; accepted after revision March 10.

From the Departments of Neurological Surgery (B.B.) and Radiology (F.T.L., M.A.P., C.M.S.), University of Wisconsin School of Medicine, Madison, WI.

Address reprint requests to Behnam Badie, MD, H4/330 Clinical Science Center Department of Neurological Surgery, University of Wisconsin, 600 Highland Avenue, Madison, WI 53792-3232.

© American Society of Neuroradiology

MR angiography revealed a 2-cm midbasilar aneurysm without evidence of subarachnoid hemorrhage. A thrombus was present in the aneurysm, and high signal intensity abnormality was seen adjacent to the aneurysm. Both DSA and CT angiography showed a fusiform basilar artery aneurysm situated below the origins of the superior cerebellar arteries and above the origins of the anteroinferior cerebellar arteries (Fig 1). The left vertebral artery was dominant, and the right vertebral artery supplied only the ipsilateral posteroinferior cerebellar artery. Bilateral carotid artery injections and MR angiography provided no evidence of posterior communicating arteries.

Because of the fusiform nature of the aneurysm, its location, and the presence of an intramural thrombus, clipping was not attempted, and instead, a decision was made to attempt treatment by performing endovascular occlusion of the left vertebral artery. Because of the lack of collateral circulation, however, an external carotid artery to superior cerebellar artery bypass was performed before occlusion of the left vertebral artery.

A left superficial temporal artery to superior cerebellar artery bypass was performed first. The superficial temporal artery was selected because of previous reports of aneurysm rupture occurring after a bypass procedure using a saphenous vein graft (2, 3). After completion of the superficial temporal artery-superior cerebellar artery anastomosis, patency of the shunt was confirmed by sonography using an Acuson XP-128 scanner with a 7.0-MHz sector transducer. The probe was placed directly on the graft, and both color and pulsed Doppler information was recorded. Although an abnormal slow bidirectional waveform was noted, neither antegrade nor retrograde flow predominated (Fig 2). The superficial temporal artery lumen and anastomosis sites were poorly visualized.

Several days after the initial bypass was performed, DSA was performed to evaluate for parent artery occlusion. Because of slow flow through the superficial temporal artery graft, however, it was decided to perform another bypass procedure to improve blood flow to the distal basilar distribution further. Thus, an external carotid artery to superior cerebellar artery bypass using a saphenous vein graft was performed next. Intraoperative assessment of the bypass patency was accomplished using duplex sonography (Fig 3). Unlike the first study, the saphenous vein graft lumen could be easily visualized, excluding the presence of the thrombus. The shunt was clearly patent, and the proximal anastomosis was seen as a mild, hemodynamically insignificant narrowing of the vessel. Slow bidirectional flow was observed during both gray scale and color Doppler examinations and suggested the presence of simultaneous, evenly matched pulse pressures from both proximal and distal ends of the graft. There was also a lack of flow during diastole. Because these findings suggested a higher risk for graft thrombosis, the patient was taken directly from the operating room to the angiography suite where endovascular occlusion of the left vertebral artery was performed.

DSA revealed slow antegrade flow through the saphenous vein graft, confirming its patency. This flow, however, increased markedly during temporary occlusion of the left vertebral artery. After a 40-min balloon test occlusion, the left vertebral artery was occluded just inferior to the level at which the collaterals

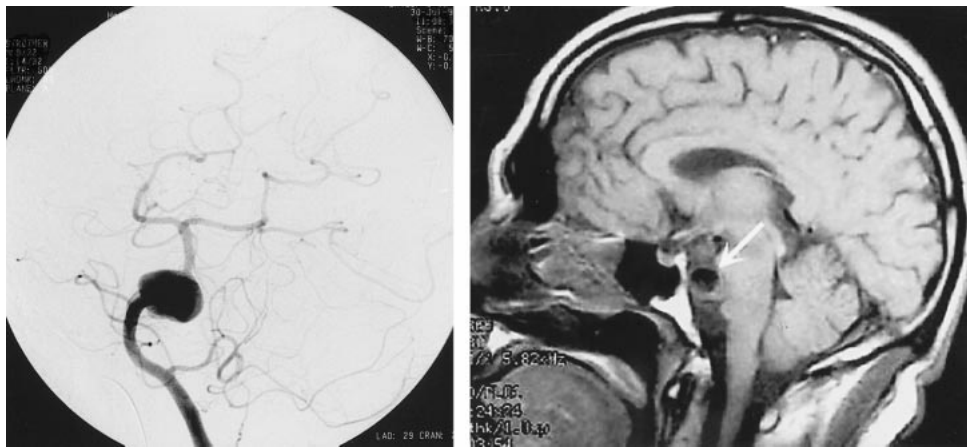


FIG 1. Preoperative digital subtraction angiogram (*left*) and sagittal view MR image of the brain (*right*) show a partially thrombosed fusiform midbasilar artery aneurysm (*arrows*). Note the dominant left vertebral artery supplying the basilar artery.

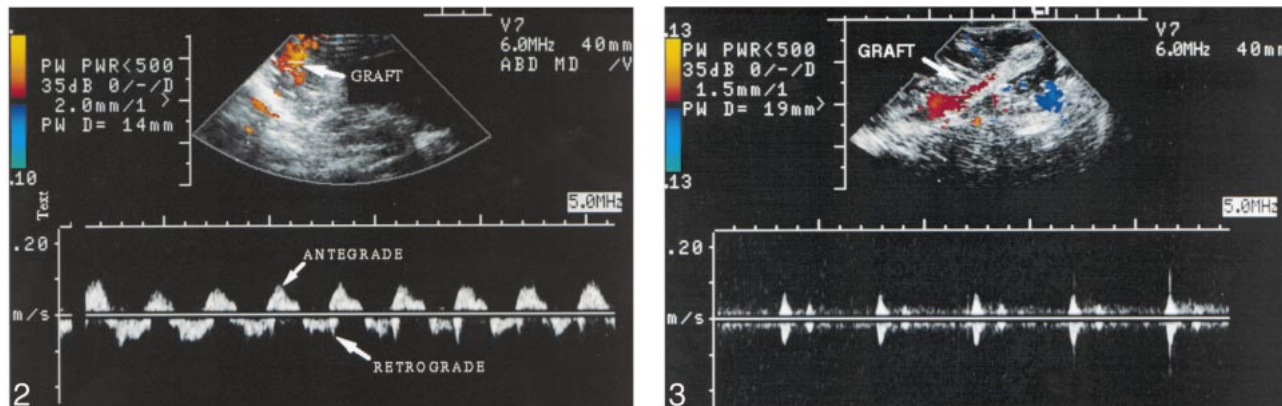


FIG 2. Color and pulsed Doppler sonographic image obtained during superficial temporal artery bypass surgery. The anatomic structure coded in *red* is the superficial temporal artery just proximal to the anastomosis. Portions of the waveform above the baseline represent flow toward the transducer (antegrade), whereas portions below the baseline represent flow away from the transducer (retrograde). Note the slow, bidirectional ("to-and-fro") flow, which implies sequential perfusion of the graft from different circulations.

FIG 3. Color and pulsed Doppler sonographic image of the saphenous vein graft (*arrow*) proximal to anastomosis with the posterior cerebral artery. The shunt is patent with low velocity flow. In comparison with Figure 2, simultaneous bidirectional flow with high resistance can be seen. Note portions of the waveform above and below the baseline at nearly identical times. This is consistent with a shunt simultaneously being perfused from both the external and internal carotid artery circulations.

from the occipital artery entered the vertebral artery (C2), using a combination of Guglielmi detachable coils and fibered pushable coils (Target Therapeutics/BSX, Fremont, CA).

Postoperatively, the results of the patient's neurologic examination remained unchanged, and the patient was transferred to the rehabilitation service with improving dysarthria and hemiparesis. Follow-up MR imaging/MR angiography performed 14 months after the second operation revealed near-complete resolution of the aneurysm and a patent saphenous vein graft (Fig 4). The patient returned to part-time employment at his previous occupation.

Discussion

DSA is the standard of reference for both preoperative and postoperative assessment of patients undergoing EC-IC procedures. It is also used routinely for intraoperative evaluation of graft patency. Intraoperative DSA, however, has significant limitations. It is invasive, time consuming, and requires the use of ionizing radiation. Moreover, physical

constraints related to the surgical and angiographic equipment required for performance of an EC-IC bypass make it impossible to integrate fully an angiographic examination into a surgical procedure. Often, the operative set-up must be essentially taken down and the angiographic equipment moved into the field each time an angiographic study is performed. Because of these limitations, a noninvasive, real-time, easily repeatable technique that provides information regarding flow dynamics within the graft would be beneficial as an adjunct to the EC-IC bypass procedures.

Since its initial intraoperative application in the 1950s, sonography has proven to be an important tool in neurosurgical procedures (4). Sonographic imaging is routinely used for intraoperative localization of mass lesions in the CNS (5). More recently, development of Doppler sonography and miniature transducers has allowed for accurate in-

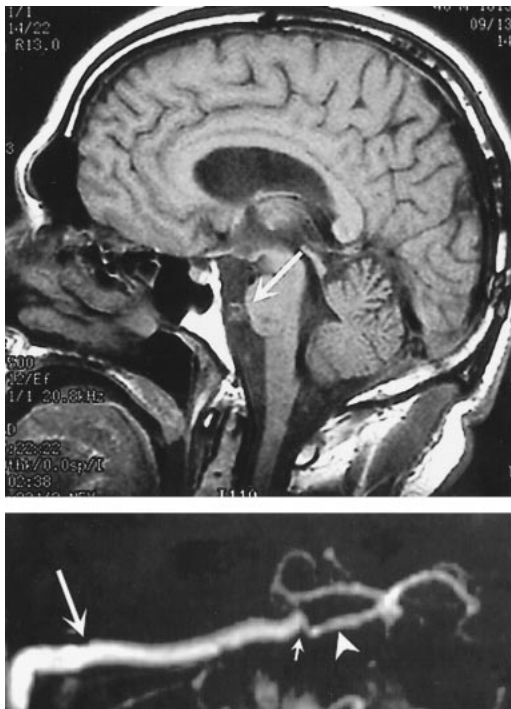


FIG 4. Postoperative sagittal view MR image of the brain (top), obtained 14 months after the second EC-IC bypass procedure was performed, reveals near-complete resolution of the aneurysm (arrow). MR angiogram (bottom) shows filling of the superior cerebellar artery (arrowhead) through an anastomosis (small arrow) with a patent saphenous vein graft (large arrow). No blood flow was detected in the aneurysm.

traoperative detection of flow in small vessels. This technology has allowed for objective determination of vessel patency and is especially useful during aneurysm and skull base surgery (1, 6). A significant limitation of Doppler sonography, however, is its inability to localize the source of flow accurately. Duplex sonography offers a solution to this limitation and has recently been reported to be of value as an intraoperative tool during carotid endarterectomy (7). In an attempt to show the feasibility of using duplex sonography as an alternative to intraoperative DSA, examinations were performed during two EC-IC bypass procedures as part of the treatment of a fusiform midbasilar aneurysm.

During both operations, the sonographic examinations were useful in the assessment of patency and the direction of blood flow in bypass grafts. Whereas patency of the saphenous vein graft was easily established by direct visualization, the superficial temporal artery lumen could not be imaged well, probably because of the large size of the transducer and the very small size of the graft. Moreover, distal anastomosis could not be evaluated accurately by sonography because of the small caliber of the vessels. Sonography, however, provided useful information regarding flow characteristics in the grafts. Immediately after completion of each anastomosis, a biphasic pattern of flow was observed in both grafts. This flow pattern was thought to be the result of the presence of opposing

pressure derived from antegrade flow in the superior cerebellar arteries. This bidirectional flow pattern cannot be seen on intraoperative DSA because the contrast medium is administered through a single arterial pedicle and because injection of contrast medium may cause pressure alterations and change the baseline hemodynamics of the vessel. For these reasons, and because DSA does not provide hemodynamic information during systole and diastole, accurate assessment of flow dynamics is not possible using standard DSA techniques. As a result, delayed filling or clearance of contrast medium caused by this bidirectional blood flow during an EC-IC bypass procedure may be interpreted as a stricture, urging unnecessary exploration of the graft. For our patient, sonography revealed biphasic flow through the saphenous vein graft, which prompted us to proceed directly from the operating room to the angiography suite, where parent artery occlusion was undertaken. As predicted based on the sonographic results, DSA confirmed that the delayed flow through the saphenous vein graft was due to a high distal opposing pressure from the superior cerebellar artery. This was obliterated when vertebral artery occlusion was performed.

We noted that rapid sonographic assessment of the flow characteristics of the grafts was helpful in assessing graft patency and hemodynamics. Sonography played a fundamental role in our decision regarding the timing of parent artery occlusion, because visualization of bidirectional flow in the saphenous vein graft lumen prompted us to proceed to vertebral artery occlusion sooner than initially planned. In summary, intraoperative duplex sonography is a rapid, noninvasive, and sensitive technique for assessing graft hemodynamics during EC-IC bypass operations. This technique can be used in conjunction with or in place of DSA.

Acknowledgment

We thank Pat Giuliani for editorial support.

References

- Giltsbach JM, Hassler WE. **Intraoperative Doppler and real time sonography in neurosurgery.** *Neurosurg Rev* 1984;7:199-208
- Anson J, Stone J, Crowell R. **Rupture of a giant carotid aneurysm after extracranial-to-intracranial bypass surgery.** *Neurosurgery* 1991;28:142-147
- Heros R, Ameri A. **Rupture of a giant basilar aneurysm after saphenous vein interposition graft to the posterior cerebral artery.** *J Neurosurg* 1984;61:387-390
- Masciopinto J, Badie B, Dempsey R. **Sonography of the nervous system.** In: Crockard A, Hayward R, Hoff J (eds), *Neurosurgery*. Oxford: Blackwell Science, Ltd.;2000:817-827
- Hammoud MA, Ligon BL, el Souki R, Shi WM, Schomer DF, Sawaya R. **Use of intraoperative ultrasound for localizing tumors and determining the extent of resection: a comparative study with magnetic resonance imaging.** *J Neurosurg* 1996;84:737-741
- Yamasaki T, Moritake K, Hatta J, Nagai H. **Intraoperative monitoring with pulse Doppler sonography in transsphenoidal surgery: technique application.** *Neurosurgery* 1996;38:95-98
- Padayachee TS, Brooks MD, Modaresi KB, Arnold AJ, Self GW, Taylor PR. **Intraoperative high resolution duplex imaging during carotid endarterectomy: which abnormalities require surgical correction?** *Eur J Vasc Endovasc Surg* 1998;15:387-393