

Are your MRI contrast agents cost-effective?

Learn more about generic **Gadolinium-Based Contrast Agents.**



**FRESENIUS
KABI**

caring for life

AJNR

**Transfer of a Self-Expanding Stent to a Braided
Microcatheter with the Aid of Transcatheter
Illumination: Technical Report and Illustrative
Case**

L. Paul Broadbent, Christopher J. Moran, Arvind Nehra, Dewitte
T. Cross III and Colin P. Derdeyn

This information is current as
of April 30, 2024.

AJNR Am J Neuroradiol 2003, 24 (8) 1517-1519
<http://www.ajnr.org/content/24/8/1517>

Transfer of a Self-Expanding Stent to a Braided Microcatheter with the Aid of Transcatheter Illumination: Technical Report and Illustrative Case

L. Paul Broadbent, Christopher J. Moran, Arvind Nehra, Dewitte T. Cross, III, and Colin P. Derdeyn

Summary: A new self-expanding stent approved for the treatment of wide-necked intracranial aneurysms can be difficult to deploy in tortuous vascular anatomy. Some of the difficulty may be attributed to deformation of the delivery microcatheter. We describe a technique for transferring the stent into a braided microcatheter.

Detachable coils are a proved effective method of treatment for some patients with intracranial aneurysms (1). Aneurysms with wide necks, however, may be very difficult to treat with coils alone. The balloon remodeling technique introduced by Moret et al (2) has allowed endovascular practitioners to treat many of these aneurysms with unfavorable neck-to-dome ratios. Another approach has been to use a balloon-expandable coronary stent to bridge the aneurysm neck and serve as a buttress for the coils within the aneurysm (3). These stents are rigid, require high pressures for deployment, and are not approved by the Food and Drug Administration for this indication.

Recently, the Neuroform stent (Boston Scientific/Target Therapeutics Inc., Natick, MA) has become available. This is a self-expanding, nitinol stent that has been approved under a humanitarian device exemption by the Food and Drug Administration for use in patients with wide-necked intracranial aneurysms. The delivery system consists of a 3-French (0.09 in) outer diameter nonbraided microcatheter, the stent preloaded within this microcatheter near the distal tip, and a 2-French (0.028 in) stabilizer catheter within an inner lumen, which allows placement of a (0.014 in) microguidewire. The stabilizer catheter is designed to buttress the stent so that the outer catheter may be withdrawn uncovering the stent for deployment. The microcatheter for standard coiling of the aneurysm may be placed in the aneurysm before stent deployment. The stent delivery system can then

be placed over the neck of the aneurysm. When the stent is deployed, it pins the microcatheter positioned within the aneurysm against the parent vessel for added support during coiling. After the coils are deployed within the aneurysm, the microcatheter is removed. The stent exerts very little radial force, which allows microcatheter withdrawal. Alternatively, after the stent has been deployed, the microcatheter may be placed through the interstices of the stent. The danger of this latter technique is the possible displacement of the stent during microcatheter manipulation.

In our experience, it can be very difficult to deploy this stent around sharp curves, particularly in the carotid siphon. Proximal tortuous vessels add to this difficulty. It is likely that the nonbraided delivery catheter deforms in this situation, either ovalizing or kinking, preventing smooth and controlled deployment of the stent. One solution to this problem discussed in the endovascular community is to transfer the Neuroform stent to a braided microcatheter. We have successfully used this method and herein describe a useful technique.

Technical Report and Illustrative Case

A 50-year-old right-handed woman with a history of polycystic renal disease and hypertension presented with neck pain. MR imaging of the cervical spine showed a probable aneurysm of the distal right vertebral artery. A second MR study obtained for better definition of the lesion revealed partial thrombosis of a large distal right vertebral artery aneurysm.

Endovascular therapy, with the possible use of a stent, was pursued. The procedure, including the use of the Neuroform stent, was explained to the patient, and signed consent was obtained. Daily administration of clopidogrel bisulfate (Plavix; Bristol-Myers Squibb) (75 mg/day) was started 5 days before the planned intervention. Aspirin was not used because of the patient's renal disease. Digital subtraction cerebral angiograms obtained at the time of treatment showed an irregularly shaped dissecting aneurysm of the distal right vertebral artery (Fig 1A and B). A small posterior inferior cerebellar artery arose from the diseased segment of the vessel. Considering this anatomy, we elected to stent and coil the aneurysm rather than trap the diseased segment of the vessel.

The patient was anticoagulated with an IV administered 5000-U bolus of heparin (USP, Wyeth-Ayerst), and systemic heparinization was maintained throughout the procedure. The target activated clotting time was 300 s.

A 5-French Envoy guiding catheter was placed in the mid-cervical right vertebral artery, and road mapping images were obtained. A 3.5 × 20 mm Neuroform stent was placed over a

Received March 14, 2003; accepted March 23.

From the Interventional Neuroradiology Service of the Mallinckrodt Institute of Radiology (L.P.B., C.J.M., A.N., D.T.C., C.P.D.), and the Departments of Neurological Surgery (C.J.M., D.T.C., C.P.D.) and Neurology (C.P.D.), Washington University School of Medicine, St. Louis, MO.

Address reprint requests to Colin Derdeyn, Mallinckrodt Institute of Radiology, 510 South Kingshighway Boulevard, St. Louis, MO 63110.

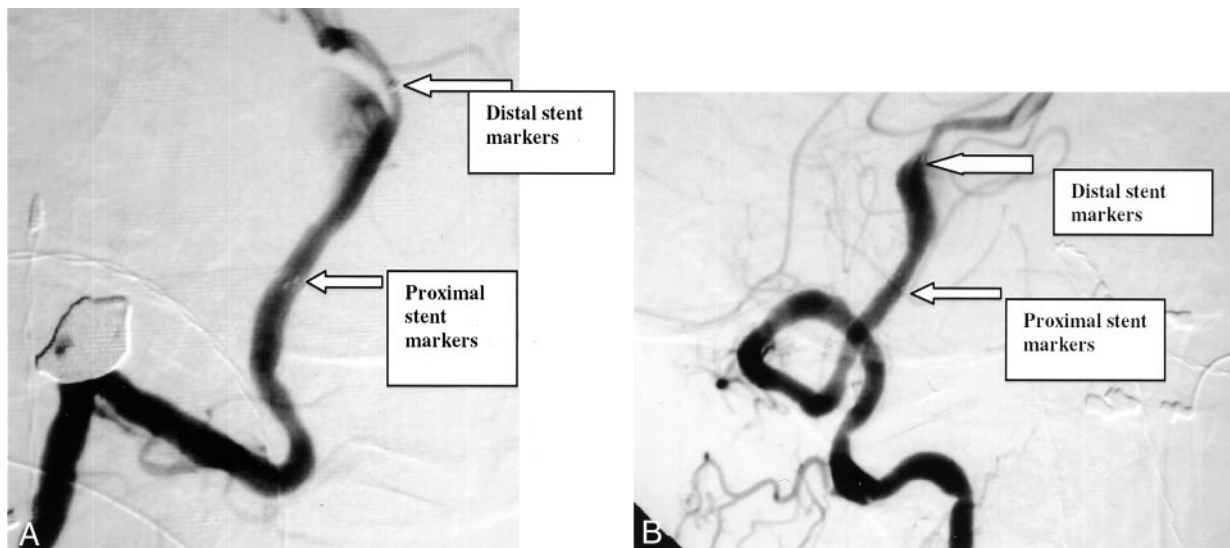


FIG 1. Stent markers. Oblique anteroposterior (A) and lateral (B) projections after injection of the right vertebral artery. A 3.5 × 20-mm Neuroform stent has been placed across the neck of a partially thrombosed dissecting aneurysm of the distal vertebral artery. Stent markers are indicated by arrows and text boxes.

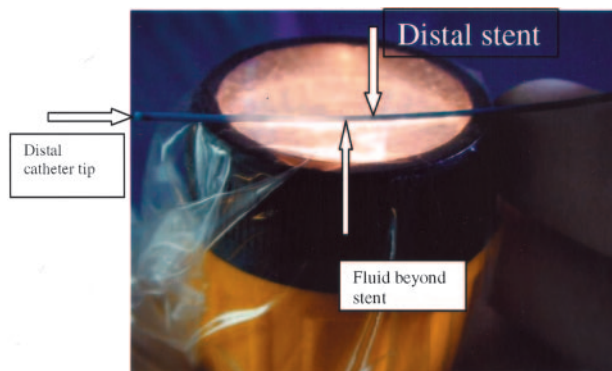


FIG 2. Distal tip of Mass TRANSIT catheter over flashlight in sterile sonography sleeve. Arrow, distal stent. Opacity beyond the stent is fluid within the catheter.

Transcend 14 guidewire (Boston Scientific/Target Therapeutics Inc.) across the aneurysm neck without difficulty. We were unable to deploy the stent despite multiple attempts with the standard delivery system. We removed the guidewire and inner stabilization tube and tried several other maneuvers that had been successful in previously treated patients, including a Coil Pusher 16 (Boston Scientific/Target Therapeutics Inc.) and a 0.018-in Roadrunner guidewire (Cook Inc., Bloomington, IN) to push the stent out of the delivery catheter. These maneuvers were also unsuccessful.

The delivery system was removed to load the stent into a braided microcatheter. We chose the 0.037-in outer diameter, 0.027-in inner diameter Mass TRANSIT microcatheter (Cordis Neurovascular, Inc., Miami, FL). We held the tip of the delivery catheter in the hub of the Mass TRANSIT and pushed the stent in with the stiff end of the Coil Pusher 16 (Boston Scientific/Target Inc.). It was difficult to follow the progress of the stent in the catheter unless we held the catheter up to the room lights. In a more recent case, we used a flashlight in a sterile sonography sleeve to transilluminate the catheter and follow the progress of the stent to the tip more easily (Fig 2). A Transcend 14 guidewire was back-loaded into the Mass TRANSIT through the Neuroform stent, and the system was easily placed across the neck of the aneurysm. The guidewire was removed and the Target Coil Pusher 16 slowly advanced until

it came into contact with the proximal aspect of the stent. Retracting the Mass TRANSIT while stabilizing the stent with the Coil Pusher 16 then deployed the stent. Very little resistance was encountered with this maneuver, and the stent deployed in a controlled manner. A post-placement angiogram showed good bridging of the aneurysm neck (Fig 1A and B). A 90-degree Prowler Plus (Cordis Neurovascular, Inc.) was then advanced into the aneurysm over the Transcend 14 guidewire. The aneurysm was coiled while maintaining patency of the right posterior inferior cerebellar artery. The patient tolerated the procedure satisfactorily and was discharged home after a 1-night stay in the neurosurgical intensive care unit.

Discussion

We have encountered difficulty in deploying the Neuroform stent in tortuous anatomy. This may be because of deformation of the nonbraided delivery catheter, which either ovalizes or kinks as it traverses curves in the vessels. This deformity probably accounts for the difficulty in deployment of the system observed. Transfer of the Neuroform stent to a braided microcatheter is a useful technique in these situations. We herein report use of the Mass TRANSIT. We have also used the Renegade HI-FLO (Boston Scientific/MEDI-TECH, Natick, MA) with similar success. This braided microcatheter likewise resists kinking and ovalizing and has an outer hydrophilic coating and an inner lumen of polyethylene terephthalate.

The Neuroform stent is preloaded within the delivery microcatheter to protect the stent before deployment. The stent is visible in its constrained state within this catheter but requires markers for fluoroscopic visibility when deployed. The tolerances of this delivery system are very exacting, and any deformation of the delivery catheter compromises these tolerances. Substitution of a kink-resistant nondeforming braided microcatheter has, in our experience, eased deployment of this very flexible stent. Knowledge of the location of this stent in the braided microcatheter is essential to accurate placement near the tip in preparation for delivery. If the stent

is inadvertently advanced beyond the end of the delivery catheter tip, partial deployment may damage the stent and make it nondeployable. The use of trans-illumination enables the operator to know where the stent is in relation to the microcatheter tip. The stent is visible through the currently provided delivery catheter, but the Mass TRANSIT is opaque without trans-illumination. The Renegade HI-FLO is more translucent than the Mass TRANSIT, and transillumination is not necessary.

Another method to transfer the stent rather than through the hub is a "tip-to-tip" transfer over a guidewire introduced through the stent and careful pushing of the stent and guidewire into the new catheter tip. Future generations of the Neuroform likely will use a braided delivery microcatheter. This should overcome some of the technical challenges discussed in this report. Although it should be noted that modification of the stent delivery system is not specifically mentioned in the humanitarian device exemption consent, physicians are allowed to use Food and Drug Administration-approved devices in nonapproved fashions to treat patients on an individual basis. Until the braided delivery microcatheter is available, use of trans-illumination and transferring the Neuroform

stent to a braided microcatheter is a useful technique for successful stent deployment.

Conclusion

The existing delivery system for the Neuroform stent is difficult to use in tortuous anatomy, likely owing to ovalizing of the non-braided outer microcatheter. In this report, we describe a technique for transferring the Neuroform stent into a braided microcatheter. We have successfully used this technique in several instances.

References

1. Molyneux A, Kerr R, Stratton I, et al. **International Subarachnoid Aneurysm Trial (ISAT) of neurosurgical clipping versus endovascular coiling in 2143 patients with ruptured intracranial aneurysms: a randomised trial.** *Lancet* 2002;360:1267-1274
2. Moret J, Cognard C, Weill A, Castaing L, Rey A. **The "remodeling technique" in the treatment of wide neck intracranial aneurysms: angiographic results and clinical follow-up in 56 cases.** *Intervent Neuroradiol* 1997;3:21-35
3. Higashida RT, Smith W, Gress D, et al. **Intravascular stent and endovascular coil placement for a ruptured fusiform aneurysm of the basilar artery: case report and review of the literature.** *J Neurosurg* 1997;87:944-949