

**Are your MRI contrast agents cost-effective?**

Learn more about generic Gadolinium-Based Contrast Agents.



**FRESENIUS  
KABI**

caring for life

**AJNR**

## **Head and Neck Radiology: A Teaching File**

*AJNR Am J Neuroradiol* 2003, 24 (9) 1922

<http://www.ajnr.org/content/24/9/1922>

This information is current as  
of May 6, 2024.

### **Head and Neck Radiology: A Teaching File**

Anthony Mancuso, Hiroya Ojiri, and Ronald Quisling. Philadelphia, PA: Lippincott Williams & Wilkins; 2002. 413 pages. 1109 illustrations. \$99

This teaching file is a very well-organized and clearly written casebook that covers the radiographic and clinical issues facing the radiologist with an active head and neck radiology practice. The text comprises of 100 teaching cases that span the breadth of head and neck imaging. The book contains more than 1000 images of excellent quality, including CT scans and MR images, with a somewhat greater emphasis on MR images. Additionally, anatomic diagrams are provided for each case. The diagrams are well labeled and are helpful in understanding the complex anatomy of this region.

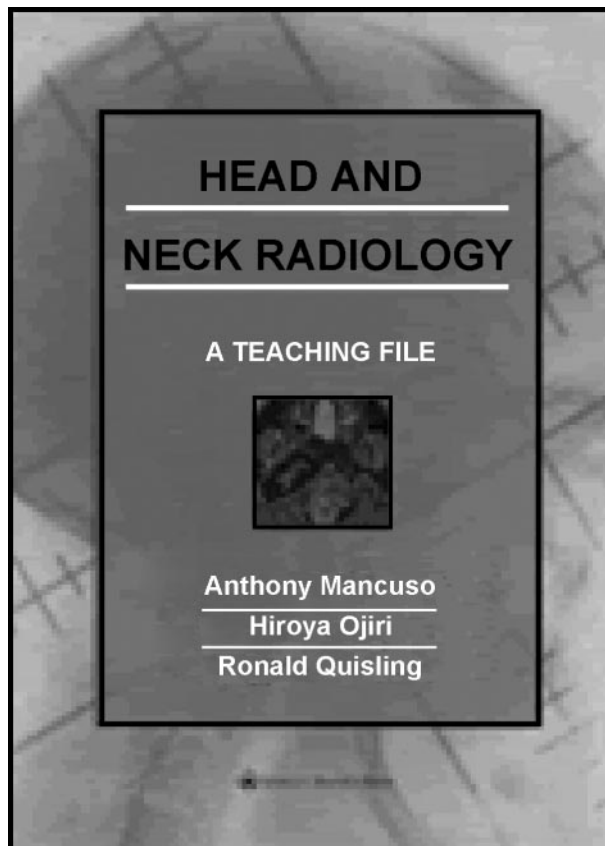
The format for each case presentation is as follows: 1) several images and a brief clinical history are provided; 2) several questions are posed by the authors to get the reader thinking along the right track; 3) significant radiographic findings are described, and salient clinical and radiologic features are summarized; 4) pertinent anatomy is outlined and accompanied by informative diagrams; 5) differential diagnoses are considered; 6) diagnosis is made; 7) diagnostic imaging approach is discussed; 8) clinical points of importance and supplemental information are provided, and additional information is provided with an emphasis again on the clinical implications of the pathologic entity; 9) answers are provided to the questions previously posed by the authors.

The section on diagnostic imaging emphasizes the points to consider in arriving at the correct diagnosis. This incorporates the anatomy and the morphology of the lesion and then emphasizes the clinical issues that must be addressed by the radiologist.

After the provided answers, additional radiographic material is presented. Often, the radiographs are from similar cases that show the variability within the same pathologic diagnosis or depict a disorder in a differential diagnosis that has a similar radiographic appearance.

The book is thorough in its review of head and neck pathologic abnormality. Chapters are organized into the following sections: orbit/visual pathway, central skull base, temporal bone/posterior fossa, sinonasal region, mandible/maxilla, parotid/submandibular glands, nasopharynx/oropharynx, oral cavity/floor of mouth, infrahyoid neck, larynx/hypopharynx, and thyroid and parathyroid.

*Head and Neck Radiology: A Teaching File* is a very practical text that emphasizes the interplay of clinical and radiographic issues and the necessity for solid knowledge of relevant anatomy. The images are generally of excellent quality, although on occasion they are too "coned down" so that the anatomy is actually less recognizable. The images are almost entirely MR



images and CT scans, which are certainly the foundation of cross-sectional imaging. Still, it would be interesting to see a few more cases correlated with either sonograms or nuclear imaging studies because other modalities often are an integral part of routine imaging.

The anatomic diagrams are excellent and well labeled. However, much of the anatomic information is provided only in outline form. To derive maximal benefit from this teaching file, it would be of great value to also have a more comprehensive textbook available, side by side, so that the anatomic details can be reviewed more thoroughly by using the standard text. This is certainly recommended for those who are less knowledgeable in this field.

Overall, *Head and Neck Radiology: A Teaching File* is a textbook that is enjoyable to read and would be useful to beginners in the field and to those who are more experienced. The beginners can learn a tremendous amount from this assortment of teaching cases, and the more experienced radiologists can use the text to hone their skills and better prepare for the clinical implications of their imaging procedures.