

Are your MRI contrast agents cost-effective?

Learn more about generic Gadolinium-Based Contrast Agents.



FRESENIUS
KABI

caring for life

AJNR

Celebrating 35 Years of the AJNR: November 1980 edition

AJNR Am J Neuroradiol 2015, 36 (11) 2191

doi: <https://doi.org/10.3174/ajnr.P0003>

<http://www.ajnr.org/content/36/11/2191.citation>

This information is current as of May 18, 2024.

Celebrating 35 Years of the AJNR

November 1980 edition

521

Brainstem Evaluation with CT Cisternography

J. Richard Steele¹
James C. Hoffman¹

Seventy-eight positive contrast computed tomography (CT) cisternograms were reviewed to assess the normal anatomy of the brainstem and its surrounding cisterns. Normal brainstem and cisternal anatomy was found to be constant and symmetrical. The review included six patients with brainstem gliomas and five patients with extraaxial masses. In these patients CT cisternography accurately identified mass formation and permitted the confident distinction of extraaxial from intra-axial masses. CT cisternography is a safe and accurate method for evaluating the anterior compartment of the posterior fossa. This procedure is particularly applicable to those cases where conventional CT yields insufficient diagnostic information.

Before the advent of computed tomography (CT), patients suspected of harboring a brainstem glioma were subjected to angiography and pneumoencephalography. In most instances CT is now capable of identifying a brainstem mass [1, 2], although angiography and pneumoencephalography are frequently considered necessary to support the diagnosis [1-4]. The reports of early investigators concerning the potential value of positive contrast CT cisternography encouraged us to use this technique for brainstem evaluation [5-7]. This report discusses our experience with CT cisternography as it relates to the normal and abnormal brainstem, and the application of this technique to those cases in which conventional CT of the brainstem is negative or insufficiently diagnostic for patient management.

Materials and Methods

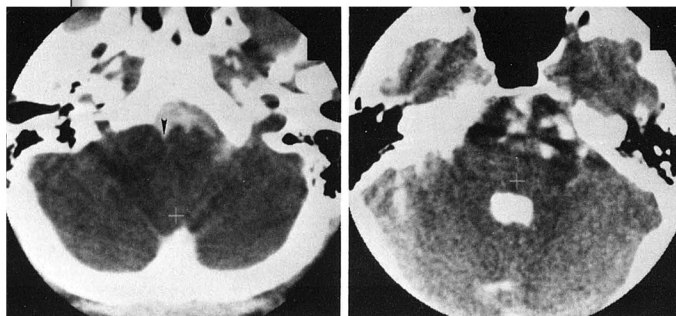
CT cisternography is performed by the lumbar subarachnoid instillation of 6 ml of metrizamide in a concentration of 150 mg/ml under fluoroscopic control. A proportionately smaller volume is administered to infants and children [8]. With the patient still prone, the fluoroscopic table is tilted into a 45° Trendelenburg position with the head flexed (chin tucked) for about 2 min to allow passage of the contrast agent into the intracranial cisterns. The patient remains in a prone hanging-head position during transport to a General Electric 8800 CT scanner. CT scanning is then carried out in the supine position, parallel to the canthomeatal line. Adjacent 10 mm thick slices are obtained. When greater detail is sought, 5 mm slices are used. The use of coronal scanning varies with the individual circumstance. No attempt is made to return the contrast to the lumbar sac at the end of the examination.

During a 2 year period, 78 CT cisternograms were obtained in our radiology department for a variety of indications (table 1). All cisternograms were reviewed in order to determine the appearance of the normal and abnormal brainstem. Symmetry of the brainstem and its surrounding cisterns was noted. Where possible, the transverse diameters of the medulla, pons, and cerebral peduncles, as well as the distance from the anterior poles to the fourth ventricle, were determined from axial images. Our experience includes six intraxial and five extraaxial masses (arachnoid cyst, cholesteatoma, choroma, hypoglossal neuroma, and metastasis). The cisternographic distinction between these two groups was sought. In addition, a chart review was conducted for all patients who underwent CT cisternography to determine the incidence and severity of adverse symptoms attributable to the examination.

Received April 11, 1980; accepted after revision June 24, 1980.

¹Department of Radiology, Emory University Clinic, 1365 Clifton Rd. N.E., Atlanta, GA 30322. Address reprint requests to J. R. Steele.

This article appears in November/December 1980 AJNR and February 1981 AJR.
AJNR 1:521-526, November/December 1980
0195-1061/80/0016-0521\$00.00
© American Roentgen Ray Society



551

CT of the Lumbosacral Spine: Importance of Tomographic Planes Parallel to Vertebral End Plate

James C. Hirschy¹
William M. Leue²
Walter H. Berninger³
Richard H. Hamilton³
Gerald F. Abbott¹

An experimental computer program capable of reformatting stored display data from a CT scanner into true cross-sectional images of the spine has been clinically tested over a 1 year period. With this program, tomographic planes exactly parallel to the vertebral end plate can be imaged at the lumbosacral level even in patients who are markedly rotated or have scoliotic deformities. The reformatted image planes are tilted in the dorsoventral and mediolateral directions to compensate for lordosis or scoliosis. The reformatting can also produce images in coronal and sagittal planes on axes other than true horizontal or vertical. The program has been used in the examination of 269 spines and has been found to be valuable in demonstrating the spinal canal and the intervertebral foramina.

The computed axial tomogram should be the ideal instrument for the examination of the spine, particularly for the evaluation of the size and shape of the spinal canal and the intervertebral disc. However, several technical limitations have hindered its completely successful application and, in a recent report by Mankin and Teng [1], preoperative evaluation of the spinal canal by CT was described as unreliable compared with the myelogram.

One of the problems with CT examination of the spine has been the inability to determine the exact position of an axial image within the spine. The placement of radiopaque catheters of graduated length on the patient's skin and correlating the number of catheters seen in the cross section on the CT image with the number of catheters at a specific level seen on the preliminary radiograph provided a useful but somewhat awkward solution to the problem of localization [2-4].

A better solution is the digital projection radiograph (GE-Scout View) that can be viewed on the CT monitor. An electronically generated line can be precisely located on the digital radiograph and the CT scanner can be programmed to obtain an axial image at that level [5].

Excessive thickness of the tomographic section has also been a problem, since small abnormalities become lost in the summation of data from a thick slice [6-8]. The recent availability of 1.5-2.0 mm scan collimation has surmounted this obstacle.

A further problem has been the inability to align the plane of the cross section at right angles to the long axis of the spinal canal or parallel to the vertebral end plate [9]. This problem is overcome in the upper four-fifths of the lumbar spine by tilting the gantry. The digital radiograph can then be used to determine the desired angle of gantry tilt for each axial slice. Unfortunately, the tilt has been insufficient to enable the plane to become parallel to the lumbosacral disc (L5-S1) in more than 95% of the patients in this series. Many patients also have lateral curvatures (scoliosis) and there is no mechanical means of making the scan plane parallel to the laterally tilted vertebrae.

These problems of tilt have been addressed by a computer program that allows

