

Ioglundide: A New Nonionic Contrast Medium for Myelography and Cisternography with Reduced Neurotoxicity

R. E. Gonsette¹ and L. Liesenborghs²

Ioglundide, a new nonionic contrast medium, has attracted attention by its virtual absence of immediate or delayed effect on brain electrical activity in animal studies. After 126 myelographies or cisternographies with ioglundide, routine electroencephalograms (EEG) and brain potential frequency analyses were performed in 109 and 73 patients, respectively. EEG changes were noted in 3.7% of subjects. Moderate meningeal signs were present in 16% of subjects. No severe adverse reactions (psychoorganic syndrome, asterixis, or hallucination) were observed. Ioglundide appears to represent a marked advance in neuroradiology in providing for the comfort of patients and the safety of the radiological procedures.

Ioglundide (fig. 1) is a nonionic contrast medium developed by Guerbet (Aulnay-sous-Bois, France) in 1976. At that time, preliminary animal experiments conducted in our laboratory demonstrated that the neurotoxicity of the new compound was very low. However, solutions available for use were unstable and more elaborate studies were postponed. In 1978, using the corticospinal evoked-potentials technique in monkeys, Hilal et al. [1] demonstrated that the neurotoxicity of ioglundide was lower than that of metrizamide. Recently we found that after pericerebral injection of lyophilized ioglundide in the guinea pig, delayed electroencephalographic (EEG) changes detected by monitored EEG frequency analysis were less marked for ioglundide than for other contrast media [2]. Since further animal experiments indicated a reduced cellular toxicity and epileptogenic activity for ioglundide as well, it was decided to investigate the possibility of a better clinical tolerance in man.

Subjects and Methods

Ioglundide was injected intrathecally in 126 patients by lumbar or suboccipital puncture using a 22 gauge needle. The regions investigated and the number of patients in each category were as follows: lumbar, 38; thoracic plus cervical, 11; cervical, 41; basal cisterns, 33; ventricles, three. Myelography was performed using an iodine concentration of 280 mg I/ml and a volume of 5 ml for cervical and lumbar investigations and 10 ml for total myelographies. A concentration of 140 mg I/ml in a volume of 10 ml was used for computed tomographic (CT) investigations (cisternographies and cervical myelographies). The total dose of iodine was 1.4–2.8 g. No premedication was given. After all procedures, patients were asked to remain in bed with their head slightly elevated for 6 hr.

Follow-up neurologic examinations were performed at 8 hr, 24 hr, and 48 hr. Patients were questioned about the presence of any minor side effects as well as more severe adverse reactions (e.g., lapses of consciousness, hallucinations, memory disturbances, dysphasia). Routine EEG in 109 patients and EEG frequency analysis in 73 patients were performed before and 8 hr or 24 hr after the radiographic procedures.

Results

Symptoms of meningeal irritation occurring as side effects of ioglundide myelography were moderate. Sixteen (14%) of 126 patients reported headache, three reported nausea, and one reported vomiting. Muscular pain was reported by five patients. No clinical signs of spinal or cerebral dysfunction were reported or observed.

Results of the EEG studies are shown in table 1. The incidence of altered EEG after intrathecal injection of ioglundide appears exceptionally low (3.7%) compared with other contrast media.

Discussion

The development of metrizamide for the opacification of perimedullar and pericerebral spaces represents a definite advancement in the field of contrast media. However, despite better tolerance and increased safety, sporadic unexpected adverse reactions have been reported (e.g., psychoorganic syndromes, asterixis, speech disturbances). A recent prospective study by Hauge and Falkenberg [3] reported neuropsychologic reactions and other side effects after metrizamide myelography in 100 patients. Confusion and amnesia were observed in 6% and hallucinations in 4% of the patients. A recent publication by Vespignani et al. [4] reported transient but definite EEG disturbances after metrizamide administration in 30 (32.6%) of 92 patients. These data correspond well with our personal experience using metrizamide in myelography and cisternography.

We have found iopamidol, a more recently developed nonionic contrast medium, to be somewhat more epileptogenic than metrizamide in animal studies. This suggests that iopamidol does not represent a marked improvement over metrizamide. It is quite difficult to estimate human tolerance to this new compound, as its clinical use is still limited. However, epileptic seizures and psychoorganic syndromes have already been reported, and EEG changes have been observed in 16.5%–30% of subjects [5–10].

¹ Department of Neurology, Clinique Saint-Pierre, Ottignies LLN 1340, Belgium. Address reprint requests to R. E. Gonsette.

² Department of Radiology, Clinique Saint-Pierre, Ottignies LLN 1340, Belgium.

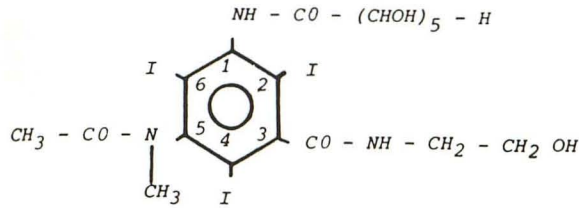


Fig. 1.—Structural formula of ioglutamide

TABLE 1: EEG Changes after Intrathecal Injection of ioglutamide

Procedure: Region	Total Dose Iodine (g)	No. Patients (n = 109)	
		Unchanged EEG	Altered EEG
Myelography:			
Lumbar	2-2.8	35	0
Thoracic	2.8	7	0
Cervical	1.4-2.8	31	2
Computed tomography:			
Cervical	1.4	11	0
Basal cisterns	1.4	21	2
Total nos. (%)		105 (96.3)	4 (3.7)

Note.—EEG = electroencephalographic. Routine EEG examinations in 109 patients and EEG frequency analyses in 73 patients were performed 8 hr or 24 hr after radiographic procedures.

The adverse reactions that have been observed after intrathecal injection of metrizamide or iopamidol clearly demonstrate the need for a better tolerated contrast medium. In general, meningeal signs (headaches, nausea) are caused by the lumbar puncture, but spinal or cerebral symptoms result from the neurotoxic action of contrast media. There is strong correlation between the occurrence of severe adverse reactions and the presence of contrast medium in the basal cisterns and its penetration into the brain tissue, as demonstrated by CT. This is probably why adverse reactions only become apparent 6-8 hr after the examination. When studying the neurotoxicity of contrast media in animal experiments, it is of the utmost importance to monitor brain electrical activities for at least 12 hr. This has been made possible by automatic EEG spectral analysis according to the Berg-Fourier transformation. Using this technique, slow wave bursts have been observed 4-6 hr after pericerebral injection of metrizamide in the guinea pig, similar to those reported in man [2]. In the same experimental conditions, ioglutamide does not produce any changes in EEG activity, even after prolonged contact with the cortex and likely penetration into the brain tissue. Normal EEG readings were recorded in our patients even when a definite intracerebral penetration of ioglutamide was demonstrated by CT.

In at least 70% of our investigated cases, ioglutamide came into contact with brain tissue during the examination. This represents a valuable clinical assessment of the neurotoxic effects of this new contrast medium. The results were encouraging. The minor side effects were similar to those experienced after diagnostic lumbar puncture. Severe adverse reactions, and in particular psychoorganic syndromes, were never observed. The incidence of EEG changes (3.7%) is far lower than that observed after intrathecal injection of metrizamide or iopamidol (mean, 35%).

Despite the technical disadvantages in using a contrast medium that is dispensed as a lyophilized powder, we believe ioglutamide represents a definite advancement for myelography and cisternography in consideration of the comfort of patients and the safety of the neuroradiologic procedures.

REFERENCES

- Hilal SK, Dauth GW, Hess KH, Gilman S. Development and evaluation of a new water-soluble iodinated myelographic contrast medium with markedly reduced convulsive effects. *Radiology* 1978;126:417-422
- Gonssette RE. Immediate and delayed neurotoxicity of newly synthesized contrast media demonstrated by EEG sequential analysis. In: Amiel M, ed. *Contrast media in radiology*. Berlin: Springer-Verlag, 1982:141-147
- Hauge O, Falkenberg H. Neuropsychologic reactions and other side effects after metrizamide myelography. *AJNR* 1982;3:229-232, *AJR* 1982;139:357-360
- Vespignani H, Werner JE, Roland J, et al. Modification de l'activité EEG après injection sous-arachnoïdienne de metrizamide—étude prospective de 92 cas. *Rev Electroencephalogr Neurophysiol Clin* 1982;12:167-176
- Bacarini L, de Nicola T, Gasparini D, Orlando P, Vassallo A. Iopamidol (B 15000), a nonionic water-soluble contrast medium for neuroradiology. *Neuroradiology* 1982;23:81-84
- Belloni G, Bonaldi G, Cassinari V, Moschini L, Orlandini A, Quilici N. Opaque anterior cisternography with a new non-ionic water-soluble contrast medium (iopamidolo). *Neuroradiology* 1980;20:265-265
- Belloni G, Bonaldi G, Moschini L, Quilici N. Cervical myelography with iopamidolo. *Neuroradiology* 1981;21:97-99
- Carella A, Federico F, Di Cuonzo F, Vinjau E, Lamberti P. Adverse side effects of metrizamide and iopamidolo in myelography. *Neuroradiology* 1982;22:247-249
- Drayer B, Suslavich F, Luther J, et al. Clinical trial of iopamidol for lumbosacral myelography. *AJNR* 1982;3:59-64
- Liboni W, Benna P, Duca S, Fra L, Sicuro A. Electrophysiological (EEG, BAEP, VEP, H reflex) patterns in myelography with nonionic water-soluble contrast media. *Neuroradiology* 1982;22:277-278