

Are your **MRI contrast agents** cost-effective?

Learn more about generic **Gadolinium-Based Contrast Agents**.



FRESENIUS  
KABI

caring for life

# AJNR

## **Discrepancy between metrizamide CT and myelography in diagnosis of cervical disk protrusions.**

H Nakagawa, T Okumura, T Sugiyama and K Iwata

*AJNR Am J Neuroradiol* 1983, 4 (3) 604-606

<http://www.ajnr.org/content/4/3/604>

This information is current as of May 13, 2024.

# Discrepancy between Metrizamide CT and Myelography in Diagnosis of Cervical Disk Protrusions

Hiroshi Nakagawa,<sup>1</sup> Terufumi Okumura, Tadamitsu Sugiyama, and Kinjiro Iwata

**With the advent of the relatively safe water-soluble contrast medium metrizamide, cervical myelography followed by metrizamide computed tomography (CT) can be performed easily. Sixteen patients with cervical disk protrusions (eight central and eight posterolateral) were studied by both procedures to evaluate the diagnostic value of each. In 75% of the posterolateral disk protrusions, myelography was as diagnostic as metrizamide CT. Metrizamide CT was definitely superior to myelography in 75% of the central disk protrusions with delineation of compressed cord. Information provided by metrizamide CT is detailed enough to allow the selection of a definitive anterior approach without delay.**

Cervical disks (particularly large midline disks) may produce clinical syndromes similar to those of spinal cord tumors and degenerative diseases [1–4]. But plain myelography of the region can sometimes be misleading [5, 6]. In recent years metrizamide, a water-soluble contrast medium, has been more widely accepted and used for cervical myelography, and with better results [7–10]. However, while cervical myelography with metrizamide (done either via a lumbar route or a lateral C1–C2 puncture) is mostly satisfactory, it is still not always conclusive. For the past 2 years we have routinely carried out metrizamide computed tomography (CT) after conventional myelography. This paper reports on the diagnostic accuracy of each method in cases of cervical disk protrusions.

## Materials and Methods

Sixteen patients with cervical disk protrusions were studied with metrizamide CT and myelography. Lumbar puncture was used in all but three cases. Lateral C1–C2 puncture was used in two cases in which previous myelography via a lumbar route was unsatisfactory, and in one case in which kyphosis in the upper thoracic spine was prominent. Two vials of 270 mg I/ml metrizamide was injected intrathecally. Anterolateral and lateral views in hyperextension and neutral positions were routinely taken, and cross-table oblique projection was used as necessary (especially in cases of small posterolateral disks).

Following myelography, CT was performed with the patient's head in neutral or slightly extended position. Five mm contiguous slices with 3 mm overlaps were taken from T1 to C2. Of 16 cases, eight were found to have centrally protruding disks and eight had posterolateral disk protrusions.

## Results

Myelography showed partial block in six cases (four central and two posterolateral) and anterior defects in 10 cases (four central and six posterolateral). When metrizamide CT was performed, disk herniations were clearly delineated by contrast material in the subarachnoid space, and the size and the direction of the disk were correctly diagnosed.

CT visualized 12 central disk herniations: three at C3–C4, five at C4–C5, and four at C6–C7. Three patients had only one central herniation, two had two central herniations, and three had central and posterolateral herniations. Of the 12 posterolateral disk herniations seen by CT, one was at C3–C4, one at C4–C5, seven were at C5–C6, and three at C6–C7. Five patients had only one posterolateral herniation, two had two posterolateral herniations, and three had both posterolateral and central herniations. Spondylotic spurs at the level of the disk herniations were found in eight of 12 posterolateral cases but in only three of 12 central ones, although bony spurs of various degrees were present at other levels in most cases. Except for two small posterolateral herniations treated conservatively, all were confirmed surgically by the anterior approach.

In nine (75%) of 12 central disk herniations, metrizamide CT proved to be superior to conventional myelography. In the other three, metrizamide CT was as diagnostic as myelography. On the other hand, in nine of 12 posterolateral disk herniations diagnostic accuracy of each procedure was almost equal. Metrizamide CT was superior in two and inferior in one.

## Representative Case Reports

### Case 1.

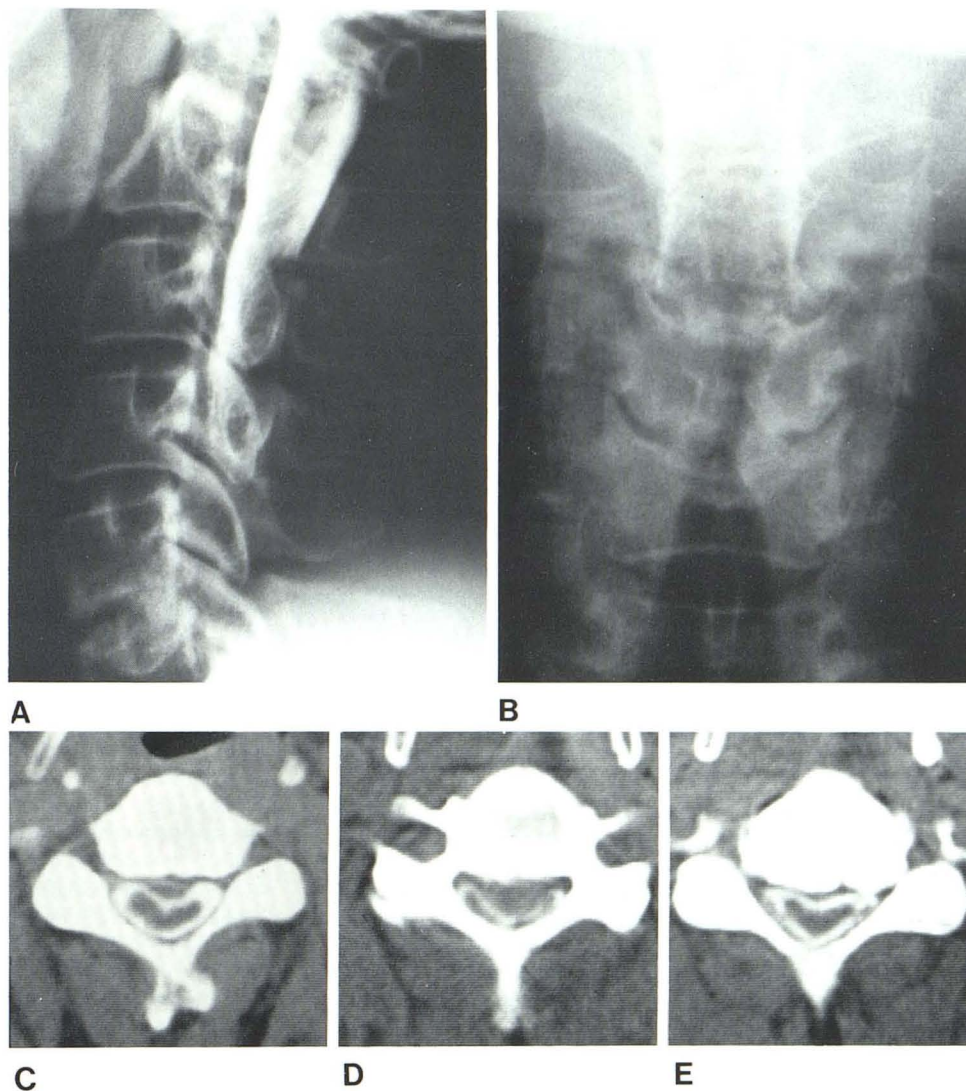
A 53-year-old man underwent anterior fusion at C5–C6 5 years before without any improvement in numbness of four extremities. He was admitted to our hospital because of progressive gait disturbance, numbness of legs, and dysuria for the last year. Neurologic examination revealed moderate to marked quadriparesis predominantly on the left, severe spastic and paretic gait, generalized hyperreflexia, sensory level at T8 bilaterally, hypalgesia at C6 on the right and at C6–C8 on the left, and impairment of position and vibration senses in the lower extremities.

Plain films of the cervical spine showed bony fusion at C5–C6 and slight spur and stenosis at C4–C5. Myelography with metrizamide injected from C1–C2 lateral puncture disclosed a severe block

<sup>1</sup> All authors: Department of Neurological Surgery, Aichi Medical University, Nagakute-cho, Aichi-gun, Aichi-ken, Japan 480-11. Address reprint requests to H. Nakagawa.



Fig. 1.—Case 1. Central disk protrusions. **A** and **B**, Cervical myelograms. **A**, Lateral projection (via C1–C2 lateral puncture). **B**, Anterolateral projection. Almost complete block at C4–C5 with widening of cord. Cause of block is not clarified. **C–E**, Metrizamide CT. **C**, at C3–C4. Midline disk of moderate size, not shown by myelography, is now clearly visualized. **D**, At C4–C5. Large central disk with severe cord compression. **E**, At C5–C6. Cord moderately compressed by osteophytes and slightly narrowed canal.



at C4–C5, with widening of the cord in an anterolateral projection (fig. 1). From these myelographic findings it was rather difficult to make a definite diagnosis and to rule out the possibility of a spinal cord tumor. However, metrizamide CT immediately after myelography enabled us to diagnose a large central disk herniation at C4–C5 with severely compressed cord. In addition to this there were a moderate size midline herniation at C3–C4, where myelography showed no anterior defect, and spondylotic spur with cord compression at C5–C6. From this information, anterior approach was selected and microdiskectomy at C3–C4 and C4–C5 and removal of bony spurs at C5–C6 were carried out. Postoperatively the patient made a remarkable improvement.

#### Case 2

A 45-year-old woman developed a persistent pain in her right shoulder and scapular area and occasional radicular pain to the right hand with numbness and weakness after a softball injury 2 years before. On neurologic examination there was mild weakness of right triceps, pronator, and intrinsic muscles; a depressed triceps

reflex bilaterally; increased knee jerks; and mild hypalgesia in right C6, C7, and C8 distributions. Cervical myelography via a lumbar route showed an anterior defect at C6–C7 (fig. 2). Metrizamide CT confirmed a small posterolateral disk herniation at C6–C7 on the right with slight cord compression and shift of anterior median raphe. In this case myelography and metrizamide CT were almost equally diagnostic, although each image represented a different dimension of the lesion. A posterolateral disk herniation was found and removed by anterior microdiskectomy without bony fusion.

#### Discussion

Cervical central disk herniation has been reported to constitute only 1% of cervical disk surgery [3]. Although there may be marked variability in clinical manifestation, central cervical disk herniations are characterized by spasticity and hyperreflexia in the lower extremities, unsteady gait, mild and poorly defined sensory disturbance, and relatively mild weakness of the upper extremities, with occasional distal atrophy [1, 2, 5]. Neck pain or antecedent trauma is rarely present. Therefore, the differential diagnosis from spinal



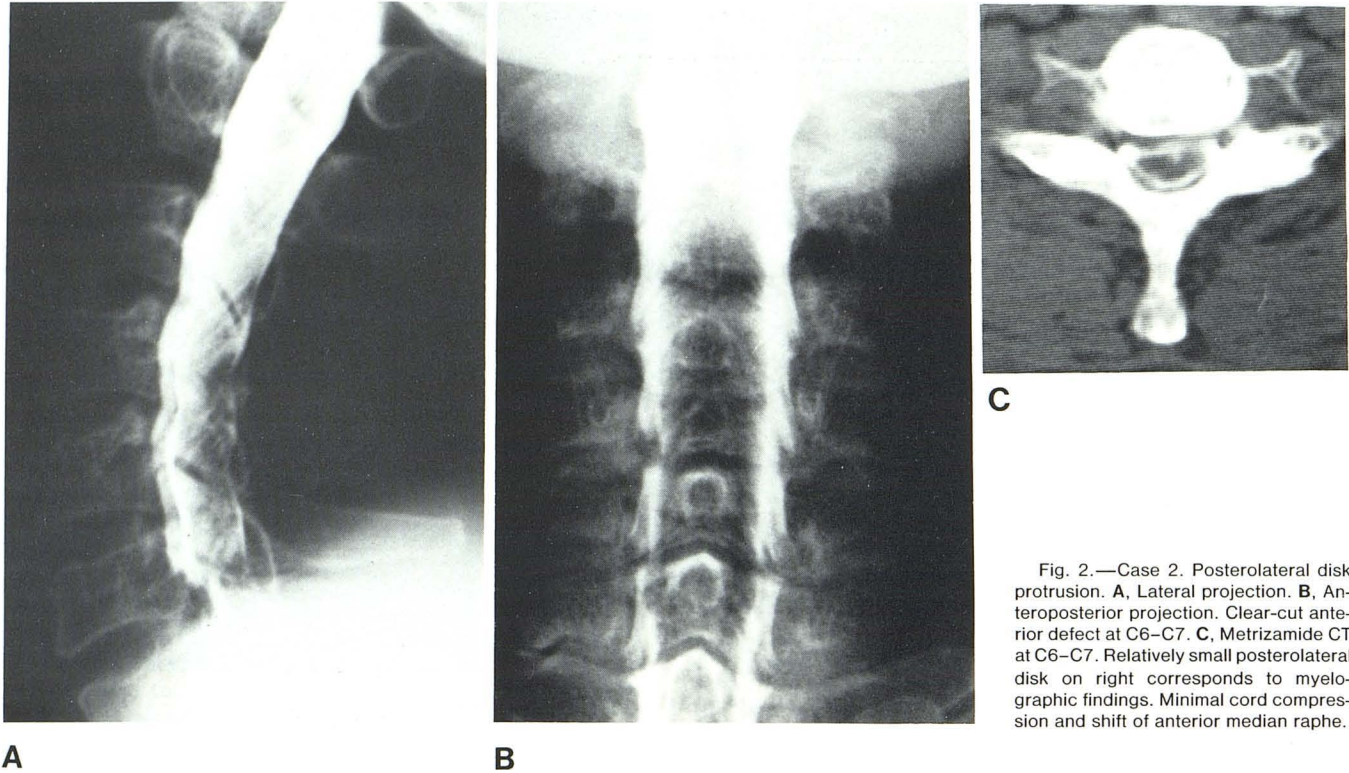


Fig. 2.—Case 2. Posterolateral disk protrusion. **A**, Lateral projection. **B**, Anteroposterior projection. Clear-cut anterior defect at C6–C7. **C**, Metrizamide CT at C6–C7. Relatively small posterolateral disk on right corresponds to myelographic findings. Minimal cord compression and shift of anterior median raphe.

cord tumors, multiple sclerosis, primary lateral sclerosis, or amyotrophic lateral sclerosis is often difficult [2].

Myelography has been the procedure of choice in these cases, but it can sometimes be misleading because of a block, which, if present, may be one level below the actual disk protrusion [5]. Since the possibility of spinal cord tumors cannot be excluded, posterior exploration (which may be a wrong approach for central disk herniations) is sometimes performed [3, 5]. While it does have some advantages over Pantopaque myelography, metrizamide myelography does not solve the problem [10].

CT allows the visualization of a large midline cervical disk herniation [11], but CT diagnosis of cervical disk herniations is not as reliable as it is for lumbar disk herniations.

Although high-resolution CT with thin slices and scan projection radiography has increased diagnostic accuracy [12], metrizamide CT after myelography is more reliable than plain CT. Furthermore, we found that in diagnosis of central disk protrusions metrizamide CT was superior to conventional myelography in 75% of the cases. Metrizamide CT also enabled us to rule out the possibility of cord tumors, and to select a proper surgical approach. In most of the cases remarkable improvement was seen after anterior microdiscectomy.

Cervical canal stenosis (noted in three of our cases of central disk herniations) is probably a significant factor for the development of severe myelopathy [5]. The degree of cord compression is easily detected by CT, and shift of the anterior median raphe may be a useful sign.

Finally, in contradistinction to central protrusions, in the diagnosis of posterolateral disk protrusions, metrizamide myelography was as diagnostic as metrizamide CT in 75% of the cases.

We believe that if metrizamide CT is routinely performed following myelography, cervical disk protrusions, especially central herniations which have been considered a rare entity, will be correctly diagnosed and can be properly treated without delay.

#### REFERENCES

1. Stookey B. Compression of spinal cord and nerve roots by herniation of the nucleus pulposus in the cervical region. *Arch Surg* 1940;40:417–432
2. Bucy PC, Heimburger RF, Oberhill HR. Compression of the cervical spinal cord by herniated intervertebral discs. *J Neurosurg* 1948;5:471–492
3. Scoville WB. Types of cervical disk lesions and their surgical approaches. *JAMA* 1966;196:479–481
4. Yuhl ET, Hanna D, Rasmussen T, Richter RB. Diagnosis and surgical therapy of chronic midline cervical disk protrusions. *Neurology (NY)* 1955;5:494–509
5. Lourie H, Shende MC, Stewart DH. The syndrome of central cervical soft disk herniation. *JAMA* 1973;226:302–305
6. Epstein BS. *The spine. A radiological text and atlas*, 4th ed. Philadelphia: Lea and Febiger, 1976:666–675
7. Skalpe IO, Amundsen P. Thoracic and cervical myelography with metrizamide, clinical experiences with a water soluble, nonionic contrast medium. *Radiology* 1975;116:101–106
8. Sackett JF, Strother CM, Quagliari CE, Javid MJ, Levin AB, Duff TA. Metrizamide—CSF contrast material. Analysis of clinical application in 215 patients. *Radiology* 1977;123:779–782
9. Bord WR, Gardiner GA. Metrizamide myelography. *AJR* 1977;129:481–484
10. Sackett JF, Strother CM. *New techniques in myelography*. New York: Harper & Row, 1979:110–121
11. Nakagawa H, Malis LI, Huang YP. Computed tomography of soft-tissue masses related to the spinal column. In: Post MJD, ed. *Radiographic evaluation of the spine*. New York: Masson, 1980:320–352
12. Coin CG, Coin JT. Computed tomography of cervical disc disease: technical considerations with representative case reports. *J Comput Assist Tomogr* 1981;5:275–280