

Are your MRI contrast agents cost-effective?
Learn more about generic Gadolinium-Based Contrast Agents.



AJNR

Transluminal angioplasty in postsurgical stenosis of the extracranial carotid artery.

A L Tievsky, E M Druy and J G Mardiat

AJNR Am J Neuroradiol 1983, 4 (3) 800-802
<http://www.ajnr.org/content/4/3/800>

This information is current as of May 14, 2024.

Transluminal Angioplasty in Postsurgical Stenosis of the Extracranial Carotid Artery

Andrew L. Tievsky,¹ Edward M. Druy, and John G. Mardiat

Transluminal angioplasty of the common carotid artery was beneficial in a patient with postendarterectomy recurrent stenosis due to fibrous myointimal hyperplasia. This lesion is the major cause of restenosis within the first 24 postoperative months and has histologic characteristics quite favorable for angioplasty with minimal possibility for embolic complications. Since surgery is a proven procedure with low morbidity/mortality for most patients, the authors believe transluminal angioplasty for carotid restenosis should be limited to surgically inaccessible lesions or patients presenting unacceptable operative risk, as in the case described.

Since the availability of the double-lumen balloon catheter, percutaneous transluminal angioplasty (PTA) has gained wide acceptance for dilatation in occlusive disease, most often atherosclerosis, of the coronary, renal, visceral, aortoiliac, and peripheral vasculature. Because of the risk and catastrophic consequences of cerebral embolization, treatment of brachiocephalic vascular stenosis is rarely attempted. However, scattered case reports in small series of patients have demonstrated PTA to be safe therapy for fibromuscular dysplasia of the internal carotid artery [1, 2] and atherosclerotic stenoses of the vertebral orifices, proximal left subclavian artery, and external carotid artery [3, 4]. We report the successful application of PTA in a case of postoperative common carotid stenosis due to fibrous myointimal hyperplasia.

Case Report

A 63-year-old white woman presented in June 1981 with daily transient ischemic attacks. Generalized cerebral ischemia was suggested by occasional bouts of transient somnolence, disorientation, expressive aphasia, and dizziness. These episodes were incapacitating and on one occasion precipitated an automobile accident. The medical history included a myocardial infarction in 1970 and four-vessel coronary artery bypass graft in 1978. There was no angina or congestive heart failure on admission, but the patient had a ventricular arrhythmia requiring pharmacologic therapy. There was a history of moderate, controlled hypertension and mild, adult-onset diabetes. The patient was a 60-pack/year cigarette smoker.

The neurologic examination was normal. The only pertinent physical finding was a left carotid bruit. Cranial computed tomography (CT) showed minimal atrophy but no infarction. Complete cerebral angiography revealed extensive extracranial atherosclerotic disease (fig. 1). The right internal carotid artery was totally occluded at its origin with minimal external-to-internal collateral flow. There was short-segment 95% stenosis at the origin of the left internal

carotid artery, but significant collateral flow to the right cerebral vessels. Aortic arch injection showed severe narrowing of the right vertebral artery orifice and a diminutive left vertebral artery that was completely occluded in its midportion. Minimal intracranial atherosclerotic disease was noted. The patient underwent uneventful left carotid endarterectomy resulting in total resolution of her symptoms and disappearance of the bruit.

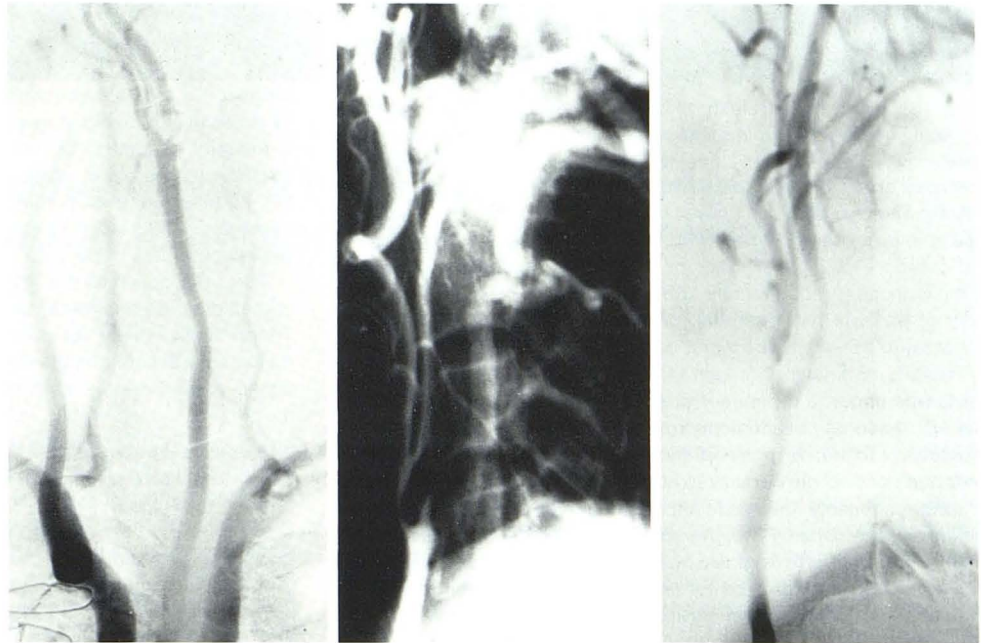
Five months later, in November 1981, the patient's symptoms reappeared and a left-sided bruit was found. Oculoplethysmography (OPG) showed decreased pressure on the left. Intravenous digital subtraction angiography (DSA) was unsuccessful because of patient motion. Arteriography revealed narrowing of the left distal common carotid artery and a 3 cm segment of high-grade stenosis in the proximal left internal carotid artery at the site of the previous arteriotomy (fig. 2). The patient underwent repeat left internal carotid endarterectomy with saphenous vein angioplasty. Fibrous intimal hyperplasia without atheroma was noted in the area of stenosis. Recovery was complicated by paresis of tongue musculature innervated by the left hypoglossal nerve, resulting in minimal dysarthria and dysphagia. Ventricular arrhythmia required intravenous lidocaine on the first postoperative day. Discharge medications included aspirin and Persantine. Surgery was judged successful in view of improvement in left ocular pressure on OPG and disappearance of ischemic episodes.

Three and one-half months later, the patient again developed nearly identical symptoms. OPG revealed severe reduction in ocular pressures bilaterally, with the left side considerably lower than the right (86 and 106 mm Hg, respectively). Repeat arteriography demonstrated the graft to be patent, although the external carotid branches did not fill (figs. 3A and 3B). The most significant finding was a fusiform, smooth narrowing of a 2 cm segment of the left common carotid artery with 90% stenosis (fig. 3C). This lesion was thought to represent fibrous intimal hyperplasia resulting from unrecognized clamp injury during the second procedure.

The patient was considered a poor operative risk for a third procedure and thus was referred for transluminal angioplasty in June 1982. She was premedicated with aspirin and Persantine and systemically heparinized (4,000 U) after the arterial puncture. After routine catheterization of the left common carotid artery, the skin was marked with a radiopaque marker at the site of stenosis. A 7 French polyethylene Grüntzig-type balloon catheter 4 mm in diameter (Medi-Tech) was exchanged over a 260 cm wire. To limit vascular trauma and avoid total carotid occlusion, pressure tracings were not obtained. The wire was advanced through the narrowed region into the patent graft. Then the balloon was positioned in the stenotic segment and inflated under fluoroscopic control to 5 atmospheres of pressure for 20 sec. After deflation, the balloon

¹All authors: Radiology, George Washington University Medical Center, 901 23rd St., N.W., Washington, DC 20037. Address reprint requests to A. L. Tievsky.

Fig. 1.—Initial preoperative arteriograms. **A**, Aortic arch injection. Severe narrowing of right vertebral orifice and distal occlusion of left side. High-grade atheromatous stenosis of left internal carotid artery. **B**, Right subclavian injection. Internal carotid artery is totally occluded. Marked narrowing of external branch.

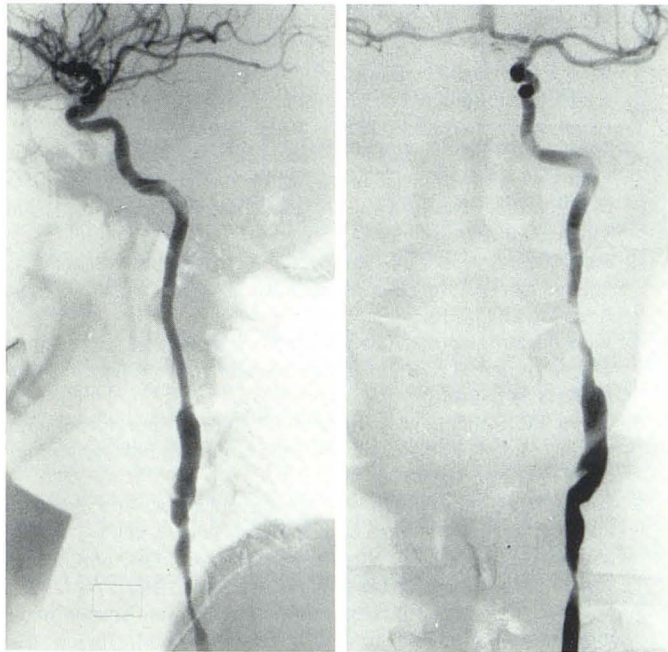


1A

1B

2

Fig. 2.—Arteriogram before second operation. High-grade concentric stenosis in 3 cm segment of proximal left internal carotid. Typical appearance of fibrointimal hyperplasia was confirmed by surgery.

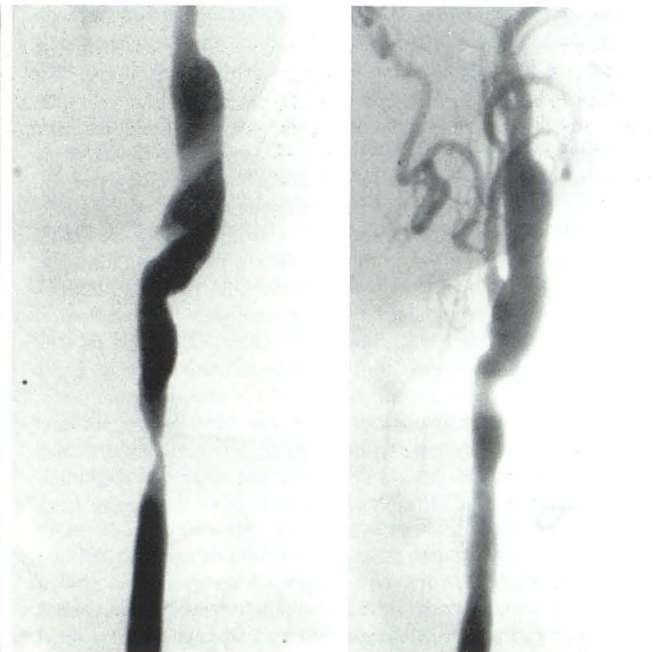


3A

3B

3C

Fig. 3.—Arteriograms obtained 4 months after second operation. **A** and **B**, Oversize saphenous vein angioplasty is patent. External carotid branches are not opacified. **C**, New concentric narrowing of 2 cm segment of left common carotid artery.



4

Fig. 4.—Postangioplasty. Considerable increase in arterial lumen diameter with small intimal tear. Filling of external carotid circulation, possibly attributable to inadvertent angioplasty by guide wire within graft during catheter exchange.

catheter and wire were withdrawn proximal to the lesion. Angiography demonstrated arterial dilatation with residual 20% narrowing and a small intimal tear, as well as an unexpected (and unexplained) benefit, namely, antegrade filling of the left external carotid arterial circulation (fig. 4). The patient remained asymptomatic during the

procedure. OPG showed ocular pressures to be symmetric but reduced (81 mm Hg bilaterally). The loud left carotid bruit disappeared and a strong left temporal pulse developed. At 4 months post-PTA, the patient was reported to be fully ambulatory with no recurrence of ischemic symptomatology or bruit.

Discussion

The primary complications of carotid endarterectomy are myocardial infarction and stroke. According to the estimation of Sundt et al. [5], morbidity/mortality is 1% for a patient without serious medical, neurologic, or angiographic risk factors. However, this patient was neurologically unstable and had medical risk due to coronary artery disease with unstable arrhythmia. There was significant angiographic risk as well in view of occlusion of the contralateral internal carotid artery. Accordingly, our patient belonged in the category of highest risk, for which the incidence of serious complications (predominantly stroke) may exceed 10%. This category of patients has potential for dramatic recovery if surgery is successful, as well as the worst prognosis if left untreated.

There is no known increase in major morbidity/mortality in patients who undergo repeat surgical procedures for restenosis (Callow AD, personal communication). However, because of the sharp dissection technique required, there is an increase in incidence of peripheral cranial nerve palsy to about 10%. The hypoglossal nerve is most commonly involved, although function generally returns within a year (Stoney RJ, personal communication). Since our patient had partial hypoglossal paresis after the second surgery, PTA was chosen in preference to a third surgical procedure. The most feared complication of carotid PTA is thromboembolic stroke. Angiographically observed embolization, usually asymptomatic, occurs during 5% of peripheral and visceral angioplasties. However, these procedures are usually performed for atherosclerotic obstructions [6].

The exact incidence of postoperative carotid stenosis is unknown. Angiography is not performed in many cases, and the diagnosis is made on the basis of symptoms or various noninvasive tests such as OPG, phonoangiography, and carotid sonography. However, a 1980 survey of the combined experience of 50 vascular surgeons reported a restenosis in 152 of 13,470 operations, an overall incidence of 1.13%. Although rates of 10% have been reported, most well documented series record an incidence of 1%–3% [7]. Most patients with restenosis are symptomatic, but at least 30% are not. It is not known whether this group is predisposed to development of fixed stroke. In future, the use of intravenous DSA should facilitate the evaluation of asymptomatic patients with restenosis and help to elucidate the natural course of this problem.

In a review of nearly 1,500 patients who had undergone carotid endarterectomy, Stoney and String [8] distinguished late from early carotid restenosis by a cut-off point of 24 months postsurgery. Cases of late restenosis are pathologically identical to primary atherosclerotic disease. On the other hand, restenosis within the first 24 postoperative months is characterized by myointimal fibroblastic proliferation without the lipid-laden cells or foam cells seen in atherosclerosis. Absence of neovascularization, hemosiderin, or fibrin deposition excludes organized thrombus as an etiology. The characteristic appearance is that of stellate cells enmeshed in a fibromyxomatous stroma. Grossly this lesion, termed fibrous intimal hyperplasia, is pearly white, glistening, and smooth on its luminal surface, blending imperceptibly without cleavage plane into the adjacent normal arterial wall. There is none of the irregularity, ulceration, or debris associated with atheromatous plaques [8].

Fibrous intimal hyperplasia apparently develops as an exuberant healing response to minor vascular trauma [7]. Faults in suturing technique, incomplete removal of intimal or medial tags, residual

tongue of plaque, and inadvertent clamp injury have all been implicated. Local turbulence may enhance the fibrous hyperplastic reaction, leading to stenosis. Constitutional factors such as intrinsic platelet or fibroblast abnormalities contributing to the development of excessive myointimal response are suspected, but unproven, in a minority of cases. On the other hand, late arterial restenosis appears to represent progression of generalized atherosclerosis [9]. Whether the evolutionary course of fibrous intimal hyperplasia culminates in atheroma is a subject of considerable debate beyond the scope of this paper [9].

The prerequisites of a vascular lesion optimal for transluminal angioplasty are a smooth, noncalcified, and concentric narrowing. Theoretically, these features should minimize the possibilities of balloon or adventitial rupture and leave a smooth, nonthrombogenic lumen. A short-segment stenosis allows for radial force without axial movement, considerably reducing intimal trauma. High-velocity blood flow and the absence of significant downstream disease play an important role in preventing thromboembolic phenomena. Fibrointimal hyperplasia generally meets all these criteria.

Surgery of recurrent carotid stenosis is a proven procedure associated with small risk for most patients. It is possible that PTA will become the treatment of choice for carotid intimal fibrous hyperplasia, with reoperation reserved for failures. However, until such time as significant numbers of cases have been treated and the safety and long-term efficacy of the procedure are established, we believe PTA for carotid stenosis should be limited to surgically inaccessible lesions or patients presenting unacceptable operative risk.

REFERENCES

1. Hasso AN, Bird RC, Zinke DE, Thompson JR. Fibromuscular dysplasia of the internal carotid artery: percutaneous transluminal angioplasty. *AJR* 1981;136:955–960
2. Belan A, Vesela M, Vanek I, Weiss K, Peregrin JH. Percutaneous transluminal angioplasty of fibromuscular dysplasia of the internal carotid artery. *Cardiovasc Intervent Radiol* 1982;5:79–81
3. Motarjeme A, Keifer JW, Zuska AJ. Percutaneous transluminal angioplasty of the brachiocephalic arteries. *AJNR* 1982;3:169–174
4. Vitek JJ, Morawetz RB. Percutaneous transluminal angioplasty of the external carotid artery: preliminary report. *AJNR* 1982;3:541–546
5. Sundt TM, Sandok BA, Whisnant JP. Carotid endarterectomy: complications and preoperative assessment of risk. *Mayo Clin Proc* 1975;50:301–306
6. Waltman AC, Greenfield AJ, Athanasoulis CA. Transluminal angioplasty: general rules and basic considerations. In: Athanasoulis CA, Pfister RC, Green RE, Roberson GH, eds. *Interventional radiology*. Philadelphia: Saunders, 1982:253–272
7. McBride K, Callow AD. Recurrent stenosis after carotid endarterectomy: a limited survey. In: Bernhard VM, Towne JB, eds. *Complications in vascular surgery*. New York: Grune & Stratton, 1980:259–273
8. Stoney RJ, String ST. Recurrent carotid stenosis. *Surgery* 1976;80:705–710
9. Callow AD. Recurrent stenosis after carotid endarterectomy. *Arch Surg* 1982;117:1082–1085