

# Computed Tomography of Ocular Colobomas

John D. Simmons<sup>1, 2</sup>  
David LaMasters<sup>1, 3</sup>  
Devron Char<sup>4</sup>

Typical ocular colobomas and associated orbital cysts are relatively common malformations that result from a defect in the fusion of the fetal optic fissure. Three cases studied with computed tomography (CT) are reported, and the spectrum of ocular colobomas, their associated findings, and CT differential diagnosis are reviewed. This experience indicates that the location and extent of colobomas can be determined with high-resolution CT.

Abnormal closure of the fetal optic fissure along the eye and optic nerve results in a malformation of the eye termed *ocular coloboma*, consisting of localized defects in the uvea, retina, and optic nerve. Variability in the position and size of the defects leads to a spectrum of deformities. Clinically these defects may produce visual field scotoma; ophthalmoscopically the sclera is visible because of the absence of overlying uveal tract and retina [1]. We report three cases of ocular colobomas and demonstrate the computed tomographic (CT) findings observed in this entity.

## Case Reports

### Case 1

A 12-year-old boy presented with delayed growth and learning and long-standing right esotropia. Family history revealed no ocular abnormalities. Right eye vision was finger counting only; the left eye vision was normal. The right eye had a small cornea and an inferior uveal, retinal, and optic disk coloboma. Orbital CT demonstrated the extent of the coloboma (fig. 1). The posterior globe had a conal configuration, the apex extending into the optic nerve. Both optic nerves were small. The left eye appeared normal. No midline abnormalities were seen within the brain.

### Case 2

A 6-month-old girl was admitted for evaluation of a left orbital mass. The mass was observed at birth and progressively enlarged. On examination she had microcephaly and broad, radially placed thumbs, consistent with Rubenstein-Taybi syndrome. The left eye was small and inferiorly displaced by a palpable orbital mass. There were bilateral inferior iris colobomas. The left fundus could not be visualized. The right fundal examination showed a large right coloboma involving the optic disk.

Orbital CT (fig. 2) demonstrated a microphthalmic left eye displaced inferiorly by a large homogeneously low-density mass. The mass nearly filled the orbit and caused expansion of the lateral orbital wall. The right eye appeared elliptical; a small low density protruded posteriorly in the area of the optic disk and distal optic nerve. This low-density protrusion was continuous with the vitreous cavity and was bounded by the higher density sclera. The findings were interpreted as left microphthalmus with an orbital cyst and a small coloboma of the right optic disk and nerve. The infant had repeated cyst aspirations of hemorrhagic fluid and eventually cyst removal.

This article appears in the September/October 1983 issue of *AJNR* and the December 1983 issue of *AJR*.

Received June 3, 1982; accepted after revision November 18, 1982.

D. Char is a recipient of a National Institutes of Health research career development award KO4-EYO 0117.

This work was supported in part by an unrestricted grant from That Man May See and from National Institutes of Health grants EYO 1441, EYO 1759, and EYO 3675.

<sup>1</sup>Department of Radiology, Moffitt Hospital, University of California, San Francisco, CA 94143.

<sup>2</sup>Present address: Department of Radiology, Hillcrest Medical Center, Utica on the Park, Tulsa, OK 74104. Address reprint requests to J. D. Simmons.

<sup>3</sup>Present address: Department of Radiology, Wilford Hall USAF Medical Center, Lackland AFB, TX 78236.

<sup>4</sup>Department of Ophthalmology, Ocular Oncology Unit, University of California, San Francisco, CA 94143.

*AJNR* 4:1049-1052, September/October 1983  
0195-6108/83/0405-1049 \$00.00  
© American Roentgen Ray Society

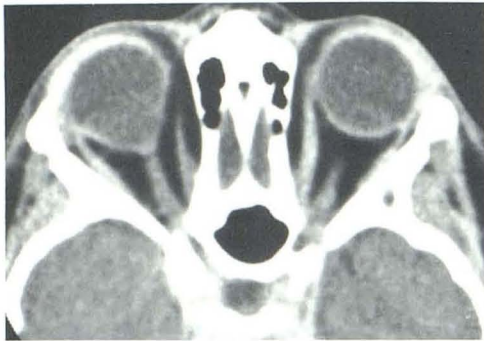
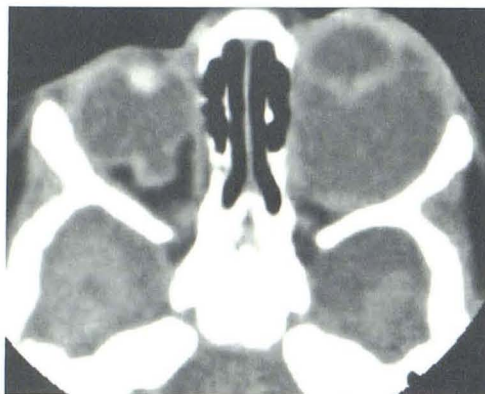
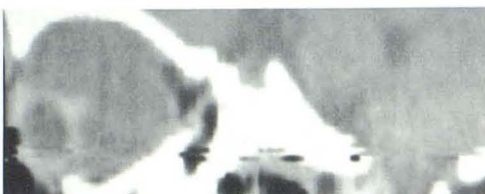Fig. 1.—Case 1. Coloboma of optic disk. Axial scan through orbit shows conal appearance of colobomatous right globe. Coloboma directly communicates with vitreous cavity and has same CT attenuation.



A



B



C

Fig. 2.—Case 2. Microphthalmus with orbital cyst and coloboma. A, Left eye is microphthalmic. Posterior to globe lies large orbital cyst, which expands orbit and displaces globe anteriorly. Right globe is normal in size but demonstrates small coloboma in optic disk region. Parasagittal reformations demonstrate extent of coloboma (B) and orbital cyst (C).

#### Case 3

A 5-month-old boy with multiple congenital anomalies was evaluated for progressive bilateral proptosis. The parents had noted that the infant seemed unresponsive to visual stimuli. Ophthalmology

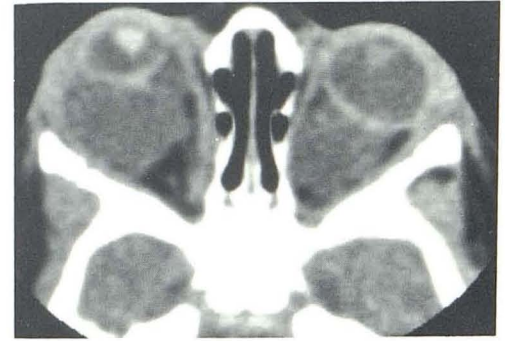


Fig. 3.—Case 3. Microphthalmus with cyst. Bilateral orbital cysts. Larger right cyst is associated with microphthalmus and expansion of orbit. Left globe has elliptical shape and normal size.

scopically bilateral white pupillary reflexes were observed. The right globe was microphthalmic. Bilateral large colobomas were also noted. CT (fig. 3) confirmed a microphthalmic right globe and bilateral orbital cysts larger on the right than on the left. The right orbit was expanded. The posterior aspect of both globes appeared funnel-shaped, consistent with the clinical impression of bilateral colobomas. The orbital cysts were subsequently decompressed by percutaneous aspiration.

#### Discussion

Colobomas are relatively common eye and orbital malformations that may occur as an isolated finding or as part of a syndrome [2, 3]. They account for about 2% of all congenital malformations of the eye [2]. Coloboma refers to a congenital or acquired "notch, gap, hole, or fissure in any ocular structures"[4]. They are classified as typical or atypical by their location and derivation [2, 4]. Typical colobomas result from a variable lack of fusion of the fetal optic fissure, which extends inferonasally along the optic nerve and globe. Atypical colobomas, which are not considered in this report, occur in the iris; they may result from abnormal secondary fetal fissures; they are not the result of a defect in the fusion of the fetal optic fissure. There is no known association of typical and atypical colobomas because of their different locations and derivations [3].

Ocular colobomas occur as a result of an embryologic developmental defect. The eye and optic nerve originate from the fetal optic vesicle. During embryogenesis, the optic vesicles undergo two types of invagination [5]. There is approximation of the outer layer (future neurosensory retina) to the inner layer (future retinal pigmented epithelium) to form the optic cup. Simultaneously, there is invagination along the inferior medial aspect of the optic cup and stalk to create the fetal or embryologic fissure. This fissure extends along the optic cup and stalk from the distal optic cup (future iris) to the distal optic nerve (future optic disk area).

Normally, the two retinal layers at the fetal fissure oppose one another. The layers fuse, making the neurosensory and pigmented retina complete. Colobomas probably occur when there is overgrowth and accentuated eversion of the inner layer of the retina at the fissure (fig. 4), which disrupts normal apposition and fusion [2, 4]. The longitudinal extent



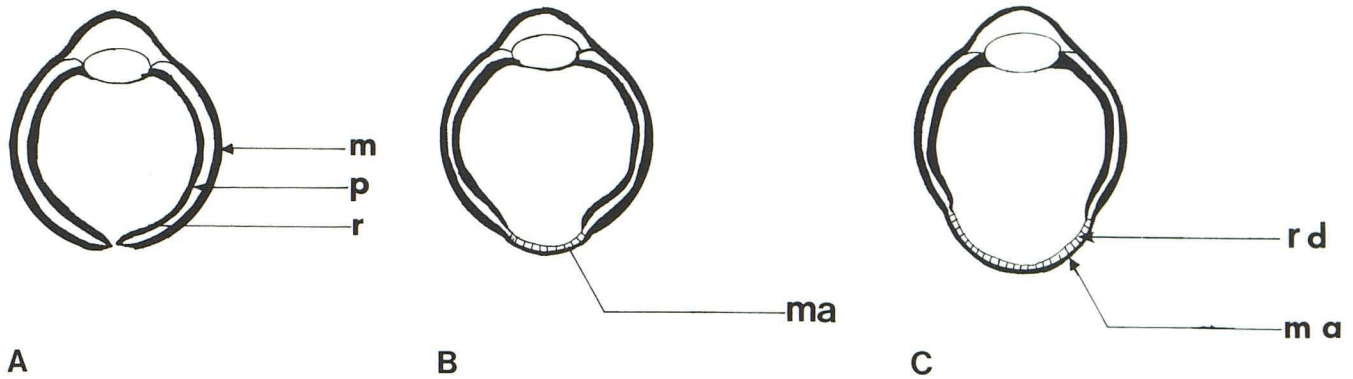


Fig. 4.—Coloboma development. **A**, Normally a fissure forms through developing layers of globe and optic nerve. These layers are neurosensory retina (r), pigmented choroid (p), and mesenchymal sclera (m). Subsequently these layers normally appose and fuse. If there is proliferation of the neurosensory retina, this normal process is disrupted. **B** and **C**, Abnormal apposition and fusion result in variably sized focal retinal degeneration (rd) and mesenchymal scleral atrophy (ma). Atrophy weakens posterior globe and leads to focal bulging and global elongation.

and location of the abnormal fissure fusion determines which of the eye structures are included in the coloboma. The posterior globe and adjacent optic nerve are involved most often. The shape of the globe or optic nerve colobomas is related to the extent of the retinal eversion. Mild retinal eversion causes focal bulging of the globe or nerve as in case 2 (fig. 2). More extensive eversion (fig. 4C) causes the globe to elongate as in case 1 (fig. 1).

Retinal cysts may be formed along with a coloboma if there is very extensive retinal proliferation and separation of the inner and outer retinal layers (fig. 5) [2, 4]. These cysts communicate with the space between the two retinal layers that surround the remaining globe. With further growth and development, the cysts may fuse into a single larger cyst, or occasionally the wall of the cyst and globe fuse to form a direct communication between the cyst and vitreous cavity. While the cysts may be small and subclinical, they often are large with displacement of the globe and variable degrees of microphthalmus [6, 7].

Colobomas are transmitted as an autosomal dominant with variable penetrance and are bilateral in about 60% of cases [3]. Orbital cysts may be unilateral or bilateral. The genders are affected equally. Although small colobomas and cysts may be clinically undetectable, their appearance ophthalmoscopically is often striking (fig. 6). Typically, the inferior medial fundus is replaced by a white wedge-shaped area of atrophic sclera. This part of the globe is depressed and may be very ectatic. The visual field examinations are abnormal, and visual acuity is often diminished because the retina is atrophic in the area of the coloboma. If an orbital cyst is present there is usually globe displacement, proptosis, and microphthalmus.

The appearance of colobomas on CT is varied. Two broad groups with overlap occur: those related to the ocular coloboma and those related to the orbital cyst.

Ocular coloboma presents as a malformed globe. The posterior globe may be elongated or conal, as in case 1, or even very locally deformed, as in case 2. It is rare for colobomas to be restricted to the optic nerve; however, nerve involvement, as in case 2, is quite common [2]. The

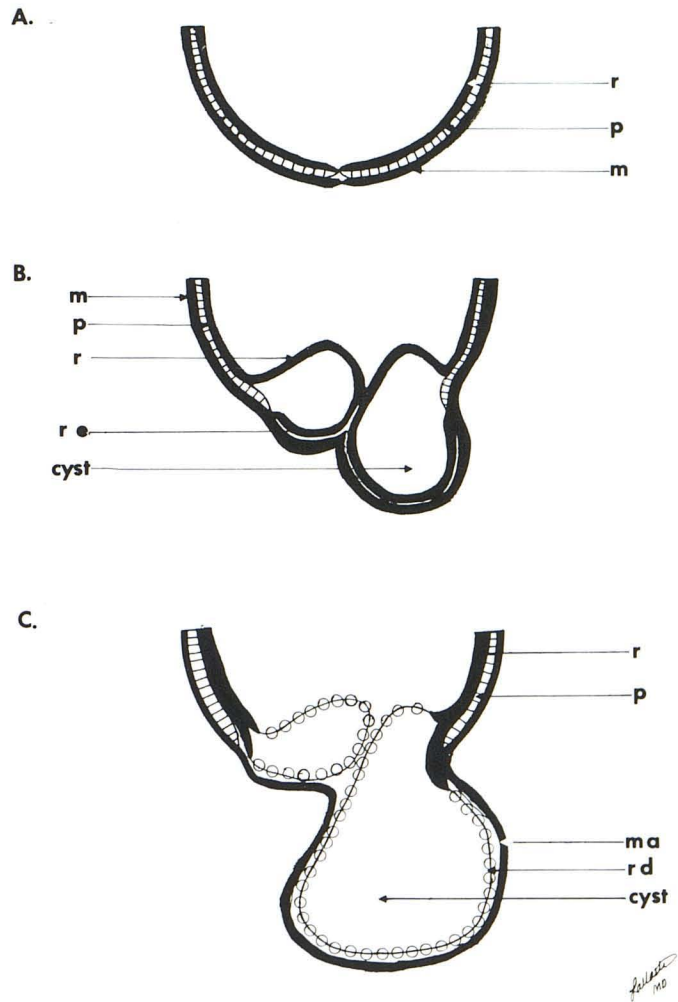


Fig. 5.—Retinal cyst formation. **A**, Normal alignment of neurosensory retina (r), pigmented choroid (p), and mesenchymal sclera (m) at fetal fissure. **B**, Abundant retinal proliferation leads to neurosensory retinal eversion (re) at fissure. Separation of retinal layers causes potential spaces or cysts. These fill with serous transudates. **C**, Subsequently retina degenerates (rd) in this area leaving thin atrophied mesenchymal sclera (ma) surrounding cyst. Cysts may fuse or retain their initial separation.



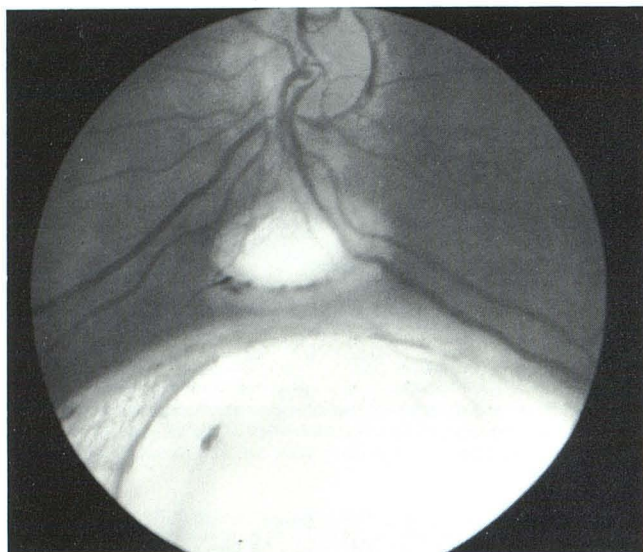


Fig. 6.—Fundal photograph shows ophthalmoscopic appearance of coloboma. There are two white defects below normal optic disk resulting from atrophy of pigmented retina associated with coloboma development. In general, neurosensory retina and sclera in this area are also atrophic.

colobomas can be differentiated on CT from ocular masses by their continuity with the low-density vitreous cavity and surrounding thin dense sclera.

The orbital cysts in our cases presented on CT as very large, low-attenuating masses surrounded by a thin rim of higher attenuation. These cysts usually contain a clear yellow transudate and have cerebrospinal fluid attenuation values. The orbit may be expanded (cases 2 and 3). The eyes are usually microphthalmic and displaced. The cyst may be unilateral or bilateral. CT is helpful in demonstrating the extent of the cysts and differentiating them from other intraorbital masses. It is also useful in evaluating the effect of cyst decompressions and recurrences.

In the CT evaluation of colobomas, attention should also be given to the proximal optic nerve and intracranial structures. Colobomas may be associated with optic nerve atrophy and have been reported in association with transsphenoidal encephaloceles, olfactory dysplasia, and agenesis of the corpus callosum [7]. The characteristic posterior global and optic nerve contour abnormalities and microphthalmus with large orbital cysts recognizable by CT are diagnostic. These findings allow differentiation from other intraorbital masses. Because an entire spectrum of coloboma manifestations has been described in the pathologic and ophthal-

mologic literature, additional CT variations will certainly be discovered in the future.

#### REFERENCES

1. Gordon DM. *Ophthalmoscopy*. Kalamazoo: Upjohn, 1971:51-52
2. Duke-Elder S. *System of ophthalmology*, vol 3, part 2. St. Louis: Mosby, 1963:456-487
3. Pagan RA. Ocular coloboma. *Surv Ophthalmol* 1981;25:223-236
4. Mann I. *Developmental abnormalities of the eye*. Philadelphia: Lippincott, 1957:68-94
5. Moore K. *The developing human*. Philadelphia: Saunders, 1973:336
6. Meyer E, Zonis S, Gdal-On M. Micro-ophthalmus with orbital cysts: a clinical pathologic report. *J Pediatr Ophthalmol Strabismus*, 1977;14:38-41
7. Corbett J, Savino PJ, Schatz NJ, Orr LS. Cavitory developmental defects of the optic disc. *Arch Neurol* 1980;37:210-213

#### Editorial Comment

This article and one by Anderson et al. in the January/February 1983 issue of the *AJNR* (Anderson RL, Epstein GA, Dauer EA. Computed tomographic diagnosis of posterior ocular staphyloma. *AJNR* 1983;4:90-91) are very similar in subject matter, and the following comment is offered to help distinguish staphylomas from colobomas:

Colobomas are congenital ocular abnormalities wherein a part of the structure of the eye is lacking, usually because of deficient closure of the globe during embryonic development. They typically appear inferonasally and may involve the optic nerve, retina, choroid, iris, and/or the lens. Staphylomas, on the other hand, are usually acquired defects in the wall of the globe that cause protrusion of cornea or sclera. They are lined with dark uveal tissue (either iris or choroid) that is visible through the thinned ocular surface, and, if bands of connective tissue persist over the defect, they may be lobulated, resembling a bunch of grapes. Staphylomas may occur on the posterior surface of the eye in severe myopia, as described by Anderson et al., or on the anterior surface in inflammatory conditions such as rheumatoid arthritis.

Thomas R. Hedges III  
 Department of Ophthalmology  
 New England Medical Center  
 Tufts University  
 Boston, MA 02111