

Are your **MRI contrast agents** cost-effective?

Learn more about generic **Gadolinium-Based Contrast Agents**.



FRESENIUS  
KABI

caring for life

**AJNR**

**Neurotoxicity of nonionic iodinated water-soluble contrast media in myelography: experimental study.**

J M Caillé, M Gioux, P Arné and J Paty

*AJNR Am J Neuroradiol* 1983, 4 (6) 1185-1189

<http://www.ajnr.org/content/4/6/1185>

This information is current as of April 30, 2024.

# Neurotoxicity of Nonionic Iodinated Water-Soluble Contrast Media in Myelography: Experimental Study

Jean-Marie Caillé<sup>1</sup>  
 Maxime Gioux<sup>2</sup>  
 Pierre Arné<sup>2</sup>  
 Jacques Paty<sup>2</sup>

The neurotoxicity of four contrast media—iotrol, iopamidol, metrizamide, and iogluclide—was studied by subarachnoid injection in 14 rabbits implanted with four cerebral electrodes. Thirty-four recordings and quantitative analyses were carried out of spontaneous electrical brain activity, seizure activity, and visual- and somatosensory-evoked potentials. The quantitative study of the electroencephalograms showed differences among the four products. All four of the contrast media induced a general slowing of the electroencephalographic activity and, 30 min after injection, slow waves and a shift of the spectrum energy toward the slow frequencies (0.5–3.5 Hz). The slowing of the recording was the least marked with iotrol and recovery of a normal recording was also quickest with iotrol. The quantitative study of electrical seizures and paroxysms revealed higher seizure activity with iogluclide and iopamidol. The study of the evoked potentials does not permit any distinction among the four contrast agents. Metrizamide induced the fewest seizures, but, considering the slow waves and the seizures, iotrol appears to be the least neurotoxic.

Using an experimental animal method that we have already described [1], we studied the neurotoxicity of four nonionic water-soluble contrast media used in myelography. The neurotoxicity of nonionic contrast products used in subarachnoid injection is not pronounced; however side effects persist that are caused by the penetration of these products into the extracellular and probably the intracellular spaces [2–6]. These complications have been well described with the clinical use of metrizamide [7]; they include electroencephalographic (EEG) alterations characterized by slow waves and seizures. Recently, new nonionic contrast products have been used in man to visualize the subarachnoid spaces. The neurotoxicity of these products is not as well known as that of metrizamide [8–11]. Quantitative studies of spontaneous electrical brain activity and evoked potentials constitute means of studying the neurotoxicity of contrast agents [1, 10, 12]. We report the results of an experimental comparison of the neurotoxicity of four contrast agents—metrizamide, iogluclide, iopamidol, and iotrol—using these methods.

## Materials and Methods

The experimental animal used, the rabbit, was chronically implanted by stereotaxic methods using Sawyer's reference points. This implantation included four electrodes: two cortical (one in the somatomotor cortex and one in the visual cortex) and two implanted more deeply (one in the ventroposterolateral nucleus of the thalamus and one in the lateral geniculate body). A cannula implanted in the anterior cephalic subarachnoid space permitted the injection of the contrast media into the cistern of the olfactory bulb. After craniotomy, the electrodes and the cannula were put into place and solidly fixed to the skull with cement.

Fourteen rabbits were used and 34 recordings were carried out. Four nonionic iodinated water-soluble contrast media were studied: metrizamide, iopamidol, iogluclide, and iotrol.

Received December 1, 1982; accepted after revision June 15, 1983.

Presented at the Symposium Neuroradiologicum, Washington, DC, October 1982.

<sup>1</sup> Service de Neuroradiologie, Hôpital Pellegrin-Tripode, 33076 Bordeaux, France. Address reprint requests to J. M. Caillé.

<sup>2</sup> Service d'Exploration Fonctionnelle du Système Nerveux, Hôpital Pellegrin-Tripode, 33076 Bordeaux, France.

AJNR 4:1185–1189, Nov/Dec 1983  
 0195-6108/83/0406-1185 \$00.00  
 © American Roentgen Ray Society



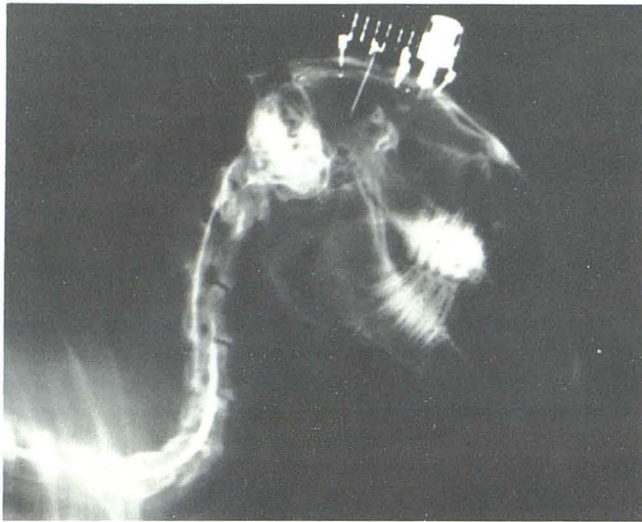


Fig. 1.—Rabbit implanted with cortical and thalamic electrodes. Contrast medium is injected via sealable cannula and mixes with CSF surrounding brain and cervical spinal cord.

For each injection the volume injected was 0.5 ml and the total dose of iodine injected was 150 mg. Immediately after injection into the anterior cephalic cisterns, the head of the rabbit was vigorously shaken to assure mixing of the contrast agent with the cerebrospinal fluid (CSF) (fig. 1).

The injections and the EEG recordings were carried out 8 days after implantation of the electrodes. Recordings were carried out in rest conditions. The electrical activity was measured from the four implanted electrodes. These were monopolar recordings with respect to the ear reference. This activity was amplified and recorded on magnetic tape. The electrocardiogram of the animal and the synchronizing signals, when stimuli were delivered, were recorded at the same time. The data were analyzed later using an intertechnique Plurimat S signal analyzer.

We studied the spontaneous brain activity between the stimulation sequences and the evoked potentials obtained by averaging the EEG after stimuli. When two or more contrast media were used on the same rabbit, the injections and EEG recordings were carried out at 8 day intervals. For each recording we continuously studied the spontaneous EEG for 8 hr, starting 1 hr before injection and continuing for 7 hr after injection. Visual-evoked potentials (VEPs) and somatosensory-evoked potentials (SEPs) were recorded 10 times after each injection of contrast media. Observations consisting of an EEG and a study of evoked responses were carried out systematically at 24 hr. Pathologic control of the brain and meninges of the different rabbits was not carried out after experimentation.

## Results

### Evoked Potentials

Evoked potentials are electrical responses in a central structure after peripheral stimulation. These signals are extracted from the baseline noise by signal averaging after repeated peripheral stimulation. We studied two sensory tracts: a short visual pathway within the brain and a longer somesthetic tract with a medullary and central route. For these two routes, we measured the cortical-evoked potentials and those from the corresponding thalamic relays. Each evoked potential is composed of a series of characteristic

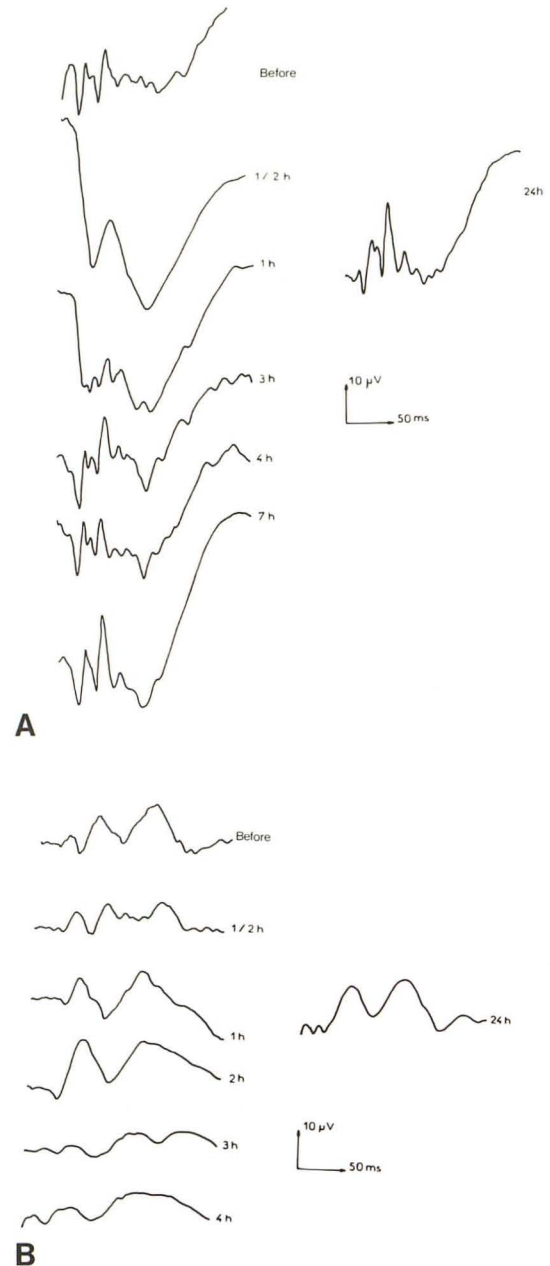


Fig. 2.—VEPs and SEPs before and after injection of contrast material. **A**, VEPs are simplified as early as the first 1/2 hr, and first three spikes are still inapparent at 1 and 3 hr. There is a marked increase in amplitude at 1/2 and 1 hr. **B**, SEPs are simplified at 3 and 4 hr and return to nearly normal aspect at 24 hr. These changes were similar for all four tested contrast agents.

positive or negative spikes. The spikes represent synaptic function in the gray matter. The latencies between spikes are the result of signal conduction in the pathways.

The study of evoked potentials permitted us to show consistently, no matter which product was used, an increase in amplitude of the evoked response and a simplification with almost complete disappearance of the three first spikes that are common in the rabbit's VEPs (fig. 2A). The first spikes reappeared gradually during the first 3 hr after injection, and the amplitude became normal toward 7 hr. The deformations seem more diagrammatic and the recuperation



slower for the evoked potentials recorded in the somato-motor cortex (fig. 2B). In studying the evoked potentials, we found that the deformations were so similar for the four contrast media that we could not distinguish among them.

### Spontaneous Electrical Activity

This may be shown in two ways: by a polygraphic study that analyzes the fundamental frequencies of the rhythms or by a spectral analysis that determines the energies of the different frequency bands.

**Polygraphic study (conventional EEG).** The continuous recording reveals two changes regardless of the contrast agent injected: (1) slowing of the rhythms after injection of the contrast material with the appearance of high-voltage slow waves, during which basal activity disappears, and (2) epileptic seizures, with or without clinical manifestations, that are characterized by spikes beginning in the thalamic regions.

**Spectral analysis.** This is a quantitative study of the different frequencies that constitute the EEG. These are obtained by a fast-Fourier transform of the recorded electrical signals (fig. 3). The energy content in certain characteristic frequency bands: 0.5–3.5 Hz, 1.5–3.5 Hz, etc. was measured for the four contrast media. The percentage of energy of these bands with respect to the total spectrum energy gives the index. We calculated the mean index before and at 30 min, 1 hr, 2 hr, 3 hr, etc. after injection of the contrast material. Using these indices we were able to study the quantitative changes in the frequencies.

Averaged indices for all substances showed general slowing of electrical activity (increase in the 0.5–3.5 Hz band) after injection of control solvent or contrast material. The difference was, however, greater after contrast material and became significant at 0.001. This slowing disappeared rapidly when solvent was injected but continued to develop after contrast injection. The slowing of electrical activity recorded from the four structures was maximal 30 min after injection of the substance shown by an increase of the 0.5–3.5 Hz band and by complementary lowering of the 3.5–6.5 Hz band. Reduction of basal rhythm frequencies (5 Hz) and dramatic increase in low frequencies induced a large displacement of the energy spectrum toward the low-frequency bands (fig. 3).

These slow waves of varying amplitude constantly appeared regardless of the contrast agent used, but their rate of disappearance varied. Metrizamide produced more slow waves and a longer recovery period. Iotrol produced less deviation toward the slow waves of the spectrum, and the reappearance of normal theta waves was the fastest. However, with iotrol a "rebound" phenomenon (appearance of slow waves) occurred after 7 hr as if the releasing of a certain toxicity provoked the reappearance of the slow waves (figs. 4 and 5A).

The action of these four contrast media concerning slow frequencies can be summarized: The four agents produced slow waves. In the first hour after injection, there was no difference in the degree of slowing of the EEG recordings, regardless of the agent used. Significant differences ap-

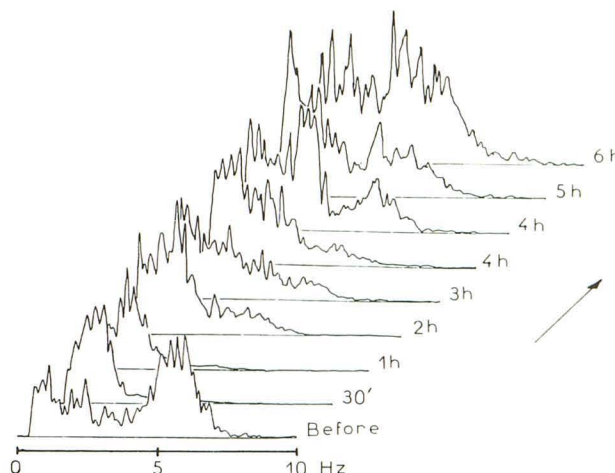


Fig. 3.—Spectral density power. Normal recording before injection is characterized by large-energy spectrum for 5–6 Hz frequency bands. At 30 min and 1 hr after injection of contrast material, there is no more energy for 5–6 Hz frequency bands; all energy is concentrated in low frequencies (0–3.5 Hz) on left. Energy of 5–6 Hz frequency bands reappears on recording only after 4 hr.

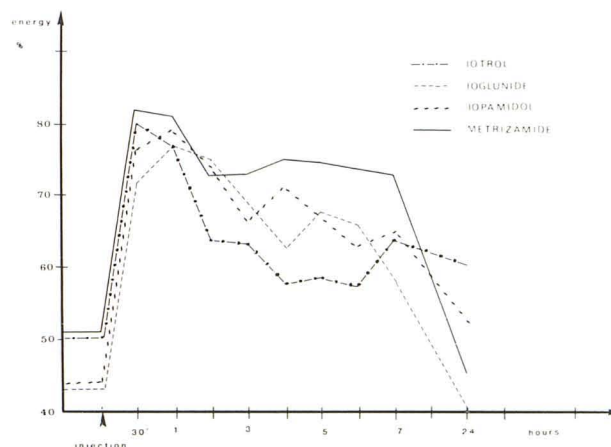
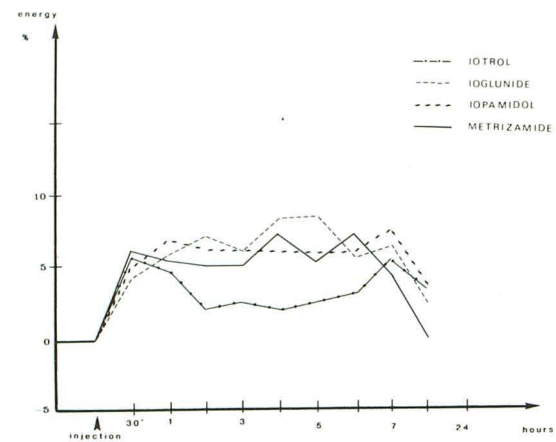


Fig. 4.—Mean index of percentage of energy of 0.5–3.5 Hz compared with total spectrum energy. Before injection, mean index for these frequencies represents 40%–50% of total energy. After injection (30 min–1 hr), mean index represents 70%–80% of total energy. Evolution toward normal spectrum of energy is faster with iotrol, but at 7 hr a rebound phenomenon occurs.

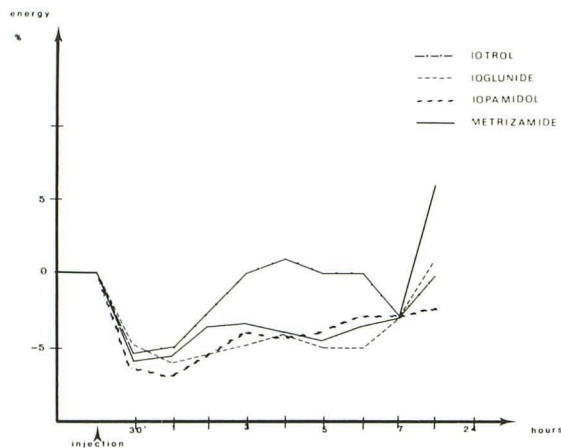
peared between 2 and 6 hr. The disappearance of slow waves was faster with iotrol than with the other three agents. The disappearance of slow waves was slowest with metrizamide. At 7 hr the return to normal of the EEG is not complete. With iotrol, a rebound phenomenon is produced at 7 hr. At 24 hr recuperation is complete for all four media. Study of rapid reduction between 3.5 and 6.5 Hz shows complementary reduction. Here again recuperation is faster with iotrol, and a rebound phenomenon was again found at 7 hr for this product (figs. 5B and 5C).

### Quantitative Study of Electrical Seizures and Paroxysms

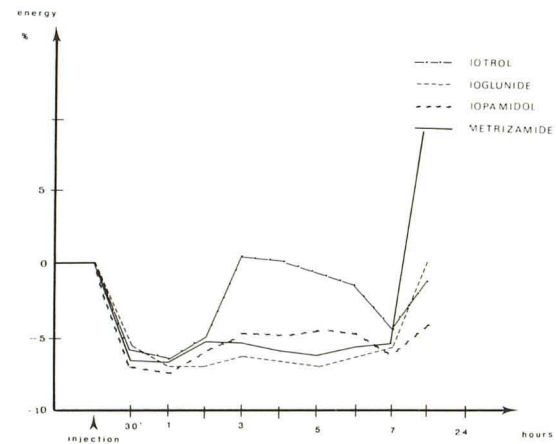
We distinguished between *seizures* and *paroxysms*. Paroxysms are displayed by one or several spikes or spike



A



B



C

Fig. 5.—Changes of percentage of energy. All curves were positioned at same level of energy before injection (0). A, After injection, energy of 1.5–3.5 Hz frequency band increased to about 5%. Evolution toward normal spectrum of energy is faster with iotrol with rebound phenomenon at 7 hr. Changes of percentage of energy of 3.5–6.5 Hz (B) and 5–6.5 Hz (C) frequency bands are opposite those of low-frequency bands, with a 5%–7% energy decrease. With iotrol, spectrum of energy becomes normal at 3 hr, but rebound phenomenon occurs at 7 hr.

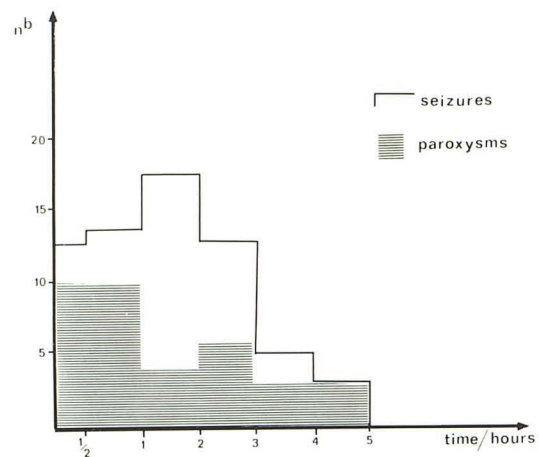


Fig. 6.—Seizures and paroxysms (shaded areas) for the four contrast agents and 34 recordings relative to time. Paroxysms and seizures occur most often in first 3 hr.

TABLE 1: Seizures and Paroxysms after Administration of Contrast Agents in Rabbits

Contrast Agent	No. of Rabbits (Total No. of Seizures/Paroxysms)		
	Totals	Seizures	Paroxysms
Metrizamide	9	2 (2)	2 (2)
Iopamidol	8	7 (31)	6 (10)
Iogluclide	7	2 (29)	4 (15)
Iotrol	10	3 (4)	5 (13)

waves. They differ from seizures, which are characterized by prolonged spike activity and followed by a recurring rhythm of spike waves. Further, seizures are generally followed by slow waves.

The seizures that we obtained were electrical seizures without clinical manifestations with one exception. Very often seizures were induced by luminous or somatosensory stimulation and originated at a subcortical level, diffusing secondarily to a cortical level. Seizures occurred most often in the first 3–4 hr (fig. 6). Seizure and paroxysm responses after administration of the various contrast agents are summarized in table 1. One of these animals was remarkably susceptible to three of the contrast agents. Iotrol produced two seizures and five paroxysms; iogluclide, 28 seizures and two paroxysms; and iopamidol, 16 seizures and one paroxysm. By contrast, metrizamide injected after iotrol and before iogluclide produced no electrical seizure.

Discussion

The neurotoxicity of contrast media used to visualize the subarachnoid spaces in man is directly related to the ability of these products to penetrate the extracellular and intracellular compartment of the brain [1, 2, 4, 6, 13, 14]. This neurotoxicity is demonstrated electrically by the modifica-



tion of evoked potentials and by the spontaneous appearance in the EEG recordings of slow waves and seizures. The increase in amplitude and the simplification of evoked potentials demonstrate a hyperexcitability of either the visual or somatomotor cortex.

The concentration of iodine injected (150 mg/0.5 ml) corresponds closely to concentrations and doses used clinically in man. Changes in the CSF pressure after intrathecal injection of 0.5 ml of contrast material are not responsible for the EEG changes [15]. Kinetic activity is much faster in rabbits than in man. In rabbits, most electrical seizures occur during the first 3 hr after injection, while in man they occur at 6–9 hr. This phenomenon surely reflects the differences of cerebral volume and thus the different rate of diffusion. It is possible that the injections may induce inflammatory reactions that might change the distribution of the contrast material in the cisterns [16, 17], but the injection sequences were different for each rabbit, and we believe that the number of rabbits (14) is sufficient to control this variable.

The simplified evoked potentials indicate a lowering of the signal:noise ratio; this may be due to increased basic noise after weakening of cortical synchronizing signals or decreased signal strength. The subcortical action of the contrast agent triggers epileptic seizures at the thalamic level and interrupts thalamocortical conduction. This action, which is essentially on the gray matter, agrees with reflexologic and intracellular studies and induces low-frequency activity.

We have shown different actions according to the substance used, both in frequency analysis of spontaneous activity and in changes with time. In this way, it is possible to build up activity profiles of the different substances and to compare them. Metrizamide produces little epileptic activity, but generates a significant slowing of the electrical activity, which disappears very slowly. Iopamidol also produces slow frequencies and many paroxysms, which most often produce electrical seizures. The kinetics of this product seem to be very rapid because all the electrical seizures are found during the first 3 hr. The kinetics of iogluclide seem to be different. The electrical seizures are as numerous as with iopamidol but are spread out until 7 hr. Iotrol quantitatively produces the fewest modifications in the EEG recording. The slowing is not as pronounced and disappears more rapidly than with the three other agents. The paroxysms are less prominent than with iogluclide and iopamidol. However, with iotrol, a rebound phenomenon occurs at around 7 hr when the slow waves reappear as well as, perhaps, paroxysms. When iotrol is used clinically in man it would be desirable to observe the patients during a long period (9–12 hr) because of the different kinetics involved. Overall, iotrol seems to be the least toxic to the rabbit. There are fewer electrical seizures and the slow waves disappear more rapidly than with the other contrast agents.

## REFERENCES

1. Gioux M, Arné P, Paty J, Caillé JM. Experimental model of neurotoxicity study of water-soluble contrast media. In: Amiel M, ed. *Contrast media in radiology*. Berlin: Springer-Verlag, 1982:134–140
2. Caillé JM, Guiber-Iranier F, Howa JM. Contamination encéphalique par le métrizamide après myélographie. *J Neuroradiol* 1980;7:3–12
3. Drayer BP, Rosenbaum AE. Metrizamide brain penetrance. *Acta Radiol [Suppl]* (Stockh) 1977;355:280–293
4. Bertoni JM, Steinman CG. Competitive inhibition of brain hexokinase by metrizamide. *Neurology* (NY) 1982;32:320–323
5. Fentstermacher JD, Bradbury MWB, Du Boulay G. The distribution of  $^{125}\text{I}$ -metrizamide and  $^{125}\text{I}$ -diatrizoate between blood, brain and cerebrospinal fluid in the rabbit. *Neuroradiology* 1980;19:171–180
6. Hammer B. The pathophysiology of intrathecally-injected contrast media. In: Felix R, Kazner E, Wegener OH, eds. *Contrast media in computed tomography*. Amsterdam: Excerpta Medica, 1981:52–57
7. Schmidt RC. Mental disorders after myelography with metrizamide and other water-soluble contrast media. *Neuroradiology* 1980;19:153–157
8. Cahn J, Borzeix MG, Cahn R, et al. Comparative experimental study of contrast media in neuroradiology. In: Amiel M, ed. *Contrast media in radiology*. Berlin: Springer-Verlag, 1982:154–158
9. Gonsette RE. The neurotoxicity of water-soluble contrast media: actual concepts and future. In: Amiel M, ed. *Contrast media in radiology*. Berlin: Springer-Verlag, 1982:115–122
10. Gonsette RE. Immediate and delayed neurotoxicity of newly synthesized contrast media demonstrated by EEG sequential analysis. In: Amiel M, ed. *Contrast media in radiology*. Berlin: Springer-Verlag, 1982:141–148
11. Sovak A, Ranganathan R, Kerber C. A nonionic, isotonic dimer iotrol: a new contrast medium for the intrathecal space. A review of pharmacological evaluation. In: Amiel M, ed. *Contrast media in radiology*. Berlin: Springer-Verlag, 1982:123–128
12. Daly DD. Genesis of abnormal activity. In: *Handbook of electroencephalography and clinical neurophysiology*, vol. 14. Amsterdam: Elsevier, 1975:5
13. Northington JW, Biery DN, Glickman LT. Intrathecal dextrose to prevent seizures after metrizamide myelography in dogs. *Invest Radiol* 1982;17:282–283
14. Hershkowitz N, Bryan N. Neurotoxic effects of water-soluble contrast agents on rat hippocampus extracellular recordings. *Invest Radiol* 1982;17:271–275
15. Carlborg B, Maly P, Golman K, Almen T, Lindqvist C. Changes in the cerebrospinal fluid pressure after intrathecal injection of contrast media in rabbits. In: Amiel M, ed. *Contrast media in radiology*. Berlin: Springer-Verlag, 1982:159–163
16. Haughton VM, Eldevik OP, Sasse EA, Lipman BT. Excretion of aqueous contrast media from the subarachnoid space of primates. In: Amiel M, ed. *Contrast media in radiology*. Berlin: Springer-Verlag, 1982:129–133
17. Haughton VM. The effect of myelographic contrast media on the arachnoid. In: Amiel M, ed. *Contrast media in radiology*. Berlin: Springer-Verlag, 1982:149–153