

Are your **MRI contrast agents** cost-effective?

Learn more about generic **Gadolinium-Based Contrast Agents**.



**FRESENIUS
KABI**

caring for life

AJNR

Recovery from Cranial Nerve Symptoms after Flow Diversion without Coiling for Unruptured Very Large and Giant ICA Aneurysms

J.K. Lee, J.H. Choi, B.-S. Kim and Y.S. Shin

This information is current as
of May 2, 2024.

AJNR Am J Neuroradiol 2022, 43 (5) 736-740

doi: <https://doi.org/10.3174/ajnr.A7498>

<http://www.ajnr.org/content/43/5/736>

Recovery from Cranial Nerve Symptoms after Flow Diversion without Coiling for Unruptured Very Large and Giant ICA Aneurysms

J.K. Lee, J.H. Choi, B.-S. Kim, and Y.S. Shin



ABSTRACT

BACKGROUND AND PURPOSE: Cranial nerve symptoms, including visual impairment and ophthalmoplegia, are one of the most common presentations of very large and giant (≥ 15 mm) ICA aneurysms. In this study, we evaluated the treatment outcomes of flow diversion and conventional coiling in terms of recovery from cranial nerve symptoms and postoperative complications.

MATERIALS AND METHODS: Seventy-nine patients with unruptured ICA aneurysms of > 15 mm who were treated with flow diversion or conventional coiling between December 2009 and December 2020 were retrospectively evaluated. We compared the radiologic and clinical outcomes, including recovery from cranial nerve symptoms, between the 2 groups.

RESULTS: Twenty-eight of 49 patients (57.1%) treated with flow diversion and 10 of 30 patients (33.3%) treated with conventional coiling initially presented with cranial nerve symptoms ($P = .068$). In the clinical follow-up, the symptom recovery rate was significantly higher in those treated with flow diversion (15 [50%] versus 3 [25%] with conventional coiling, $P = .046$). Multivariate logistic regression analysis demonstrated that flow diversion was significantly associated with symptom recovery (OR, 7.425; 95% CI, 1.091–50.546; $P = .040$). The overall postoperative complication rate was similar (flow diversion, 10 [20.4%]; conventional coiling, 6 [20.0%], $P = .965$), though fatal hemorrhagic complications occurred only in patients with intradurally located aneurysms treated with flow diversion (4 [8.2%] versus 0 [0.0%] with coiling, $P = .108$).

CONCLUSIONS: Flow diversion without coiling for very large and giant ICA aneurysms yielded a higher rate of recovery from cranial nerve symptoms, but it may be related to an increased hemorrhagic complication rate, especially for intradurally located aneurysms.

ABBREVIATION: OKM = O'Kelly-Marotta

Flow diversion has shifted the paradigm of endovascular aneurysm treatment in recent years. The mechanism of flow diversion involves device endothelialization and endoluminal reconstruction of the parent artery with simultaneous intraneurysmal thrombosis.¹ The safety and efficacy of flow diversion have been extensively reviewed in the past decade.²⁻⁴ Consequently, flow diversion has emerged as a favorable treatment for large (10–25 mm) and giant (> 25 mm) intracranial aneurysms, with several studies reporting a higher rate of aneurysm occlusion and a lower rate of recurrence compared with the

respective rates with conventional endovascular treatment.⁵⁻⁸ However, more recent studies found a lower long-term aneurysm complete occlusion rate after flow diversion, ranging from 72% to 78%.^{9,10} Moreover, a meta-analysis performed by Brinjikji et al¹¹ found that the morbidity and mortality in patients treated with flow diversion were 5% and 4%, respectively.

Giant intracranial aneurysms account for 2%–5% of all intracranial aneurysms, and they are associated with a higher risk of rupture compared with the smaller aneurysms.^{12,13} In addition to the risk of rupture, large and giant aneurysms in some locations can cause cranial nerve symptoms. For example, cranial nerves II, III, V, and VI may be compressed from large aneurysms of the ICA, leading to third nerve palsy, visual loss, diplopia, and facial numbness.^{14,15} Packing of coils in the aneurysm may create mass effect, whereas flow diversion may promote shrinkage of the aneurysm.^{14,16,17} In this study, we compared the clinical outcomes of patients treated with flow diversion without coiling and conventional coiling, specifically evaluating its efficacy on cranial nerve symptoms.

Received January 12, 2022; accepted after revision March 8.

From the Departments of Neurosurgery (J.K.L., J.H.C., Y.S.S.) and Radiology (B.-S.K.), Seoul St. Mary's Hospital, The Catholic University of Korea College of Medicine, Seoul, South Korea.

Please address correspondence to Jai Ho Choi, MD, PhD, Department of Neurosurgery, Seoul St. Mary's Hospital, The Catholic University of Korea, Seoul (06591), South Korea; e-mail: bivalvia98@gmail.com

Indicates article with online supplemental data.

<http://dx.doi.org/10.3174/ajnr.A7498>

MATERIALS AND METHODS

Study Design and Population

A total of 3522 patients with unruptured intracranial aneurysms treated with the endovascular method at a single institution between December 2009 and December 2020 were retrospectively evaluated. Among them, 127 aneurysms of ≥ 15 mm were included. We excluded patients with previously ruptured or treated aneurysms, fusiform aneurysms, and aneurysms that did not arise from the ICA. Fifteen millimeters was selected because of the national insurance policy, which prohibits the use of flow diversion for aneurysms of < 15 mm. Additionally, the insurance policy prohibits interventionists from using coils in conjunction with flow diversion, limiting the treatment of these large and giant aneurysms. Consequently, we were able to specifically evaluate the effectiveness of flow diversion without coiling. We reached an ethical decision for each patient by selecting the treatment technique according to a multidisciplinary overview from our department. Patients treated with flow diversion without coiling were assigned to the flow-diversion group, while those treated with conventional coiling were assigned to the coiling group. This study was approved by the institutional review board at our institution.

Periprocedural Angiographic Evaluation and Endovascular Procedure

All patients underwent preprocedural diagnostic DSA of the intracranial vessels for a comprehensive evaluation of the aneurysm. Aneurysm features, including the size, shape, location, and thrombosis inside the aneurysm, were examined. Additionally, the size and morphology of the parent artery, as well as its relationship with the aneurysm, were assessed. Postoperative follow-up for each patient was performed 6–12 months after treatment with MRA and DSA for patients treated with conventional coiling and those treated with flow diversion, respectively. Clinical symptoms and complications were assessed at the time of follow-up imaging. The angiographic results of flow diversion were evaluated using the O’Kelly-Marotta (OKM) filling grade system. Radiologic and clinical evaluations were conducted with the consensus of 2 observers (J.K.L. and J.H.C.), who were blinded to the information on perioperative ischemic complications.

Statistical Analysis

Statistical analysis was performed using SPSS, Version 24 (IBM). We performed a χ^2 test or Fisher exact test for categorical variables and an independent *t* test for continuous variables, and $P < .05$ was considered statistically significant. Multivariate analysis was performed using a logistic regression model for variables that were significant in the univariate analysis ($P < .10$).

RESULTS

Patient Baseline Characteristics

Among the 79 patients with intracranial aneurysms, 49 patients (62.0%) were treated with flow diversion and 30 patients (38.0%) were treated with conventional coiling. Coiling procedures were performed using different endovascular techniques: 18 (60.0%) stent-assisted, 2 (6.7%) balloon-assisted, 6 (20.0%) single-catheter, and 4 (13.3%) multiple-catheter coiling. The baseline characteristics of the 2 groups are summarized in the Online

Supplemental Data. The mean patient age did not differ between the flow-diversion group (57.82 [SD, 11.96] years) and the coiling group (60.67 [SD, 13.05] years). The proportion of female patients was higher than that of males in both groups (flow diversion group, 47 of 49 patients [95.9%]; coiling group, 26 of 30 patients [86.7%]). Risk factors, including smoking, diabetes mellitus, hypertension, and hyperlipidemia, were similar between the 2 groups. Although the comparison was not statistically significant, flow diversion was used more frequently to treat patients with aneurysm-induced cranial nerve symptoms ($n = 28$, 57.1%) than coiling ($n = 10$, 33.3%). The most common cranial nerve symptoms were related to the eye and vision, except for 1 patient who initially presented with ipsilateral facial pain.

The mean maximal size of aneurysms among patients in the flow-diversion group was significantly larger than that among patients in the coiling group (22.04 [SD, 5.36] mm versus 18.27 [SD, 4.12] mm, $P = .001$). The proportion of aneurysms with diameters of > 25 mm was higher in the flow-diversion group (12 patients, 24.5%) than in the coiling group (1 patient, 3.3%). Most aneurysms treated with coiling ranged from 15 to 20 mm ($n = 23$, 76.7%). On inspection of the aneurysm location, there was no significant difference between the 2 groups; however, more extracranial aneurysms were treated with flow diversion ($n = 23$, 46.9% versus $n = 8$, 26.7%). Among the aneurysms originating from the intradural segment of the ICA, 25 (51.0%) in the flow-diversion group and 12 (40%) in the coiling group were located within the ophthalmic segment.

Clinical and Radiologic Outcomes

The results of both treatment modalities are shown in Table 1. Because flow diversion promotes delayed occlusion of the aneurysm, initial aneurysm occlusion after treatment was evaluated only in patients who underwent coiling. Immediate complete occlusion was achieved in 13 of the 30 patients (43.5%) in the coiling group, and a remnant neck or sac was observed in 8 (26.7%) and 9 patients (30.0%), respectively.

A follow-up examination was not available for 4 patients in the flow-diversion group and 2 in the coiling group. Among the 45 patients who were followed up 1 year after undergoing treatment with flow diversion, 28 (62.2%) reached complete or near-complete occlusion assigned as grade D based on the OKM grading scale, 12 (26.7%) had a neck remnant (OKM C), and 5 (11.1%) had sac filling (OKM A and B).¹⁸ Aneurysm occlusion status did not change much for patients who underwent conventional coiling, with complete or near-complete occlusion seen in 13 patients (46.4%); a neck remnant, in 7 (25.0%); and sac filling, in 8 (28.6%). Furthermore, recurrence of once-occluded aneurysms during the subsequent follow-up was found in 12 patients (40.0%) in the coiling group but not in any in the flow-diversion group ($P < .001$). The retreatment rates for recurrent or remnant aneurysms were similar for both the flow-diversion and coiling groups (6 [12.2%] versus 7 [23.3%]).

Clinically, more patients showed improvement in initial cranial nerve symptoms after undergoing treatment with flow diversion than with coiling (15 [60.0%] versus 3 [25.0%], $P = .046$). Multivariate logistic regression analysis (Table 2) indicated that treatment with flow diversion without coiling was significantly

Table 1: Comparison of clinical and radiologic outcomes between patients treated with flow diversion and those treated with conventional coiling^a

Characteristics	Flow Diversion (n = 49)	Conventional Coiling (n = 30)	P Value
Radiologic outcomes			
Initial occlusion grade			
Not available	49 (100%)		<.001
Complete		13 (43.5%)	
Remnant neck		8 (26.7%)	
Sac filling		9 (30%)	
One-year follow-up occlusion grade (flow-diversion coiling)			.154
OKM D/complete or near-complete	28 (62.2%)	13 (46.4%)	
OKM C/remnant neck	12 (26.7%)	7 (25%)	
OKM A and B/sac filling	5 (11.1%)	8 (28.6%)	
Recurrence during follow-up	0 (0%)	12 (40%)	<.001
Retreatment	6 (12.2%)	7 (23.3%)	.197
Mean follow-up period (mo)	30.3 (SD, 18.7)	40.8 (SD, 25.6)	.111
Clinical outcomes			
Cranial nerve symptom change			.046
Improved	15 (60%)	3 (25%)	
Worsened or sustained	10 (40%)	9 (75%)	
mRS ≥ 2 at discharge	2 (4.1%)	0 (0%)	.262
mRS ≥ 2 at last follow-up	5 (10.2%)	0 (0%)	.071
Mean follow-up period (mo)	33.0 (SD, 21.1)	45.9 (SD, 35.8)	.073

^aData are mean or No. (%).

associated with recovery from cranial nerve symptoms (OR, 7.425; 95% CI, 1.091–50.546; $P = .040$). A representative case of improved visual field after treatment with flow diversion is shown in the [Figure](#).

Treatment-Related Complications

Complications occurring after the procedure were compared between the groups, as summarized in [Table 3](#). The total complication rate was similar for both groups; however, patients in the coiling group had a higher ischemic complication rate (4 [13.3%] versus 3 [6.1%], $P = .274$). Although not statistically significant, the hemorrhagic complication rate was higher in the flow-diversion group (4 [8.2%] versus 0 [0.0%], $P = .108$). Postoperative MR imaging within 24 hours after surgery for these 4 patients did not show evidence of intracranial hemorrhage, but they were re-admitted to the hospital with decreased consciousness from delayed aneurysmal rupture. Three of them had early delayed rupture between 1 and 4 weeks postoperatively, and 1 had late delayed rupture occurring after 5 months. All 4 of these patients were initially treated for aneurysms in the intradural location and died of intracranial hemorrhage.

DISCUSSION

In this retrospective analysis, we found higher recovery rate of cranial nerve symptoms due to very large-to-giant ICA aneurysms after flow diversion without coiling than after conventional coiling. Aneurysms originating from the ICA may cause compression symptoms of cranial nerves II, III, V, and VI, especially when they are large or giant. Although conventional coiling can achieve complete occlusion of these aneurysms, cranial nerve symptoms may be aggravated by the mass effect. There have been various studies showing better outcomes with flow diversion than with conventional coiling, with a higher occlusion rate but not a higher complication rate.^{4,19,20} In this study, we compared the outcomes of cranial nerve symptoms using flow diversion without coiling and conventional

coiling for very large and giant aneurysms, in addition to other clinical and radiologic parameters. Flow diversion has the advantage of redirecting blood flow and promoting thrombus formation in the aneurysm sac, subsequently reducing the mass effect. In this study, 15 of 28 patients (60.0%) treated with flow diversion showed a significantly higher symptom improvement rate compared with 3 of 10 patients (25.0%) treated with conventional coiling ($P = .046$). Moreover, the multivariate analysis identified flow diversion as the only predictor of recovery from cranial nerve symptoms (OR, 7.425; 95% CI, 1.091–50.546; $P = .040$). The benefit of decreased mass effect coincided with a higher occlusion rate (62.2% versus 46.4%, $P = .154$) and lower recurrence rate (0.0% versus 40%, $P < .001$). Similarly, Wang et al²¹ reported favorable outcomes of mass effect-related symptoms for aneurysms treated with flow diversion; however, flow diversion was combined with adjunctive loose coil embolization. Our study investigated the unequivocal effect of flow diversion without using coils inside the aneurysm, which can induce intra-aneurysmal thrombosis or protect the aneurysm wall from direct blood flow. Treating very large and giant aneurysms by flow diversion without adjunctive coiling may be undesirable, but the current national insurance policy prohibits such treatment options.

Our results suggest that flow diversion can notably reduce the mass effect of very large and giant aneurysms, especially in the absence of coils inside the sac. However, the complications associated with flow diversion should not be overlooked. The overall complication rate for both conventional coiling and flow diversion did not differ in comparative data by Chalouhi et al,²⁰ in agreement with our results (20.4% versus 20.0%, $P = .965$). In a previous meta-analysis, delayed aneurysm rupture from treatment with flow diversion was reported with an occurrence rate of 1.7%–3% among the complications.^{11,22} Furthermore, Cagnazzo et al⁵ found a 7% early rupture of aneurysms treated with flow diversion alone, and no cases of rupture in those treated with adjunctive coils. Although not statistically significant, we identified 4 (8.2%)

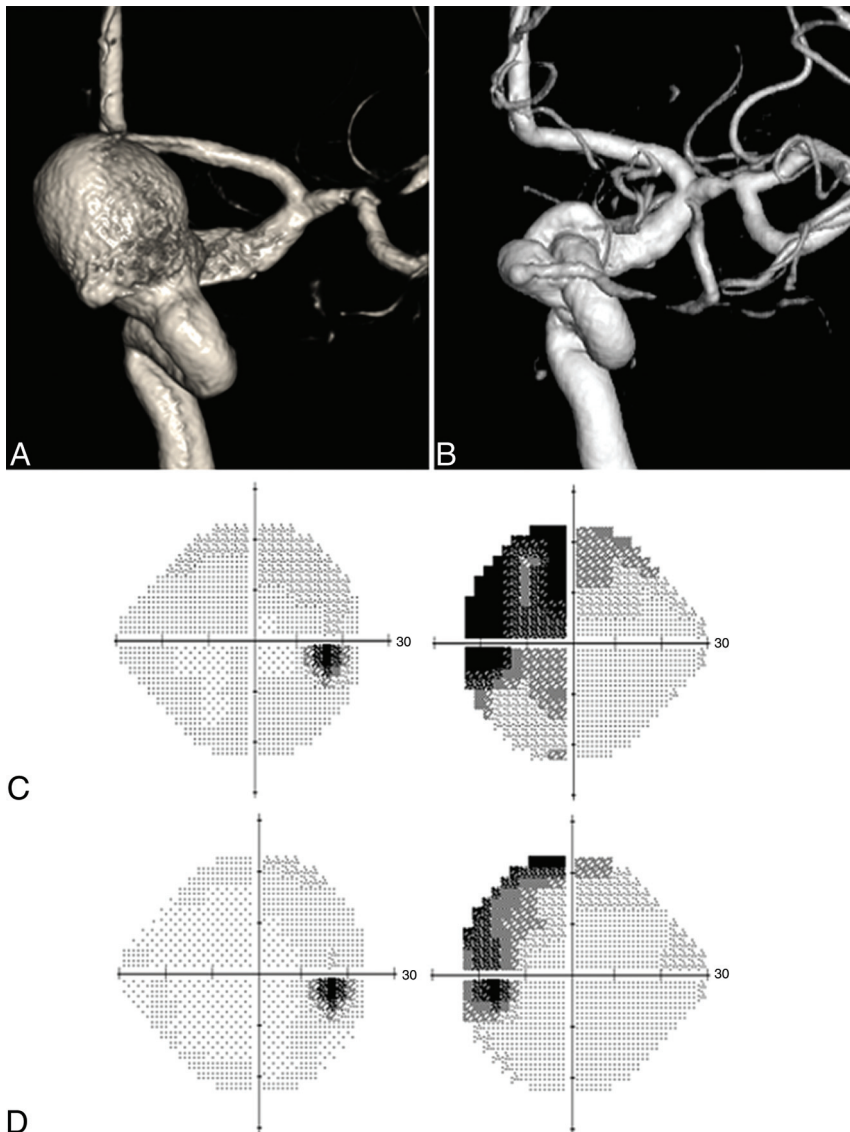


FIGURE. A, Left ICA angiogram showing a large aneurysm with a dome size of 19.0 mm located in the ophthalmic segment of the ICA. B, Follow-up angiogram at 1 year shows near-complete occlusion of the aneurysm. C, Visual field examination before treatment shows a visual field defect of the left eye. D, Follow-up examination at 1 year shows an improved visual field of the left eye. Additionally, the patient's visual acuity improved from 0.3 to 0.8.

fatal hemorrhagic complications from delayed aneurysm rupture after flow diversion and none after conventional coiling ($P = .108$), all of which were in aneurysms originating from the intradural location of the ICA. The hemorrhagic complication rate raises concerns about the safety of flow-diversion treatment in very large and giant intradural ICA aneurysms, especially when adjunctive coils are not used. Besides the 2 methods of treatment in our study, ICA occlusion after angiographic test occlusion may be an alternative treatment option with a low complication rate with favorable outcome because Bechan et al²³ reported 90% improvement rate of cranial nerve symptoms.²⁴

Our study has some limitations owing to its retrospective design and small sample size. Not all patients were evaluated by an ophthalmologist unless the patient experienced visual symptoms or the aneurysm was clearly in the direction of the cranial nerve. Thus, the occurrence of cranial nerve symptoms may be underestimated due to the lack of standard ophthalmic examinations. Furthermore, the symptom duration for each patient was not recorded appropriately. The recovery from symptoms may vary according to the duration of the nerve compression. Further prospective comparative studies are required to validate our findings.

CONCLUSIONS

Our findings suggest that cranial nerve symptoms caused by aneurysm compression may be adequately reduced

Table 2: Univariate and multivariate analyses of the predictors associated with improvement of cranial nerve symptoms^a

Variables	Univariate			Multivariate		
	Recovery from Cranial Nerve Symptoms		P Value	OR	95% CI	P Value
	Yes (n = 17)	No (n = 21)				
Age 60 years or older	6 (35.3%)	12 (57.1%)	.185			
Hypertension	8 (47.1%)	6 (28.6%)	.253			
Intradural location	8 (47.1%)	14 (66.7%)	.062	0.175	0.028–1.092	.092
Size ≥25 mm	5 (29.4%)	5 (23.8%)	.523			
Mean size (mm)	22.9 (SD, 4.5)	23.0 (SD, 6.6)				
Complete/near-complete occlusion	10 (58.8%)	8 (38.1%)	.630			
Technique			.093	7.425	1.091–50.546	.040
Flow diversion	15 (88.2%)	13 (61.9%)				
Conventional coiling	2 (11.8%)	8 (38.1%)				

^aData are mean or No. (%).

Table 3: Treatment-related complications^a

Characteristics	Flow Diversion (n = 49)	Conventional Coiling (n = 30)	P Value
Total complications	10 (20.4%)	6 (20%)	.965
Ischemic complications	3 (6.1%)	4 (13.3%)	.274
Symptomatic infarction	3 (6.1%)	2 (6.66%)	
TIA or asymptomatic infarction	0 (0%)	2 (6.66%)	
Size ≥ 20 mm	2/27 (7.4%)	0/7 (0%)	.458
Intradural location	2/26 (7.7%)	3/22 (13.6%)	.502
Hemorrhagic complications	4 (8.2%)	0 (0%)	.108
Early delayed aneurysmal rupture	3 (6.1%)	0 (0%)	
Late delayed aneurysmal rupture	1 (2%)	0 (0%)	
Size ≥ 20 mm	2/27 (7.4%)	0/7 (0%)	.458
Intradural location	4/26 (15.4%)	0/22 (0%)	.055
Mortality	4 (8.2%)	0 (0%)	.108
Size ≥ 20 mm	2/27 (7.4%)	0/7 (0%)	.458
Intradural location	4/26 (15.4%)	0/22 (0%)	.055

^a Data are No. (%).

by flow-diversion treatment. However, flow-diversion treatment without coiling may be associated with an increased rate of fatal hemorrhagic complications for the treatment of large and giant intradurally located ICA aneurysms. Flow diversion without coiling may be more suitable for aneurysms located extradurally that cause cranial nerve symptoms.

Disclosure forms provided by the authors are available with the full text and PDF of this article at www.ajnr.org.

REFERENCES

- Ravindran K, Salem MM, Alturki AY, et al. Endothelialization following flow diversion for intracranial aneurysms: a systematic review. *AJNR Am J Neuroradiol* 2019;40:295–301 [CrossRef Medline](#)
- Becske T, Kallmes DF, Saatci I, et al. Pipeline for uncoilable or failed aneurysms: results from a multicenter clinical trial. *Radiology* 2013;267:858–68 [CrossRef Medline](#)
- Chalouhi N, Starke RM, Yang S, et al. Extending the indications of flow diversion to small, unruptured, saccular aneurysms of the anterior circulation. *Stroke* 2014;45:54–58 [CrossRef Medline](#)
- Lanzino G, Crobbedu E, Cloft HJ, et al. Efficacy and safety of flow diversion for paraclinoid aneurysms: a matched-pair analysis compared with standard endovascular approaches. *AJNR Am J Neuroradiol* 2012;33:2158–61 [CrossRef Medline](#)
- Cagnazzo F, Mantilla D, Rouchaud A, et al. Endovascular treatment of very large and giant intracranial aneurysms: comparison between reconstructive and deconstructive techniques: a meta-analysis. *AJNR Am J Neuroradiol* 2018;39:852–58 [CrossRef Medline](#)
- Saatci I, Yavuz K, Ozer C, et al. Treatment of intracranial aneurysms using the Pipeline flow-diverter embolization device: a single-center experience with long-term follow-up results. *AJNR Am J Neuroradiol* 2012;33:1436–46 [CrossRef Medline](#)
- van Oel LI, van Rooij WJ, Sluzewski M, et al. Reconstructive endovascular treatment of fusiform and dissecting basilar trunk aneurysms with flow diverters, stents, and coils. *AJNR Am J Neuroradiol* 2013;34:589–95 [CrossRef Medline](#)
- Strauss I, Maimon S. Silk flow diverter in the treatment of complex intracranial aneurysms: a single-center experience with 60 patients. *Acta Neurochir (Wien)* 2016;158:247–54 [CrossRef Medline](#)
- Peschillo S, Caporlingua A, Resta MC, et al. Endovascular treatment of large and giant carotid aneurysms with flow-diverter stents alone or in combination with coils: a multicenter experience and long-term follow-up. *Oper Neurosurg (Hagerstown)* 2017;13:492–502 [CrossRef Medline](#)
- Fujii T, Teranishi K, Yatomi K, et al. Long-term follow-up results after flow diverter therapy using the Pipeline embolization device for large or giant unruptured internal carotid artery aneurysms: single-center retrospective analysis in the Japanese population. *Neurol Med Chir (Tokyo)* 2022;62:19–27 [CrossRef Medline](#)
- Brinjikji W, Murad MH, Lanzino G, et al. Endovascular treatment of intracranial aneurysms with flow diverters: a meta-analysis. *Stroke* 2013;44:442–47 [CrossRef Medline](#)
- Wiebers DO, Whisnant JP, Huston J 3rd, et al. Unruptured intracranial aneurysms: natural history, clinical outcome, and risks of surgical and endovascular treatment. *Lancet* 2003;362:103–10 [CrossRef Medline](#)
- Greving JP, Wermer MJ, Brown RD, Jr, et al. Development of the PHASES score for prediction of risk of rupture of intracranial aneurysms: a pooled analysis of six prospective cohort studies. *Lancet Neurol* 2014;13:59–66 [CrossRef Medline](#)
- Silva MA, See AP, Dasenbrock HH, et al. Vision outcomes in patients with paraclinoid aneurysms treated with clipping, coiling, or flow diversion: a systematic review and meta-analysis. *Neurosurg Focus* 2017;42:E15 [CrossRef Medline](#)
- Durner G, Piano M, Lenga P, et al. Giant Intracranial Aneurysm Study Group. Cranial nerve deficits in giant cavernous carotid aneurysms and their relation to aneurysm morphology and location. *Acta Neurochir (Wien)* 2018;160:1653–60 [CrossRef Medline](#)
- Carneiro A, Rane N, Küker W, et al. Volume changes of extremely large and giant intracranial aneurysms after treatment with flow diverter stents. *Neuroradiology* 2014;56:51–58 [CrossRef Medline](#)
- Miyachi S, Hiramatsu R, Ohnishi H, et al. Usefulness of the Pipeline embolic device for large and giant carotid cavernous aneurysms. *Neurointervention* 2017;12:83–90 [CrossRef Medline](#)
- O'Kelly CJ, Krings T, Fiorella D, et al. A novel grading scale for the angiographic assessment of intracranial aneurysms treated using flow diverting stents. *Interv Neuroradiol* 2010;16:133–37 [CrossRef Medline](#)
- Zanaty M, Chalouhi N, Starke RM, et al. Flow diversion versus conventional treatment for carotid cavernous aneurysms. *Stroke* 2014;45:2656–61 [CrossRef Medline](#)
- Chalouhi N, Tjoumakaris S, Starke RM, et al. Comparison of flow diversion and coiling in large unruptured intracranial saccular aneurysms. *Stroke* 2013;44:2150–54 [CrossRef Medline](#)
- Wang Z, Tian Z, Li W, et al. Variation of mass effect after using a flow diverter with adjunctive coil embolization for symptomatic unruptured large and giant intracranial aneurysms. *Front Neurol* 2019;10:1191 [CrossRef Medline](#)
- Arrese I, Sarabia R, Pintado R, et al. Flow-diverter devices for intracranial aneurysms: systematic review and meta-analysis. *Neurosurgery* 2013;73:193–99; discussion 99–200 [CrossRef Medline](#)
- Bechan RS, Majoie CB, Sprengers ME, et al. Therapeutic internal carotid artery occlusion for large and giant aneurysms: a single center cohort of 146 patients. *AJNR Am J Neuroradiol* 2016;37:125–29 [CrossRef Medline](#)
- Choi JH, Lee KS, Kim BS, et al. Treatment outcomes of large and giant intracranial aneurysms according to various treatment modalities. *Acta Neurochir (Wien)* 2020;162:2745–52 [CrossRef Medline](#)