

Generic Contrast Agents

Our portfolio is growing to serve you better. Now you have a *choice*.



FRESENIUS
KABI

[VIEW CATALOG](#)

AJNR

Intradural disk herniation with CT appearance of gas collection.

M C Kaiser, G Sandt, A Roilgen, P Capesius, D Poos and F Ohanna

AJNR Am J Neuroradiol 1985, 6 (1) 117-118

<http://www.ajnr.org/content/6/1/117.citation>

This information is current as
of May 12, 2025.

Intradural Disk Herniation with CT Appearance of Gas Collection

M. C. Kaiser,¹ G. Sandt,² A. Roilgen,² P. Capesius,¹ D. Poos,¹ and F. Ohanna²

Intradural disk rupture has been reported [1–5]. In most cases disk herniation in the lumbar region occurs on one side or the other of the strong posterior longitudinal ligament; seldom is the central part of the ligament perforated. Very rarely, a disk fragment ruptures through the anterior aspect of the spinal dura to project intrathecally [1].

Continued negative pressure is not necessary to retain gas within a disk [6]. Consequently, gas formed in the nucleus pulposus may persist even if the latter herniates into the spinal canal. Intradural rupture of a disk fragment with the computed tomographic (CT) appearance of an intraspinal gas collection has not been reported. In the case we report, reparative neuromalike tissue reactions had developed around a nerve root to which the disk fragment appeared to be firmly attached [7]. CT provided very important information

about the precise site of the lesion, and the gas bubble gave a good indication of its etiology.

Case Report

A 44-year-old man had a 2 year history of fluctuating lower back pain. Four weeks before admission he experienced acute exacerbation of radicular pain in association with right-sided paresthesia. He was referred for a CT examination of the lumbar spine. Standard radiographs had shown a disk space narrowing at the L5–S1 level with a vacuum phenomenon. CT demonstrated a large intradural air bubble at the L5–S1 level (fig. 1A). Density measurements within the gas collection varied from –600 to –900 H. Metrizamide myelography revealed a lateral filling defect at the L5–S1 interspace on the right side, with cauda equina compression (fig. 1B). Contrast-enhanced CT showed the same air bubble, unchanged in size, site, configura-

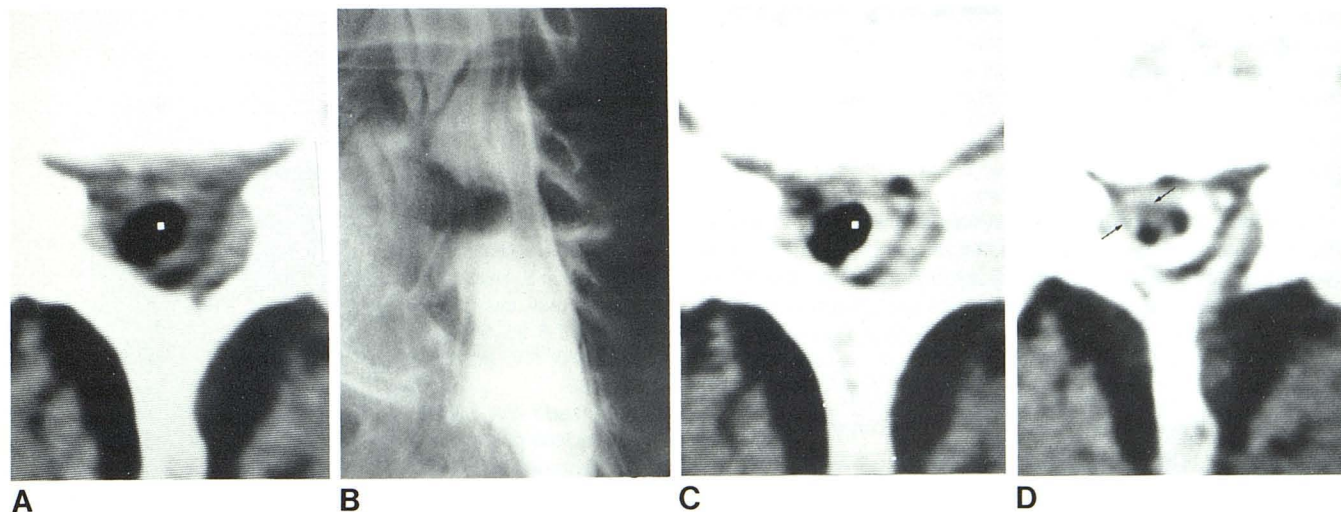


Fig. 1.—A, Unenhanced axial CT scan at L5–S1 interspace. Large intradural gas collection (–800 H). No extradural compression of thecal sac. B, Oblique view, lumbar metrizamide myelogram. Large filling defect clearly outlined on right side. Nerve roots appear compressed locally and deviate to left side. C, Axial CT metrizamide myelogram at level similar to A. Gas collection partly

surrounded by metrizamide. Unchanged site, size, configuration, and density (–600 to –900 H). D, Slightly lower. Intradural soft-tissue mass with degenerative gas-containing material (arrows). Relatively low attenuation within mass (20–30 H) due to partial-volume averaging.

Received September 26, 1983; accepted after revision January 11, 1984.

¹ Department of Neuroradiology, Centre Hospitalier Luxembourg, 4, rue Barblé, Luxembourg-City, Grand-Duchy of Luxembourg. Address reprint requests to M. C. Kaiser.

² Department of Neurosurgery, Centre Hospitalier Luxembourg, Luxembourg-City, Grand-Duchy of Luxembourg.

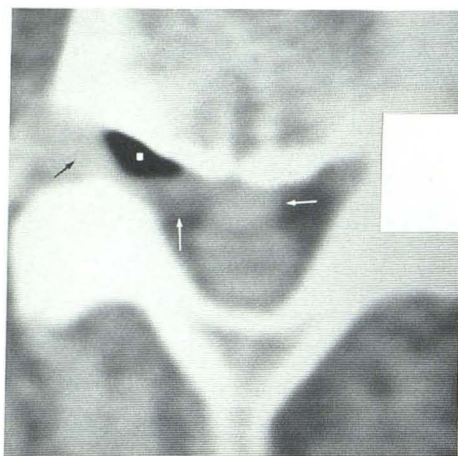

Fig. 2.—Large midline mass behind vertebral body extending to right side, obstructing neural foramen (arrows). Density measurements within mass (65 H) were typical of disk material. Large gas collection within herniated disk material (−943 H). Dura is displaced posteriorly; extradural location of hernia is obvious.

tion, and density, partially surrounded by metrizamide (fig. 1C). The gas collection appeared to be connected to an underlying soft-tissue mass (density 20–30 H) (fig. 1D). This was presumed to be a disk fragment with relatively low attenuation resulting from partial-volume averaging.

Considering the clinical and radiologic findings, a presumptive diagnosis of an intradural disk fragment was established. Surgery was performed. A disk fragment 1–2 cm in diameter had entirely protruded into the dural sac. This fragment was solidly attached to an adjacent nerve root from which it could only be freed with great difficulty. Histologic examination showed severely degenerated cartilage with a neuromalike hypertrophy around a resected nerve root fragment. The postoperative course of the patient was uneventful.

Discussion

Intradural disk rupture was first reported in 1942 by Dandy [2]. Other cases have been reported since [1, 3–5]; CT was performed in one [3]. In most previously published cases the intrathecal disk rupture originated from the L4–L5 intervertebral disk [1]. Clinical history is characterized by chronic low back pain, acute severe radicular pain, and progressive neurologic deficit. In the lumbar region, intradural disk rupture carries a good prognosis [5]. Patients with thoracic or cervical lesions show little or no postoperative improvement [5].

The observation that disk material ruptures through the anterior part of the dura and is displaced intrathecally is very rare, and no satisfactory explanation has yet been offered for

its mechanism. Under normal conditions the ventral dura is loosely attached to the posterior longitudinal ligament [1]. According to one theory, pathologic adhesions subsequent to surgery or inflammation, particularly in the lower lumbar region, may be a causative factor [1]. Some of these are considered sufficiently strong to resist disk herniation without giving way before perforation of the dura.

The typical myelographic feature is a complete block to progression of metrizamide. In our case the myelographic appearance did not suggest an intradural abnormality; on the other hand the CT picture showed a lesion largely located within the dural sac.

Intraspinous gas in herniated disks has been described, but we found no report of migration of a gas-containing disk fragment through the dura. It has been stated that gas formed in the nucleus pulposus may persist even when herniation occurs into the spinal canal [6]. A gas collection within the fissures of the nucleus pulposus is not resorbed and replaced by fluid, as there is no vascular network nearby [8]. In our records we found a case of a patient with a massive lateralized disk protrusion obstructing the neural foramen on the right side and containing a large hypodensity. The gaseous nature of the low-density substance within the hernia was confirmed by density measurement, −960 H, and its extradural location was quite obvious (fig. 2). Continued negative pressure is not necessary to retain gas within the disk. As demonstrated by our case a gas collection may remain in extruded disk fragments, even after migration through the dura.

ACKNOWLEDGMENT

We thank Joséane Hoffmann for help in manuscript preparation.

REFERENCES

1. Blikra G. Intradural herniated lumbar disc. *J Neurosurg* 1969; 31:676–679
2. Dandy WE. Serious complications of ruptured intervertebral disks. *JAMA* 1942;119:474–477
3. Hodge CJ, Binet EF, Kieffer SA. Intradural herniation of lumbar intervertebral discs. *Spine* 1978;3:346–350
4. Peyser E, Harari A. Intradural rupture of intervertebral disk: report of two cases with review of the literature. *Surg Neurol* 1977;8:95–98
5. Smith RV. Intradural disc rupture. *J Neurosurg* 1981;55:117–120
6. Orrison WW, Lilleas FG. CT demonstration of gas in a herniated nucleus pulposus. *J Comput Assist Tomogr* 1982;4:807–808
7. Mathews GJ, Osterholm JL. Painful traumatic neuromas. *Surg Clin North Am* 1972;51:1313–1324
8. Ford LT, Gilula LA, Murphy WA, Mokhtar G. Analysis of gas in vacuum lumbar disc. *AJR* 1977;128:1056–1057