

Are your **MRI contrast agents** cost-effective?

Learn more about generic **Gadolinium-Based Contrast Agents**.



FRESENIUS
KABI

caring for life

AJNR

Comparison of clinical and computed tomographic staging of head and neck tumors.

R A Gatenby, C B Mulhern, Jr, J Strawitz and P J Moldofsky

AJNR Am J Neuroradiol 1985, 6 (3) 399-401

<http://www.ajnr.org/content/6/3/399>

This information is current as
of May 6, 2024.

Comparison of Clinical and Computed Tomographic Staging of Head and Neck Tumors

Robert A. Gatenby¹
 Charles B. Mulhern, Jr.
 Joseph Strawitz
 Philip J. Moldofsky

The extent of tumor was staged independently using conventional clinical methods and high-resolution computed tomography (CT) in 100 patients with tumors at the base of the skull, nasopharynx, oropharynx, hypopharynx, larynx, nose, and paranasal sinuses. Conventional clinical methods used for staging included physical examination, routine biopsy, routine radiography, tomography, and sonography when appropriate. In 10 patients, CT identified tumors that had not been apparent clinically; eight of these were in the nasopharynx and two in the hypopharynx. In another 26 patients, CT showed the tumor to be more locally extensive than had been evident clinically; 12 of these tumors were in the oropharynx. A new technique of CT-guided biopsy of head and neck tumors was used in 20 patients to attain histologic information or to confirm the extent of the tumor. Thus, information obtained by CT scanning or CT-guided biopsy significantly altered treatment planning in 36 of the 100 patients.

Tumors of the head and neck are among the most common malignancies in this country, accounting for about 2% of cancer-related deaths [1]. Several recent reports have stressed the superb definition of normal and abnormal anatomy afforded by high-resolution computed tomographic (CT) scanning [2-4]. Other articles have illustrated the role of CT scanning in staging tumors of the head and neck [5, 6]. We prospectively evaluated 100 patients with tumors of the head and neck to define more clearly the role of CT in the evaluation of such patients.

Subjects and Methods

One hundred patients with tumors of the pharynx, larynx, sinuses, and nasal cavity were staged prospectively with conventional clinical methods. Tumors of the salivary glands, oral cavity, and thyroid were excluded from this evaluation. Conventional clinical evaluation included indirect mirror and direct endoscopic examination, palpation of primary sites (when feasible) and neck nodes, routine biopsy, routine radiography, plain tomography, and laryngography when appropriate.

CT scans of the neck from the base of the skull to the level of the thyroid gland were obtained in each patient. All scans were obtained on a Siemens Somatom 2 scanner (10 sec scanning time). Contiguous 4 mm sections were routinely used with rapid drip infusion of 150 ml of 60% meglumine iohalamate. Scans were always obtained before biopsy or at least 2 weeks after biopsy to prevent confusion in interpretation caused by postbiopsy inflammation and edema.

The scans were reviewed without knowledge of the formal clinical stage obtained by other methods of evaluation. The CT stage was based entirely on the dictated report. To allow uniformity of reporting, the extent of each patient's primary tumor was classified according to the TNM criteria [7]. When there was a significant difference between the clinical stage and the CT stage, confirmation of the true extent of the disease was obtained either through CT-guided biopsy or surgery. Our technique for CT-guided biopsy is reported elsewhere [8].

Received March 21, 1984; accepted after revision June 11, 1984.

¹All authors: Department of Radiology, Fox Chase Cancer Center and Jeanes Hospital, Central Ave. and Shilmire St., Philadelphia, PA 19111. Address reprint requests to R. A. Gatenby.

AJNR 6:399-401, May/June 1985

0195-6108/85/0603-0399

© American Roentgen Ray Society

TABLE 1: TNM Staging of Head and Neck Tumors by Site of Origin

Site (No. of Patients): Stage	No. of Patients in Each Stage				
	NA	T1	T2	T3	T4
Oropharynx (38):					
Clinical	0	10	10	10	8
CT	2	3	9	13	11
Nasopharynx (23):					
Clinical	8	3	5	3	4
CT	0	1	6	8	8
Hypopharynx (14):					
Clinical	2	4	6	2	0
CT	0	2	5	5	2
Larynx (11):					
Clinical	0	5	4	2	0
CT	0	4	3	3	1
Sinus (10):					
Clinical	0	0	2	4	4
CT	0	0	0	4	6
Nasal cavity (4):					
Clinical	0	0	2	0	2
CT	0	0	0	1	3

Note.—NA = tumor not apparent.

Results

Most patients evaluated had pharyngeal lesions. Laryngeal lesions accounted for only 11% of patients evaluated. This is inconsistent with the reported incidences of these tumors [8] and probably reflects referral patterns rather than the true incidence of disease in the Philadelphia region.

Table 1 documents the extent of local disease in each region according to the TNM classification. It is apparent from these data that CT consistently revealed significantly more extensive local disease than was apparent clinically. In summary, information from CT resulted in an increase in the local stage of tumor in 26% of patients and detected 10 lesions not apparent from the clinical examination. The advantage of CT was particularly evident in the nasopharynx (fig. 1), undoubtedly because of the difficulty in obtaining adequate clinical examination of that region. In the rest of the sites, the major contribution of CT was the documentation of submucosal extension of tumor that was not evident clinically (fig. 2). In 32 patients who had nodal metastasis at the time of presentation, two had significant adenopathy on CT that was not detected clinically. CT-guided biopsies were performed in both patients for confirmation.

The data were studied to determine the contribution of CT to clinical management. There were several criteria for "significant alteration" of clinical management: (1) detection of disease that was symptomatic but not apparent on clinical evaluation; (2) change of mode of therapy (e.g., radiation therapy instead of surgery); and (3) significant change in the surgical procedure or radiation portals that had been planned before the CT study. Using these criteria, CT significantly altered the clinical management of 36% of patients evaluated (table 2). When viewed by the site of tumor origin, the clinical impact of CT was again greatest in nasopharyngeal tumors. Indeed, over 25% of nasopharyngeal lesions diagnosed in this series were not apparent to the clinical examiner (fig. 1).

Two lesions in the piriform sinuses were also detected by CT examination alone. In the other cases, the contribution of CT was predominantly to document far more extensive tumor than had been apparent clinically (fig. 2). This usually resulted in a change of planned therapy from surgery to radiation therapy or a significant increase in the radiation therapy portals. In one case, a less aggressive surgical procedure was performed when clinically suspected orbital invasion was not confirmed by CT. In two cases, adenopathy was detected that had not been apparent clinically. In one case, a metastasis to the base of the skull was discovered. Two entirely mucosal lesions in the hypopharynx were not demonstrated by CT.

CT-guided biopsy was performed in 20 patients in this series. In 12 patients, it was used to confirm the presence of a primary lesion or to establish the histologic diagnosis in tumors that were clinically apparent but not amenable to routine biopsy. In five patients, sequential biopsies were performed at different sites to document the full extent of submucosal spread of tumor. In two patients, nodal metastases were biopsied, and in one patient a metastasis at the base of the skull was biopsied.

Discussion

Of the 35,000–40,000 new cases of head and neck cancer in the United States each year, death results in 65% [9]. About 90% of patients who die have uncontrolled local disease at the time of death [9].

Obviously, knowing the extent of the primary tumor is crucial in therapy selection for local control. Currently, the American Joint Committee for Cancer Staging and End Results Reporting manual contains the most commonly used "rules" for staging. At present, the manual requires that staging be based on careful clinical examination and radiographic evaluation only as necessary. CT is not a requirement for staging.

Our study indicates that the currently required methods for staging fail to detect the full local extent of tumor in about 25% of patients. Significant adenopathy is detected only by CT in 2% of all patients and in 6% of patients who present with adenopathy.

We speculate that some treatment failures, particularly in apparently limited disease [10, 11], may reflect failure to detect the full extent of tumor. Similarly, puzzling survival data, such as those showing T3 lesions having a better prognosis than T2 lesions [11], may be explained simply by incomplete staging. In addition, our study indicates that about 10% of tumors of the head and neck will not be apparent initially to the clinical examiner. Thus, CT should be performed when clinical symptoms warrant even if no tumor is apparent. Clearly diagnostic radiology can and should play a major role in evaluation of head and neck tumors. To be effective, CT examinations must be performed meticulously with a thorough knowledge of the anatomy and TNM staging criteria.

In conclusion, high-resolution CT scanning of the head and neck can make a substantial contribution to clinical management in more than one-third of cases. CT is valuable in several ways: (1) in detecting tumors not apparent clinically, usually

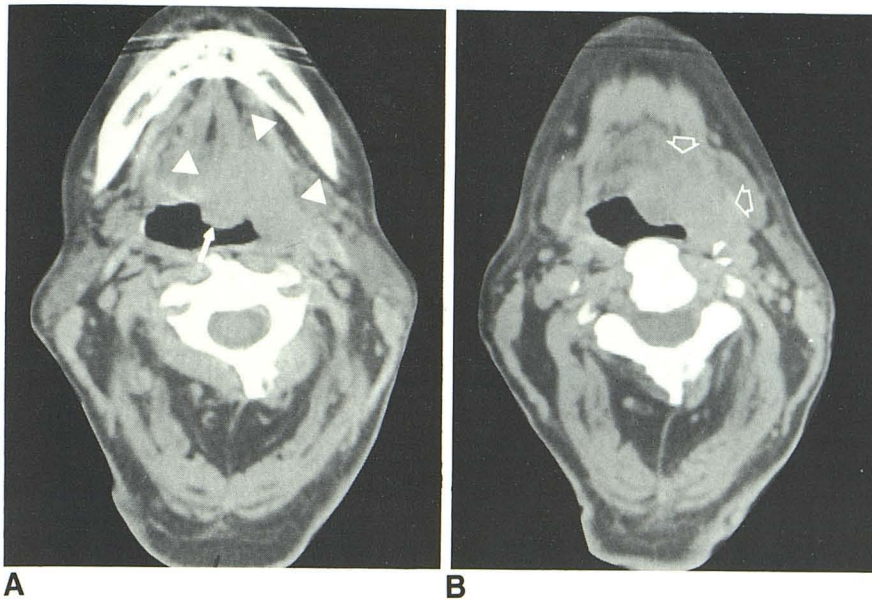


Fig. 1.—56-year-old woman with 1.5 × 1.5 cm mass projecting from base of tongue (closed arrow). Extension into floor of the mouth and left lateral oropharyngeal wall (arrowheads) and submandibular soft tissues (open arrows) not apparent clinically. Confirmed at surgery.

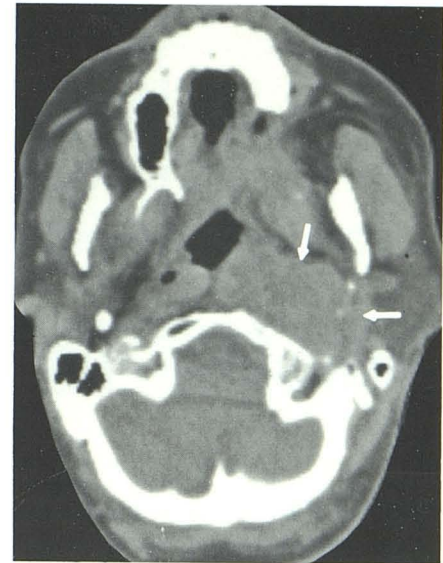

Fig. 2.—65-year-old man with left vocal cord paralysis. Physical examination was otherwise normal. Large, entirely submucosal squamous cell carcinoma in nasopharynx (arrows). Confirmed by CT-guided biopsy.

TABLE 2: Contribution of CT to the Clinical Management of Head and Neck Tumors

Tumor Site	Total No. of Patients	No. of Patients with CT Detection Superior to Clinical		
		Tumor not Apparent Clinically	More Locally Extensive than Evident Clinically	Total (%)
Oropharynx	38	0	12*	12 (32)
Nasopharynx	23	8	4*	12 (52)
Hypopharynx	14	2	2	4 (29)
Larynx	11	0	3	3 (27)
Sinus	10	0	3	3 (30)
Nasal cavity	4	0	2	2 (50)
Total	100	10	26	36

* Includes one patient in whom CT also detected adenopathy.

in areas difficult to examine (e.g., the nasopharynx), and (2) in more clearly delineating the extent of clinically apparent disease, generally because of submucosal extension or the documentation of nodal metastasis. We speculate that some treatment failures reported in apparently local disease may in fact have been from inadequate staging. We recommend that information from the CT examination of the head and neck be incorporated as a mandatory part of the TNM staging procedures.

REFERENCES

1. Silverberg E, ed. *National Cancer Institute's Surveillance, Epidemiology and End Results (SEER) Program (1973-1978)*. Cancer

Statistics, 1982. New York City: Statistical Information Services, Department of Epidemiology Society, 1982

2. Mancuso AA, Bohman L, Hanafee W, Maxwell D. Computed tomography of the nasopharynx: normal and variants of normal. *Radiology* 1980;137:113-121

3. Miller EM, Norman D. The role of computed tomography in the evaluation of neck masses. *Radiology* 1979;133:145-149

4. Mancuso AA, Harnsberger HR, Muraki AS, Stevens MH. Computed tomography of cervical and retropharyngeal lymph nodes: normal anatomy, variants of normal, and applications in staging head and neck cancer. Part I: Normal anatomy. *Radiology* 1983;148:709-714

5. Harnsberger HR, Muraki AS, Stevens MH. Computed tomography of cervical and retropharyngeal lymph nodes: normal anatomy, variants of normal, and applications in staging head and neck cancer. Part II. Pathology. *Radiology* 1983;148:715-723

6. Muraki AS, Mancuso AA, Harnsberger HR, Johnson LP, Meads GB. CT of the oropharynx, tongue base, and floor of the mouth: normal anatomy and range of variations, and applications in staging carcinoma. *Radiology* 1983;148:725-731

7. American Joint Committee for Cancer Staging and End Results Reporting. *Manual for staging of cancer*. Chicago: Whiting, 1978

8. Gatenby RA, Mulhern CB, Strawitz J. CT guided percutaneous biopsies of head and neck masses. *Radiology* 1983;146:717-719

9. Carter SK, Glatstein E, Livingston RB. *Principles of cancer treatment*. New York: McGraw-Hill, 1982

10. Fu KK, Lichter A, Galante M. Carcinoma of the floor of the mouth: an analysis of treatment, results and the sites and causes of failure. *Int J Radiat Oncol Biol Phys* 1976;1:829-837

11. Spanos WT Jr, Shukovsky LJ, Fletcher GH. Time, dose and tumor volume relationships in irradiation of squamous cell carcinomas of the base of the tongue. *Cancer* 1976;37:2591-2599