

Are your **MRI contrast agents** cost-effective?

Learn more about generic **Gadolinium-Based Contrast Agents**.



FRESENIUS
KABI

caring for life

AJNR

Cebocephaly: CT and sonographic findings.

S J McCorkell, A Ohlsson and F Probst

AJNR Am J Neuroradiol 1985, 6 (4) 647-649

<http://www.ajnr.org/content/6/4/647.citation>

This information is current as
of May 11, 2024.

Cebocephaly: CT and Sonographic Findings

Scott J. McCorkell,¹ Arne Ohlsson,² and Franz Probst*¹

Cebocephaly is a rare congenital abnormality combining a severe midline facial malformation and prosencephaly. Computed tomographic (CT) and sonographic findings in this syndrome are described.

Case Report

A 2760 g female infant was born at term to a gravida 6 para 5 mother after a normal pregnancy with no history of exposure to alcohol, teratogens, or ionizing radiation. Abnormal findings on physical examination were slight hypertonicity, respiratory distress in room air, and microcephaly (head circumference < -3 SD). The hard palate was intact. The anterior and posterior fontanelles were small, and hypotelorism was present. A single midfacial nostril was clinically patent but to assure adequate ventilation an oral airway was inserted

(fig. 1A). Chromosomal analysis was normal. The infant died of respiratory failure at 3 days of age.

Skull films showed severe hypotelorism, a single nostril, and hypoplasia of the sphenoid bone and maxilla (fig. 1B). A CT scan of the face and brain demonstrated the intact palate and single nostril with generalized hypoplasia of the facial bones. There was superior and medial fusion of the orbits with absence of ethmoidal structures. Separate optic nerves originated from normally formed globes but fused into a single structure before entering a single optic canal (fig. 2A). Scans through the midcranium showed an undivided thalamus and no third ventricle. A large single ventricle was present, surrounded by a small amount of undivided cerebral cortex. A large dorsal sac, filled with cerebrospinal fluid, occupied the rest of the intracranial space. The dorsal sac was connected to the single ventricle and separated from subdural fluid by a thin membrane (fig. 2B). A serpiginous central venous structure, the deformed vein of Galen, was

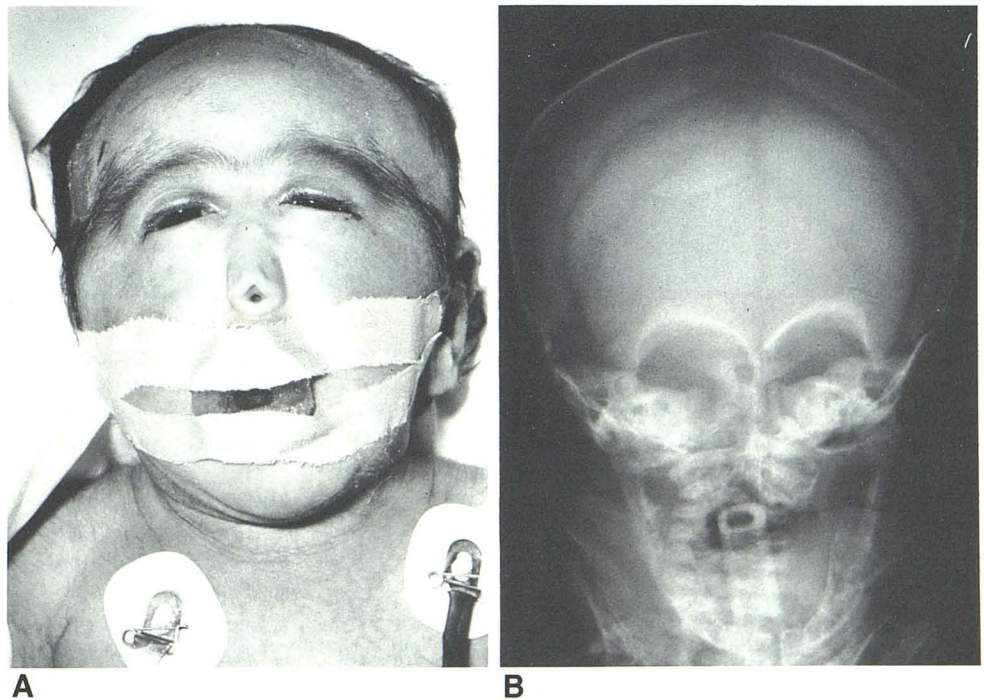


Fig. 1.—A, Typical facies of cebocephaly. Single nostril, microcranium, severe hypotelorism, and fused eyebrows. Oral airway is present. B, Plain skull film. Close-set orbits and hypoplasia of sphenoid bones. Single optic canal.

Received February 23, 1984; accepted after revision July 26, 1984.

* Deceased.

¹ Department of Radiology, King Faisal Specialist Hospital, P.O. Box 3354, Riyadh 11211, Saudi Arabia. Address reprint requests to S. J. McCorkell.

² Department of Pediatrics, Division of Neonatology, King Faisal Specialist Hospital, Riyadh 11211, Saudi Arabia.

AJNR 6:647-649, July/August 1985 0195-6108/85/0604-0647 \$00.00 © American Roentgen Ray Society

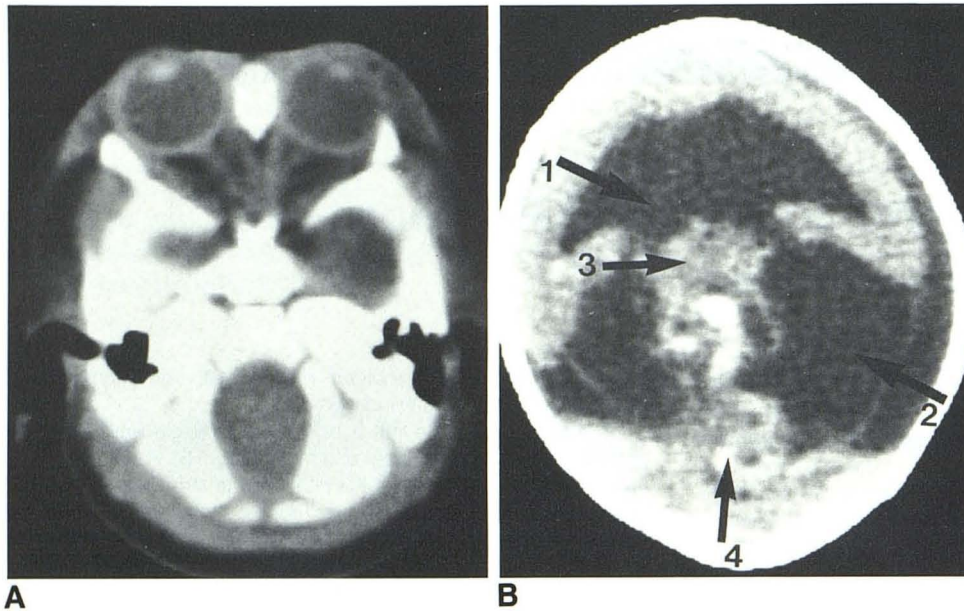


Fig. 2.—CT scans. **A**, Medial fusion of orbits. Ethmoid air cells are absent. Optic nerves are incompletely divided and fuse before entering single optic canal. **B**, At level of midcranium. Anteriorly, single ventricle (arrow 1) is surrounded by undivided brain substance. Parts of cerebrospinal fluid-filled dorsal sac (arrow 2). Undivided thalamus (arrow 3); enlarged and serpiginous vein of Galen after contrast enhancement (arrow 4).

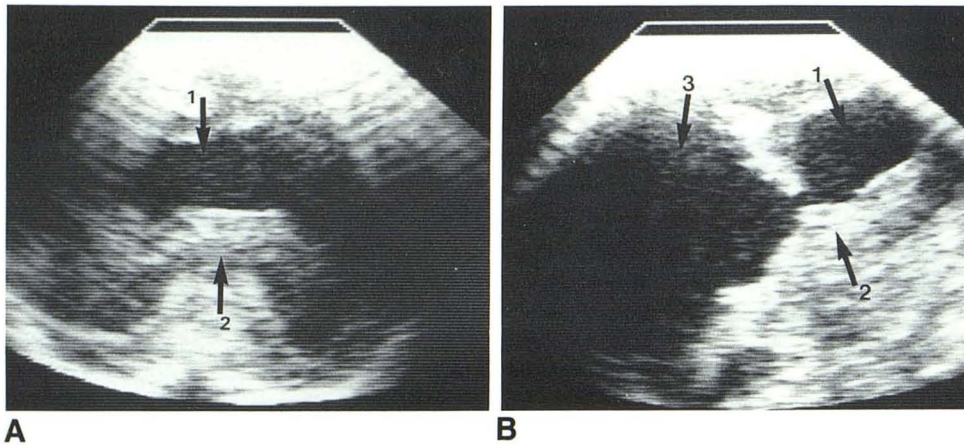


Fig. 3.—**A**, Coronal sonogram. Single ventricle (arrow 1) and undivided thalamus (arrow 2). **B**, Sagittal sonogram. Single ventricle (arrow 1), undivided thalamus (arrow 2), and dorsal sac (arrow 3).

well demonstrated after intravenous administration of contrast material. Scans at higher levels (not shown) failed to show midline structures such as the septum pellucidum or falx cerebri. Posterior fossa structures were present and normal. Sonography (fig. 3) confirmed the presence of an undivided thalamus, single ventricle, and showed the dorsal cyst well.

Discussion

Cebocephaly belongs to a spectrum of midline cerebrofacial malformations that have been well recognized for centuries due to their characteristic appearance. Greek writers were familiar with at least one form, although it is unlikely that an individual afflicted with cyclopia could obtain adulthood as in Homer's *Odyssey*. DeMeyer [1] classified the cerebrofacial malformations in order of descending severity: cyclopia, ethmocephaly, cebocephaly, median cleft lip, and orbital hypotelorism with hypoplastic intermaxillary segment.

Cyclopia, ethmocephaly, and cebocephaly are consistently associated with severely malformed brains of the prosencephaly spectrum. The presence of prosencephalic brains in infants with the other two malformations is variable. Prosencephalic brains may also occur with normal facial structures [2].

The clinical characteristics of cebocephaly are a flat rudimentary nose with a single nostril, extreme orbital hypotelorism, fused eyebrows, and trigonocephaly (fig. 1A). Corresponding internal orbitofacial abnormalities, best seen with CT, include posteriorly fused or incompletely separated optic nerves and optic canals and hypoplasia or absence of ethmoid air cells, nasal septum, and turbinates. A dysplastic hard palate and hypoplasia of the maxilla may also be present.

Newborn infants with prosencephaly may have difficulty maintaining homeostatic functions due to dysmorphic changes in diencephalic and brainstem centers. Wide swings in body temperature and endocrine insufficiencies have also

been described. Associated dysplasias or hypoplasias of the pituitary, thyroid, and adrenal glands are sometimes present [3]. Malformations of the genital structures and viscera have also been reported [4]. In this case, although there were no extracranial abnormalities, the infant was unable to maintain body temperature and died from impaired respiratory function.

Chromosomal abnormalities including trisomy of chromosomes 13 and 18 have been associated with cebocephaly [5]. However, since cebocephaly also occurs with normal karyotypes it is not thought to be the result of a specific chromosomal aberration. Both gene mutations and environmental factors such as drugs and ionizing radiation have been suggested as a cause. Thalidomide [6] and alcohol [7] can produce similar cerebrofacial malformations in animals. This may be of clinical importance as experimentally induced defects resemble severe forms of fetal alcohol syndrome in humans. Our patient was not exposed to alcohol, drugs, or ionizing radiation antenatally.

Although all neuroimaging methods can demonstrate the intracerebral abnormalities in cebocephaly, sonography is easy to perform and shows the dorsal sac particularly well. CT demonstrates both the brain and facial abnormalities.

Cebocephaly is usually fatal in the early neonatal period but survival to age 8 months has been reported [8]. The single nostril is often obstructed and is functionally similar to com-

plete choanal atresia. The decision to intubate a child affected with cebocephaly should be tempered with the knowledge that prosencephalic brain malformations always accompany the typical facies of cebocephaly.

REFERENCES

1. DeMeyer W. Classification of cerebral malformations. *Birth Defects* **1971**;5:78-93
2. Probst FP. Neuroradiology. In: Probst FP, ed. *The prosencephalies*. Berlin: Springer-Verlag, **1979**:69-90
3. Haworth JC, Medovy H, Lewis AJ. Cebocephaly with endocrine dysgenesis. *J Pediatr* **1961**;59:726-733
4. Warkany J. Cyclopia-rhinencephaly series. In: Warkany J, ed. *Congenital malformations*. Chicago: Year Book Medical, **1976**:206-207
5. Lazjuk GI, Lurie IW, Nedzved MK. Further studies on the genetic heterogeneity of cebocephaly. *J Med Genet* **1976**;13:314-318
6. Mikami T, Matsubara Y, Suzuki Y, Chiba T. The critical period for inducing cranio-facial malformations by thalidomide in JW-NIBS rabbits. *Congenital Anomalies* **1982**;22:173-176
7. Sulik KK, Johnston MC. Embryonic origin of holoprosencephaly: interrelationship of the developing brain and face. *Scan Electron Microsc* **1982**;1:309-322
8. Morison JE. Central nervous system. In: Morison JE, ed. *Foetal and neonatal pathology*. London: Butterworths, **1974**:525-549