

Are your **MRI contrast agents** cost-effective?

Learn more about generic **Gadolinium-Based Contrast Agents**.



FRESENIUS
KABI

caring for life

AJNR

The behavior of Pantopaque on MR: in vivo and in vitro analysis.

I F Braun, J A Malko, P C Davis, J C Hoffman, Jr and L H Jacobs

AJNR Am J Neuroradiol 1986, 7 (6) 997-1001

<http://www.ajnr.org/content/7/6/997>

This information is current as
of April 18, 2024.

The Behavior of Pantopaque on MR: In Vivo and In Vitro Analyses

Ira F. Braun¹
 John A. Malko
 Patricia C. Davis
 James C. Hoffman, Jr.
 Louis H. Jacobs

MR imaging is considered by many to be the procedure of choice in imaging the spinal cord; yet we encountered an important pitfall of this procedure in the form of a patient with retained intraspinal Pantopaque. The results of this case are presented as well as those obtained in another patient with retained Pantopaque. Also described is the behavior of this contrast material when using in vitro imaging data obtained from a CSF/Pantopaque phantom. When T1-weighted imaging sequences are used, Pantopaque gives a high signal and CSF gives a low signal. With long repetition time, (e.g., 4000 ms), the CSF signal is high and the Pantopaque signal is not. With repetition time around 1000 to 2000, both may be isointense. The implications of these findings are discussed.

MR imaging of the spine is considered by many investigators to be the imaging procedure of choice for investigating disorders of the spinal cord [1, 2]. We describe our discovery of an important imaging pitfall in MR of the spine, first presented by our group [3] in a patient who had undergone previous Pantopaque myelography. Similar findings from another study were subsequently reported by Mamourian and Briggs [4]. Further, we report our results on imaging a simple Pantopaque/CSF phantom. The phantom results predict the behavior of the CSF in response to Pantopaque contrast observed in our in vivo spine imaging with the various pulse sequences commonly used clinically.

Materials and Methods

All MR images, both clinical and experimental, were obtained from a Philips Gyroscan superconducting unit (Philips Medical Systems, Shelton, CT) operating at 0.5 T. For our initial patient, coronal and sagittal spin-echo images were obtained in the standard body coil using a TR of 600 and a TE of 30 and 60 msec. Sagittal spin-echo images using both the body coil and a surface coil were obtained in the second patient using TRs of 500, 2000, and 4000 and TEs of 30 to 200 msec.

Experimental Data

To study the behavior and relative intensity changes to be expected in clinical cases, a simple phantom was constructed comprising a glass tube containing equal amounts of Pantopaque and normal CSF. This phantom was then imaged using TR values of 500, 1000, 2000, and 4000 msec, and TE values of 30, 60, 90, and 120 msec. In addition, using a mixed sequence and varying pulse-sequence parameters of TR, TE, and TI, we obtained calculated values of T1 (~150 msec) and T2 (~40 msec) for Pantopaque.

Clinical Data

The first patient was a 50-year-old woman who presented with a progressive

Received February 25, 1986; accepted after revision May 3, 1986

¹ All authors: Department of Radiology, Section of Neuroradiology, Emory University School of Medicine, 1365 Clifton Road, N.E., Atlanta GA 30322. Address reprint requests to I. F. Braun.

AJNR 7:997-1001, November/December 1986

0195-6108/86/0706-0997

© American Society of Neuroradiology

paraparesis with an approximate T9 level, right greater than left, associated with increasing back pain. A previous myelogram had been interpreted as normal. A repeat myelogram was requested by the referring clinician, but refused by the patient. She was referred for an MR study.

The second patient was a 30-year-old man who presented with low back pain. He had had a previous Pantopaque myelogram, and plain films revealed a significant amount of retained Pantopaque in the canal.

Results

The MR study of our first patient obtained with a T1-weighted sequence is shown in Figures 1A and 1B. A linear area of hyperintensity was thought to represent an elongated intradural extramedullary tumor or perhaps a blood clot, and the patient was scheduled for subsequent surgery. T2-weighted images were not obtained. Prior to surgery, however, on a routine preoperative review of plain films, the presence of a collection of retained intraspinal Pantopaque in a similar location as the linear hyperintensity was noted (Fig. 1C). Metrizamide myelography, performed to rule out an intraspinal lesion in this location, was performed followed by a CT study (Figs. 1D–1F). These were interpreted as normal. The area of hyperintensity was then thought to represent retained Pantopaque.

The MR study of a second patient was performed using both T1- and T2-weighted sequences as shown in Figures 2A–2H, corroborating the results obtained in our phantom studies (see below). Initially, on T1-weighted images, CSF is hypointense with respect to Pantopaque. As the relative T2 weighting increases, they become isointense to each other and, finally, with greater T2 weighting, CSF is hyperintense relative to Pantopaque. For comparison purposes, plain films are shown in Figures 2I and 2J.

The images obtained with the CSF/Pantopaque test-tube phantom are shown in Figures 3 and 4. The images were obtained from 5-mm-thick single-slice spin-echo sequences with the tube carefully positioned so as to minimize partial volume effects. Figure 3 shows the effect of varying TR with TE fixed at 30 msec (used to obtain T1 information). CSF at a TR of 500 msec initially starts out less intense relative to Pantopaque and gradually increases in intensity as the TR is lengthened. At a TR of 4000 msec, the relative intensity of Pantopaque to CSF is reversed, with CSF now brighter. These findings are consistent with CSF having a longer T1 than Pantopaque. It is also apparent that there is a discrete TR, between 1000 and 2000 msec, at which point both substances are isointense relative to each other.

Information about relative differences in T2 relaxation times between Pantopaque and CSF and their effects on images is shown in Figure 4, where TR was kept constant at 500 msec

and the TE varied from 30 to 120 msec. At a TE of 30 msec, CSF is less intense than Pantopaque. As the TE is lengthened, the substances go through a point at which they are isointense to each other; eventually, as the TE is increased further, CSF becomes increasingly hyperintense with respect to Pantopaque. This behavior is due to CSF having a longer T2 relaxation time than that of Pantopaque.

Discussion

Pantopaque, introduced in 1941 as a contrast material for myelography [5], is a mixture of ethylesters of isomeric, iodophenylundecyclic acids containing 30.5% firmly bound organic iodine. The clinical use of this contrast agent has declined dramatically in recent years owing to the introduction of safe, water-soluble contrast media for myelography. However, because of the slow rate of absorption of Pantopaque, estimated to be 1 ml per year [6], a significant number of patients referred for MR imaging of the spine will still have considerable amounts of this contrast material retained in their thecal sacs. In addition, in England, according to Shapiro [7], Pantopaque is normally left in the canal after myelography. The scope of this potential imaging problem, made evident to us by our initial case, prompted us to investigate this problem in greater depth using the phantom.

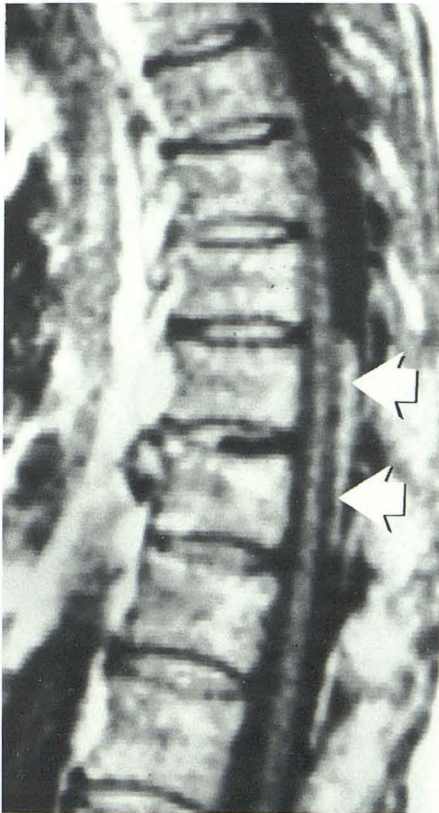
The results obtained from both the *in vivo* and *in vitro* image experiments are in agreement with the relaxation times obtained by us with Pantopaque and with the published relaxation times for CSF. The relative intensities on T1- and T2-weighted sequences in the clinical material are also consistent with the data in our *in vitro* experiment with the phantom.

A minor point that bears mentioning is the inconsistency in referring to Pantopaque as an MR contrast agent [4]. An MR contrast agent should be a compound that, when taken up by an organ or tissue, changes the relaxation times of that organ or tissue and thereby affects the appearance of an image obtained with a particular pulse sequence. Pantopaque does none of these; its appearance is determined solely by its own unique MR parameters.

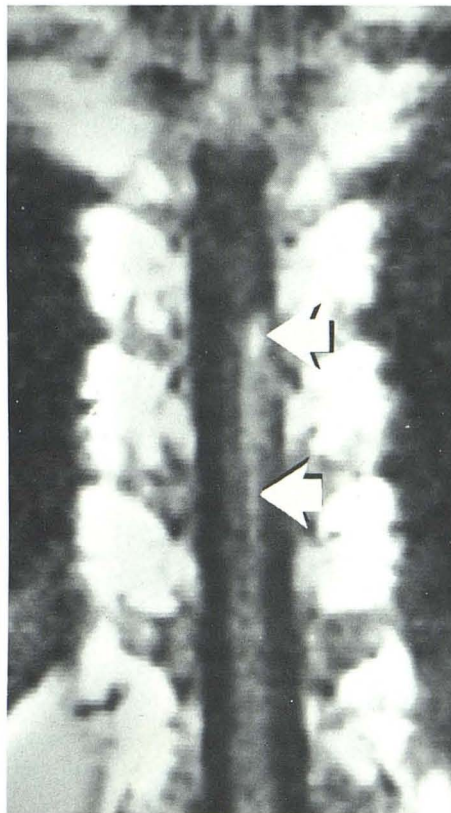
A potential problem might arise if the iodine moiety of Pantopaque were to dissociate from the remainder of the molecule and either become dispersed in the CSF or excreted. In this instance, the noniodinated Pantopaque would not attenuate the X-ray beam and therefore the presence of Pantopaque would not be realized on plain radiography, while the relaxation characteristics could still lead to false-positive diagnoses on MR. However, the authors of this paper were assured by staff members of the research and development department of Lafayette Pharmacal, Inc. (manufacturer of Pantopaque) that the iodine-benzene bond in Pantopaque is most stable and could only be cleaved with great difficulty in the laboratory (personal communication).

Fig. 1.—Sagittal (A) and coronal (B) MR images obtained with standard body coil using a 10-mm slice. TR = 600 msec, TE = 30 msec. A linear area of hyperintensity (*arrows*) is seen on both images. Lateral plain film (C) of lower thoracic spine reveals presence of residual intraspinal Pantopaque in a location corresponding to area of linear hyperintensity seen in A and B. Anteroposterior

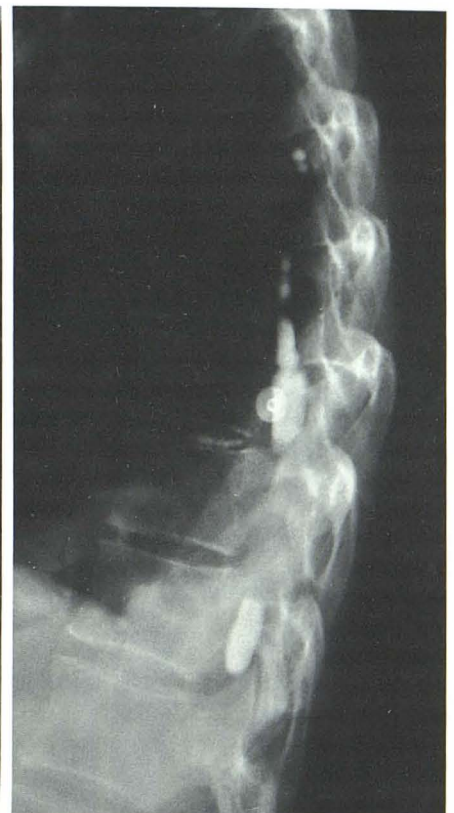(D) and lateral (E) views obtained after intrathecal administration of water-soluble contrast material reveal presence of persistent Pantopaque in an otherwise unremarkable myelographic image. Axial CT study (F) performed through low thoracic region after the myelogram. No abnormality is depicted.



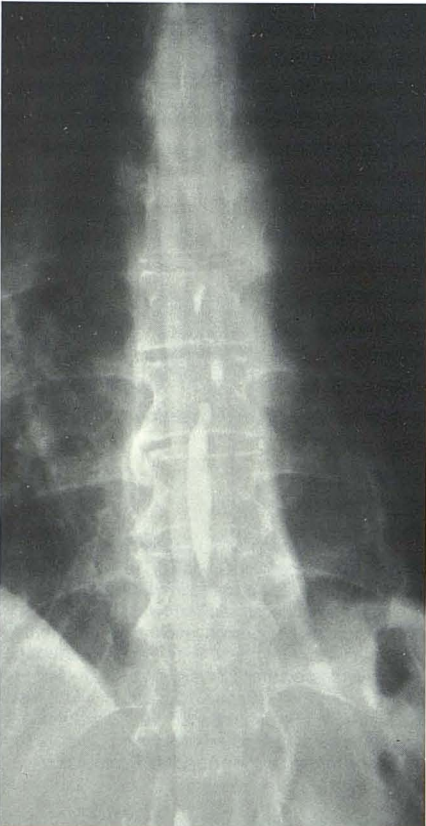A



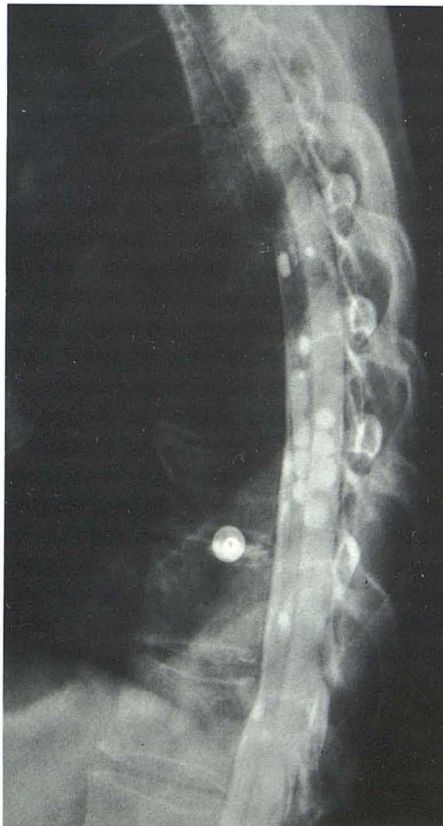B



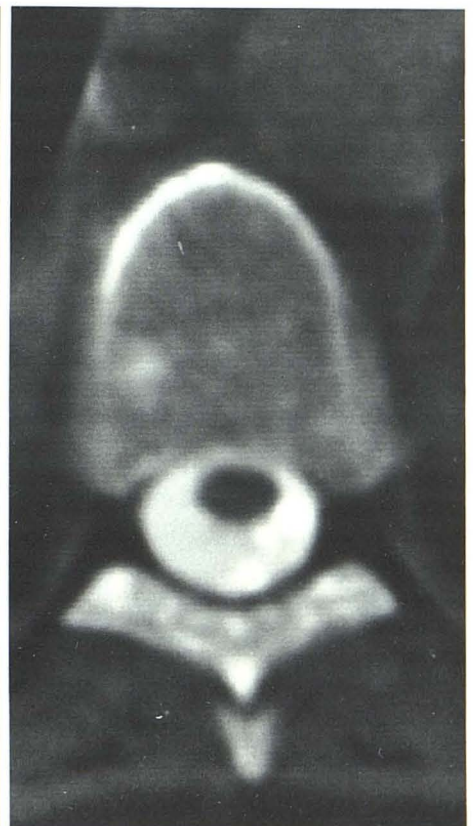
C



D



E



F

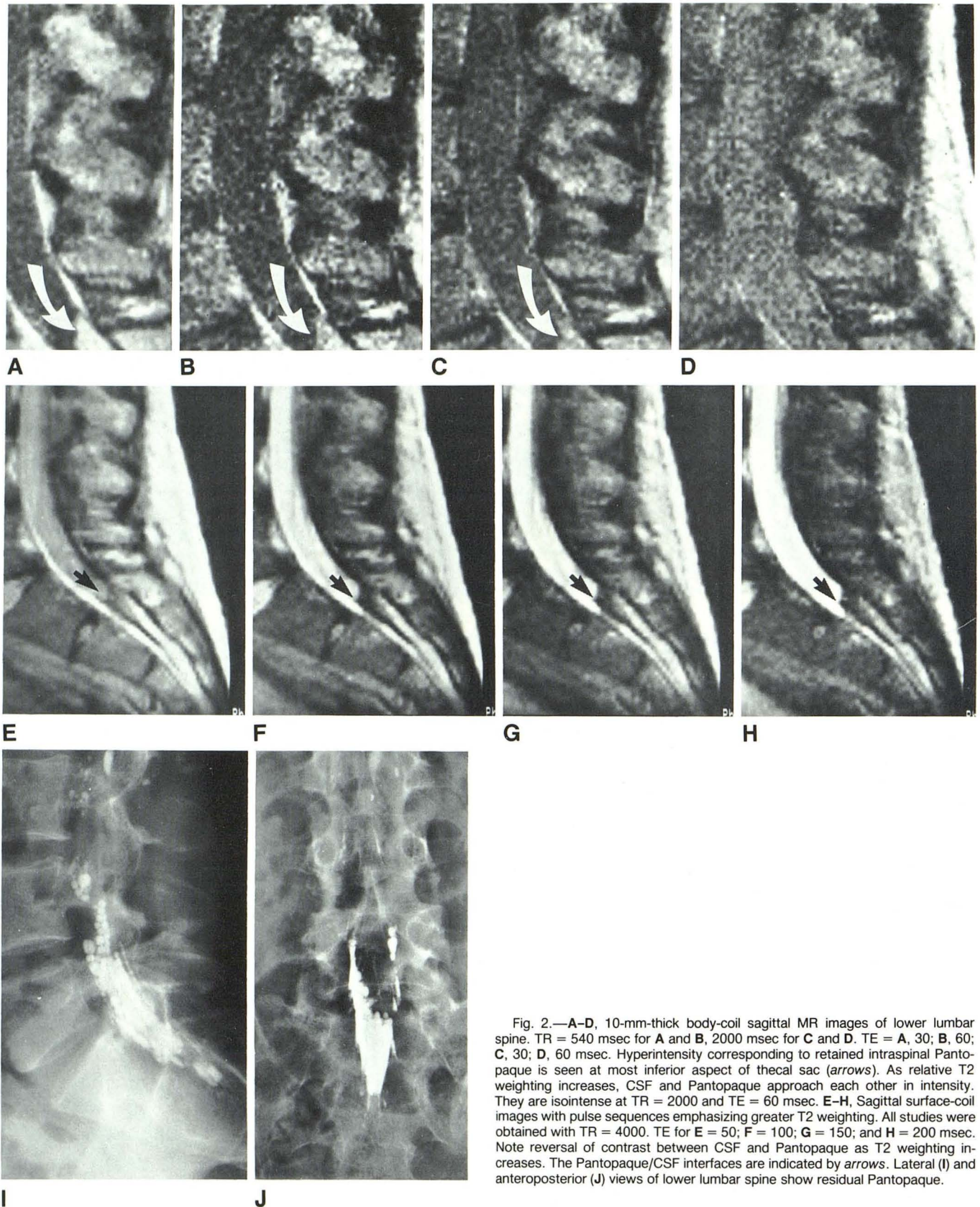
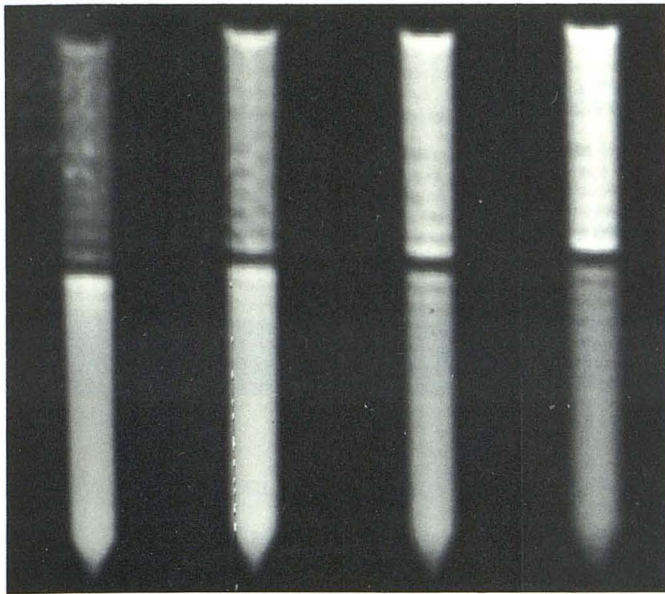
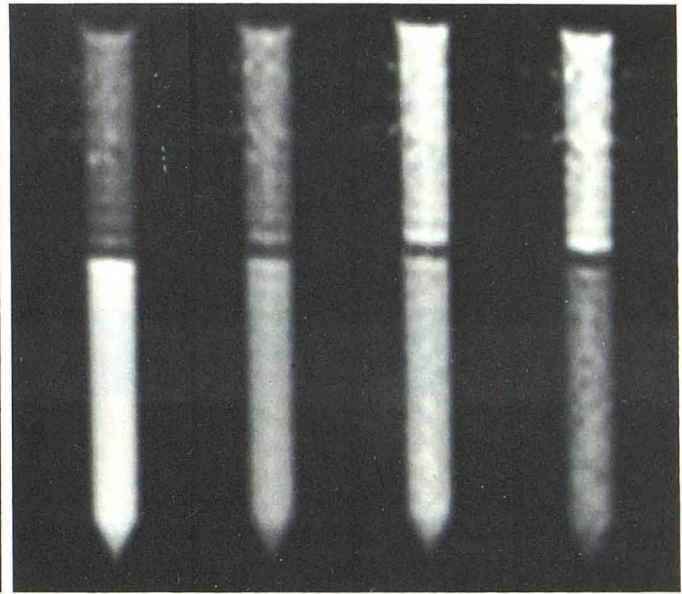


Fig. 2.—A-D, 10-mm-thick body-coil sagittal MR images of lower lumbar spine. TR = 540 msec for A and B, 2000 msec for C and D. TE = A, 30; B, 60; C, 30; D, 60 msec. Hyperintensity corresponding to retained intraspinal Pantopaque is seen at most inferior aspect of thecal sac (arrows). As relative T2 weighting increases, CSF and Pantopaque approach each other in intensity. They are isointense at TR = 2000 and TE = 60 msec. E-H, Sagittal surface-coil images with pulse sequences emphasizing greater T2 weighting. All studies were obtained with TR = 4000. TE for E = 50; F = 100; G = 150; and H = 200 msec. Note reversal of contrast between CSF and Pantopaque as T2 weighting increases. The Pantopaque/CSF interfaces are indicated by arrows. Lateral (I) and anteroposterior (J) views of lower lumbar spine show residual Pantopaque.



3

Fig. 3.—Phantom images obtained with a fixed TE of 30 msec and a varying TR of 500, 1000, 2000, and 4000 msec, left to right, respectively. For details, see text. CSF occupies upper portion of tube while Pantopaque occupies lower portion. A bandlike area of negligible signal intensity between the two solutions is formed by trapped air bubbles.



4

Fig. 4.—Images of the phantom obtained at a constant TR of 500 msec and a varying TE of 30, 60, 90, and 120 msec, left to right, respectively. These images provide information about relative differences in T2 relaxation time between Pantopaque and CSF. See text for further explanation.

Conclusions

If an area of abnormal intraspinal intensity is seen in a patient who has undergone previous myelography, plain films should be scrutinized for evidence of retained Pantopaque. Pantopaque may simulate intraspinal fat or hemorrhage on MR imaging.

REFERENCES

1. Norman D, Mills CM, Brant-Zawadzki M, Yeates A, Crooks LE, Kaufman L. Magnetic resonance imaging of the spinal cord and canal: potentials and limitations. *AJR* **1983**;141:1147-1152, *AJNR* **1984**;5:15-22
2. Han JS, Kaufman B, El Yousef, et al. NMR imaging of the spine. *AJR* **1983**;141:1137-1145, *AJNR* **1983**;1151-1159
3. Braun IF, Hoffman JC, Malko JA, Davis PC, Kibble M. MR imaging of intraspinal Pantopaque. Presented at the 71st scientific assembly and annual meeting of the RSNA, Chicago, November **1985**
4. Mamourian AC, Briggs RW. Appearance of Pantopaque on MR images. *Radiology* **1986**;158:457-460
5. Steinhausen TB, Dungan CE, Furst JB, et al. Iodinated organic compounds as contrast media for radiographic diagnoses. III. Experimental and clinical myelography with ethyl iodophenylundecylate (Pantopaque). *Radiology* **1944**;43:230-235
6. Ramey GH, French JD, Strain WH. Iodinated organic compounds as contrast media for radiographic diagnoses. IV. Pantopaque myelography. *Radiology* **1944**;43:236-240
7. Shapiro R. *Myelography*, 4th ed. Chicago: Year Book Medical, **1984**:8