

Are your **MRI contrast agents** cost-effective?

Learn more about generic **Gadolinium-Based Contrast Agents**.



FRESENIUS
KABI

caring for life

AJNR

Intense brain cortical enhancement on CT in laminar necrosis verified by biopsy.

B H Liwnicz, M D Mouradian and J B Ball, Jr

AJNR Am J Neuroradiol 1987, 8 (1) 157-159

<http://www.ajnr.org/content/8/1/157.citation>

This information is current as
of April 19, 2024.

Intense Brain Cortical Enhancement on CT in Laminar Necrosis Verified by Biopsy

Boleslaw H. Liwnicz,¹ Maral D. Mouradian,² and James B. Ball, Jr.³

Anoxia of the cortical gray matter of the CNS may result from a variety of pathophysiologic conditions, including systemic hypoxemia, cerebral hypoperfusion, hypoglycemia, and carbon monoxide or cyanide poisoning. Areas of the brain with high metabolic demand or in boundary zones of perfusion are more vulnerable to tissue anoxia than other areas are [1]. The increased susceptibility of the cerebral cortex and the basal ganglia in CNS anoxia is seen at autopsy and can be identified on CT. We report a case of laminar necrosis of the cerebral cortex that was seen as intense, diffuse cortical enhancement on double-dose, delayed, contrast-enhanced CT, and was subsequently confirmed by biopsy.

Case Report

A 39-year-old man with a history of chronic undifferentiated schizophrenia was admitted to a hospital because of severe vomiting and diarrhea, diagnosed as gastroenteritis. He was noted to have decreased speech and to be withdrawn. He was transferred after a week to our hospital. His family reported that his condition was different than the previous acute exacerbations of his psychosis. His medications included intramuscular injections of fluphenazine decanoate.

On admission, the patient was stuporous. Blood pressure was 150/114 mmHg; pulse, 80 beats/min; respiration, 18/min and unlabored; rectal temperature, 37.6°C. Examination of the head and neck showed no evidence of trauma or neck stiffness. The chest was clear; cardiovascular and abdominal examinations were unremarkable. He was unresponsive to verbal stimuli, but withdrew his extremities in response to pain. He was totally mute. Occasionally he opened his eyes spontaneously. His pupils were 3 mm and reactive. Eye movement was elicited by rotation of the head. There was no papilledema. The muscle tone was increased bilaterally, with hyperactive muscle stretch reflexes and flexor plantar responses. Hemogram, serum sodium, glucose, and arterial blood gases were normal. Liver function tests and ammonia level were unremarkable. Electrocardiogram was normal. Serum and urine screening tests for alcohol, tricyclic antidepressants, narcotics, barbiturates, phenothiazines, benzodiazepine, and lithium were negative except for a small quantity

of hydroxyzine. Urinary porphyrins were normal and serologic tests for syphilis were negative both in serum and CSF. The CSF had normal pressure and glucose, cells within normal limits, protein level of 50 mg/dl (normal up to 45 mg/dl), normal IgG index, and no oligoclonal bands. Fungal, mycobacterial, and viral studies were all negative. The electroencephalogram showed diffuse slowing in the theta range intermixed with occasional delta activity. Arousal stimuli caused no change in the background.

An unenhanced CT scan of the head obtained on admission (Fig. 1A) demonstrated bilateral lenticular nucleus low-attenuation zones. The CT scan was repeated on day 5, before and after contrast enhancement with 45 l, and showed an additional low-density area in the head of the left caudate nucleus (Figs. 1B and 1C) and multiple small foci of enhancement at the gray-white interface (not shown). The neurologic condition of the patient was unchanged. He developed aspiration pneumonia, which was treated successfully. A third CT scan was obtained on day 16 after a double dose (90 l) of intravenous contrast infusion and 30 min delay. It showed marked enhancement of the cerebral gray matter, especially in areas adjacent to the sylvian fissures, tentorium, and anterior interhemispheric fissure (Fig. 1D).

Meningoencephalitis was suspected, and a right temporal biopsy was performed 3 weeks after admission to our hospital. Microscopic examination revealed laminar necrosis in layers three to five (Fig. 2A). There was loss of neurons, marked capillary proliferation, and minimal mononuclear infiltration (Fig. 2B).

Six weeks later the patient was discharged to a nursing home with severe impairment of higher mental functions.

Discussion

Cerebral cortical laminar necrosis in this case is thought to be due to prolonged global cerebral hypoperfusion secondary to volume depletion. Hypoperfusion is known to cause secondary anoxic-like changes. The predominant CT finding was marked diffuse cortical enhancement. The increased contrast enhancement on CT scan, likely accentuated by the double-dose delayed technique used, resulted from the disruption of the blood-brain barrier, which was documented on biopsy as cortical necrosis with vascular proliferation. Such a cortical enhancement pattern has been reported in two of 10 cases

Received January 8, 1985; accepted after revision April 8, 1985

This work was supported by GAR Foundation.

¹ Department of Pathology and Laboratory Medicine, University of Cincinnati, College of Medicine, 231 Bethesda Ave., Cincinnati, OH 45267. Address reprint requests to B. H. Liwnicz.

² Department of Neurology, University of Cincinnati, College of Medicine, Cincinnati, OH 45267.

³ Department of Radiology, University of Cincinnati, College of Medicine, Cincinnati, OH 45267.

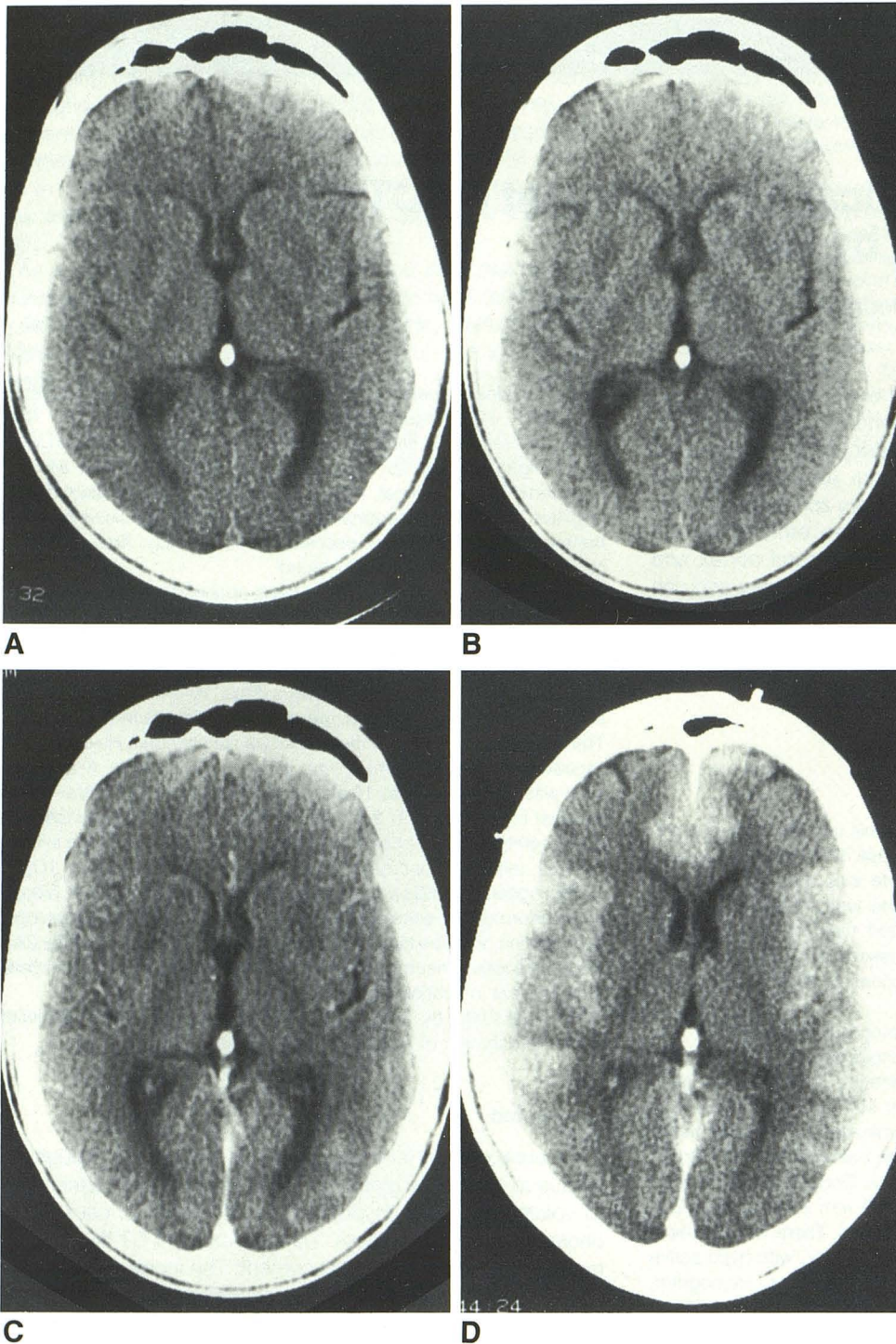


Fig. 1.—Sequential axial CT scans at approximately the same level.

A, Noncontrast CT on admission. Subtle areas of low attenuation in lenticular nuclei bilaterally.

B and C, Noncontrast and contrast-enhanced CT, respectively, on day 5. An additional zone of low attenuation in head of left caudate nucleus.

D, Double-dose contrast-enhanced CT on day 16. Intense cortical enhancement, especially adjacent to sylvian fissures and in anterior interhemispheric fissure. Other sections demonstrated increased enhancement adjacent to tentorium bilaterally.

of global CNS hypoperfusion [2] and in hypoglycemia [3, 4]. Marked diffuse hypodensity of cerebral and cerebellar cortices are also known to occur with profound cerebral hypoxia [5].

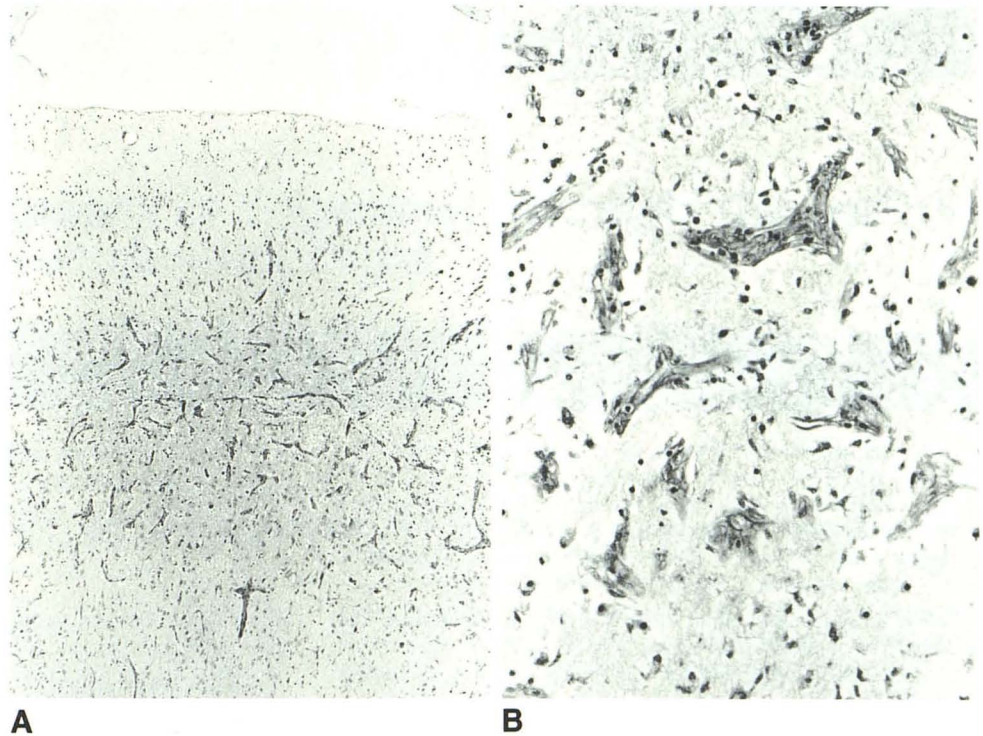
In addition, hypodensity was seen in the head of the caudate nucleus and in lenticular nuclei in our case. The basal ganglia structures are also vulnerable to anoxia because of

their high metabolic demand and their boundary-zone blood supply. On CT they may be hypodense [5] or show contrast enhancement [6, 7]. They are frequently involved in carbon monoxide [8–10] and cyanide poisoning [11]. It has been suggested that diffuse cortical and basal ganglia involvement in anoxic encephalopathy secondary to hypoperfusion is due to a moderate but prolonged hypoperfusion rather than to

Fig. 2.—Biopsy of brain cortex.

A, Laminar necrosis of cerebral cortex, most prominent in layer three, but also involving layers four and five. (H and E $\times 50$)

B, Layer three of cerebral cortex demonstrating neuronal loss and abundant vascular proliferation. (H and E $\times 250$)



more precipitous and severe low-blood-flow states that result in infarcts at the boundary zones [12]. A less common CT pattern in anoxic encephalopathy is that of white-matter low densities with preservation of the gray matter [13] due to demyelination with relative preservation of the axons and their cortical neuronal perikarya [14]. The latter was not seen in our case.

This report emphasizes that the diagnosis of anoxic encephalopathy is not always evident clinically. The CT picture of intense diffuse cortical enhancement may result from such encephalopathy. The recognition of such a CT pattern even without an appropriate history and laboratory data may be strongly suggestive of anoxic encephalopathy.

ACKNOWLEDGMENT

The authors thank Jay Card for his expert photographic assistance.

REFERENCES

- Brierley JB. Cerebral hypoxia. In: Blackwood W, Consellis J, eds. *Greenfield's neuropathology*, 3rd ed. Edinburgh: Edward Arnold, 1976:43-85
- Kjos BO, Brant-Zawadzki M, Young RG. Early CT findings of global central nervous system hypoperfusion. *AJNR* 1983; 4:1043-1048, *AJR* 1983;141:1227-1232
- Richardson ML, Kinard RE, Gray MB. CT of generalized gray matter infarction due to hypoglycemia. *AJNR* 1981;2:366-367
- Kaiser MC, Pettersson H, Harwood-Nash DC, Fitz CR, Chuang S. Case report. Computed tomography of the brain in severe hypoglycemia. *J Comput Assist Tomogr* 1981;5(5):757-759
- Tippin J, Adams HP, Smoker WRK. Early computed tomographic abnormalities following profound cerebral hypoxia. *Arch Neurol* 1984;41:1098-1100
- Wackenheim A, Jeanmart L, Baert AL. *Craniocerebral computer tomography. Confrontations with neuropathology*. Berlin: Springer-Verlag, 1980: 65-67
- Ramsey RG. *Neuroradiology with computed tomography*. Philadelphia: Saunders, 1981:397-398
- Kim KS, Weinberg PE, Suh JH, Ho SU. Acute carbon monoxide poisoning: computed tomography of the brain. *AJNR* 1980;1:399-402
- Kobayashi K, Isaki K, Fukutani Y, et al. CT findings of the interval form of carbon monoxide poisoning compared with neuropathological findings. *Eur Neurol* 1984;23:34-43
- Laplane D, Baulac M, Widlocher D, Dubois B. Pure psychic akinesia with bilateral lesions of basal ganglia. *J Neurol Neurosurg Psych* 1984;47:377-385
- Finelli PF. Case report. Changes in the basal ganglia following cyanide poisoning. *J Comput Assist Tomogr* 1981;5(5):755-756
- Adams JH, Brierley JB, Conner RCR, Triep CS. The effects of systemic hypotension upon the human brain. Clinical and neuropathological observations in 11 cases. *Brain* 1966;89:235-268
- Yagnik P, Gonzalez C. White matter involvement in anoxic encephalopathy in adults. *J Comput Assist Tomogr* 1980;4(6):788-790
- Plum F, Posner JB, Hain RF. Delayed neurological deterioration after anoxia. *Arch Intern Med* 1962;110:18-25