Are your MRI contrast agents cost-effective?
Learn more about generic Gadolinium-Based Contrast Agents.
FRESENIUS KABI
caring for life

AJNR

Acute subdural hematoma mimicking epidural hematoma on CT.

J Braun, B Borovich, J N Guilburd, M Zaaroor, M Feinsod and I Grushkiewicz

AJNR Am J Neuroradiol 1987, 8 (1) 171-173
http://www.ajnr.org/content/8/1/171.citation

This information is current as of April 19, 2024.

Acute Subdural Hematoma Mimicking Epidural Hematoma on CT

J. Braun,[1] B. Borovich,[2] J. N. Guilburd,[2] M. Zaaroor,[2] M. Feinsod,[2] and I. Grushkiewicz[2]

The characteristic feature of acute subdural hematoma (ASDH) when located over the convexity is that of a hyperdense crescentic area that conforms to the underlying cerebral surface and extends over most of the subdural space. Epidural hematoma (EDH), on the other hand, adopts a biconvex shape that is fundamentally focal in nature. During a 4½-year period two of 25 operatively proven cases of ASDH had a CT appearance of EDH. CT differential diagnosis is very difficult. The following cases are presented because, to our knowledge, this occurrence has not previously been recorded.

Case Reports

Case 1

A 78-year-old woman with bone marrow failure fell and struck her head. Two hours later she lost consciousness. On arrival she was comatose and manifested bilateral alternating purposeful and decerebrate movements on painful stimuli. Blood studies showed hemoglobin 6.5 g/dl, leukocytes 2300, granulocytes 18%, platelets 22,000, and normal prothrombin and partial thromboplastin time. By the time bone marrow aspiration and biopsy were done there was already an active erythropoiesis with normal myelopoiesis and megakaryocyte count. Skull radiographs were normal. CT scan showed bilateral biconvex extracerebral hematomas over the cerebral convexities. A clear interface divided the hematomas into an upper small hypodense zone and a lower large hyperdense zone (Fig. 1). After compensation of the patient's pancytopenia, the hematomas were evacuated. They were both ASDHs formed by blood clots and fluid and there was no capsule at all. The brain cortex showed scattered petechial hemorrhages. Postoperatively, the patient recovered neurologically and hematologically. The bone marrow failure was felt to be secondary to a previous viral infection because of the coincidence of recovery with dexamethasone treatment. Three weeks after surgery she was discharged. Unfortunately, she was lost to follow-up.

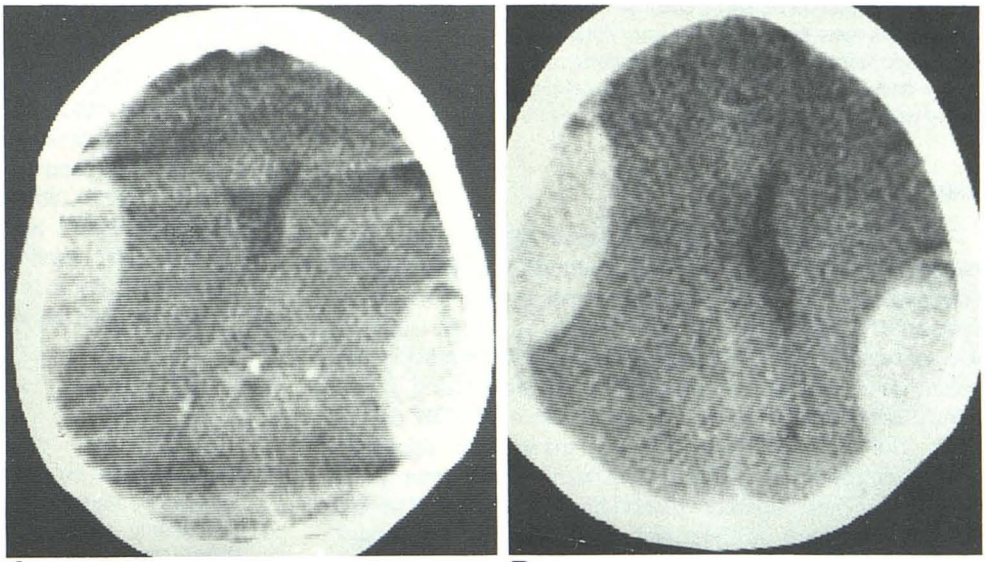

Fig. 1.—Case 1. Nonenhanced CT scans. *A* and *B*, Bilateral biconvex acute subdural hematomas without significant anterior and posterior extension. Note small hypodense region in superior part of hematoma with fluid level.

Received November 28, 1984; accepted after revision April 8, 1985.
[1] Department of Diagnostic Radiology, Technion School of Medicine, Rambam Medical Center, Haifa, Israel. Address reprint requests to J. Braun.
[2] Department of Neurosurgery, Technion School of Medicine, Rambam Medical Center, Haifa, Israel.

AJNR **8:171–173, January/February 1987** 0195–6108/87/0801-0171 © American Society of Neuroradiology

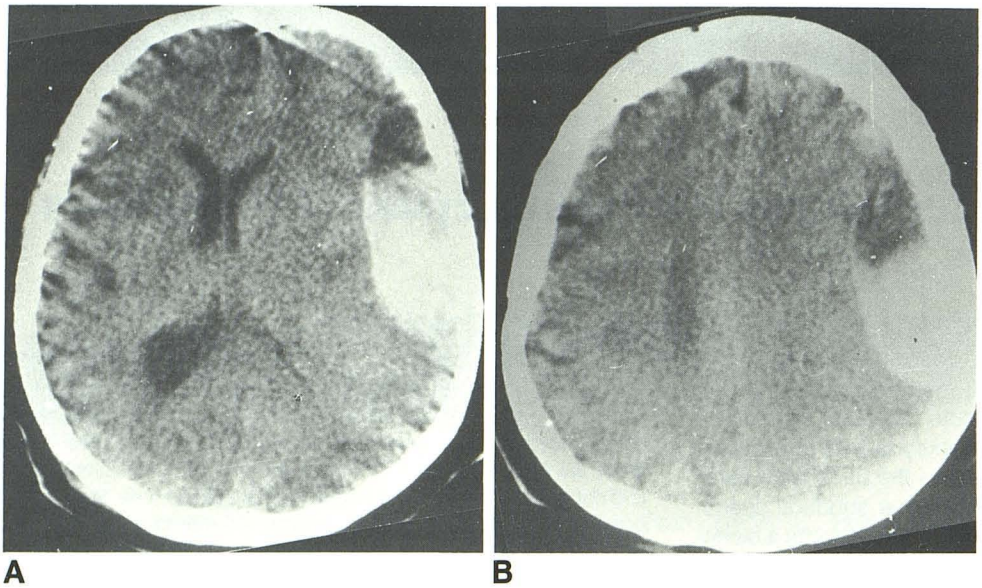

Fig. 2—Case 2. Nonenhanced CT scans. *A* and *B*, Left large biconvex acute subdural hematomas. Margin of hematoma is almost perpendicular to skull wall. Note hypodense region in superior part of hematoma with fluid level.

Case 2

A 58-year-old woman with known metastatic breast cancer and bone marrow failure fell and struck her head. On arrival she was alert, aphasic, and exhibited a right hemiplegia. Blood studies showed hemoglobin 7.9 g/dl, leukocytes 3100, platelets 36,000, and normal prothrombin and partial thromboplastin time. Skull radiographs showed only multiple osteolytic lesions. CT scan revealed a left temporoparietal extracerebral biconvex focal hematoma. A clear interface divided the hematoma into an upper hypodense zone and a lower hyperdense zone (Fig. 2). The hematoma was evacuated. It proved to be subdural, partly solid partly fluid, and with no capsule at all. There was fresh bleeding from cortical veins. Thereafter, her neurologic status improved but her general condition worsened. She died 7 days after surgery in a state of progressive irreversible respiratory and cardiac insufficiency. Autopsy was not granted.

Discussion

The characteristic CT appearance of ASDH is that of a hyperdense crescentic lesion that extends over most of the subdural space. EDH, on the other hand, is lenticular, biconvex, and much more focal in nature [1–7, 9–11]. During a 4½-year period, two female patients involved in relatively mild head trauma and exhibiting pancytopenia were found to harbor ASDHs that mimicked the appearance of EDH on CT scan. The focal biconvex bleeding showed no significant anterior or posterior extension. The round inner border of the hematomas were hyperconvex and formed an angle of almost 90° with the skull. ASDHs may sometimes have a convex internal margin but only in their central section and when the bleeding is exceedingly great [3]. As the periphery of the hematoma is approached, the margin becomes increasingly concave, regaining at the end its characteristic crescent shape. Subdural hematomas may also have a biconvex configuration in the subacute or chronic phase due to formation of membranes around the clot. The reason for the biconvex appearance in our cases is not clear and we were not able to find a similar picture in the literature. It could have resulted from blockage of the subdural space by adhesions subsequent to small previous asymptomatic bleeding secondary to the coagulopathy. This may have been associated with a loss of turgidity of the brain, due to the patients' poor general state of health, which allowed its indentation.

Another interesting aspect was the heterogeneity of the hematomas. A low-density zone was seen superiorly separated by a fluid level from an inferior hyperdense section. The operative findings discarded the possibility of rebleeding in a previously unknown homogeneous chronic subdural hematoma. This "sedimentation effect" [8] could possibly be related in the present cases to the coagulopathy; namely, blood sedimentation progressed more hastily than coagulation. This feature could perhaps be used for the differential diagnosis because it is clearly distinct from the swirl phenomenon seen in acute EDH type 1 reported by Zimmerman and Bilaniuk [12], which is the result of active bleeding. In this latter case the hypodense zone is more centrally located within the hematoma and has an irregular vortical aspect without fluid level.

REFERENCES

1. Brant-Zawadzki M, Pitts LH. The role of CT in evaluation of head trauma. In: Federle MP, Brant-Zawadzki M, eds. *Computed tomography in the evaluation of trauma.* Baltimore: Williams & Wilkins, **1982**:1–59
2. Cornell SH, Chiu LC, Christie JH. Diagnosis of extracerebral fluid collections by computed tomography. *AJR* **1978**;131:107–110
3. Forbes GS, Sheedy PF, Piepgras DG, Houser OW. Computed tomography in the evaluation of subdural hematomas. *Radiology* **1978**;126:143–148
4. French BN, Dublin AB. The value of computerized tomography in the management of 1000 consecutive head injuries. *Surg*

Neurol **1977**;7:171–183
5. Koo AH, LaRoque RL. Evaluation of head trauma by computed tomography. *Radiology* **1977**;123:345–350
6. Lipper MH, Kishore PRS, Girevendulis AK, Miller JD, Becker DP. Delayed intracranial hematoma in patients with severe head injury. *Radiology* **1979**;133:645–649
7. Merino de Villasante J, Taveras JM. Computerized tomography (CT) in acute head trauma. *AJR* **1976**;126:765–778
8. Ming-Chien Kao. Sedimentation level in chronic subdural hematoma visible on computerized tomography. *J Neurosurg* **1983**; 58:246–251
9. Paxton R, Ambrose J. The EMI scanner. A brief review of the first 650 patients. *Br J Radiol* **1974**;47:530–565
10. Peyster RG, Hoover ED. CT in head trauma. *J Trauma* **1982**;22:25–38
11. Zimmerman RA, Bilaniuk RT, Gennarelli T, Bruce D, Dolinskas C, Uzzell B. Cranial computed tomography in diagnosis and management of acute head trauma. *AJR* **1978**;131:27–34
12. Zimmerman RA, Bilaniuk RT. Computed tomographic staging of traumatic epidural bleeding. *Radiology* **1982**;144:809–812