

Are your **MRI contrast agents** cost-effective?

Learn more about generic **Gadolinium-Based Contrast Agents**.



FRESENIUS  
KABI

caring for life

# AJNR

## **Giant intracavernous carotid aneurysm after spontaneous thrombosis of a carotid cavernous sinus fistula.**

V B Graves, C M Strother, J M Weinstein and M Letellier

*AJNR Am J Neuroradiol* 1988, 9 (3) 595-597

<http://www.ajnr.org/content/9/3/595.citation>

This information is current as of May 1, 2024.

# Giant Intracavernous Carotid Aneurysm After Spontaneous Thrombosis of a Carotid Cavernous Sinus Fistula

Virgil B. Graves,<sup>1</sup> Charles M. Strother,<sup>1</sup> Joel M. Weinstein,<sup>2</sup> Marc Letellier<sup>3</sup>

## Case Report

A 40-year-old woman was admitted to a local hospital following the acute onset of severe right temporal and retroorbital headache associated with nausea and vomiting. For 2 or 3 days before the onset of symptoms she had experienced a flulike illness with repeated episodes of coughing. She also had a mild temperature elevation. Her past medical history was unremarkable.

At the time of initial examination she was alert and complained of severe headache. There was slight restriction of her neck movements and she complained of a noise in her right ear. On examination a bruit was heard over the right temporal area. No visual signs or symptoms were present, and there were no focal neurologic abnormalities. She was admitted to the hospital with an initial diagnosis of subarachnoid hemorrhage resulting from rupture of an intracranial aneurysm. Angiography done the same day revealed a high-flow right internal carotid artery to cavernous sinus fistula (Fig. 1).

During the next 24 hr the patient developed striking proptosis, chemosis, and loss of vision in the right eye. She was transferred to the University of Wisconsin Center for Health Sciences for balloon occlusion of her carotid cavernous sinus fistula.

Upon arrival she was restless and complained of severe right orbital pain. Her blood pressure was 130/90 and her temperature was 37.7°C. Examination revealed severe proptosis, chemosis, and conjunctival erythema of the right eye, which had no light perception. Visual acuity was 20/20 in the left eye. Extraocular motility of the right eye was severely restricted in all directions. Ocular motility was normal on the left. The intraocular pressure was greater than 60 mm Hg O.D. and 8 mm Hg O.S. No bruit could be heard either over the right orbit or over the right temporal area. Repeat angiography revealed a slow flow carotid cavernous sinus fistula with evidence of thrombus within the cavernous sinus and superior ophthalmic vein (Fig. 2). Dilatation and abnormally slow flow in the inferior and posterior draining veins from the cavernous sinus was also noted. Attempts to enter the cavernous sinus with a detachable balloon catheter failed. Because of the evidence of spontaneous thrombosis and the fact that the right eye was judged to have irreversible visual loss, a trapping procedure was not performed.

Over the next 48 hr the patient continued to complain of severe right orbital pain. She developed partial palsies of the 7th, 11th, and 12th cranial nerves. With only symptomatic treatment these symptoms as well as the proptosis and chemosis resolved, and on the 10th day after admission she was discharged. At this time she was without pain and showed complete retinal infarction.

Eight months after the onset of her symptoms, she had persistent conjunctival swelling and a blind cosmetically unacceptable right eye. She was therefore admitted for enucleation and orbital reconstructive surgery. At this time her only complaint was a mild but continuous discomfort in the right retroorbital region. Examination was normal except for a phthisical right eye. An MR image showed dilatation of the right cavernous sinus with signal intensities, indicating the presence of flowing blood (Fig. 3). Because of these findings a right carotid angiogram was done. This revealed a giant aneurysm of the cavernous segment of the right internal carotid artery. The carotid cavernous sinus fistula was obliterated (Fig. 4).

Occlusion of the cavernous segment of the right internal carotid artery was done with two detachable balloons. This was well tolerated, and over the next day the right orbital discomfort disappeared. A follow-up MR scan done the day after the carotid occlusion showed evidence of thrombosis of the giant aneurysm (Fig. 5). These findings were confirmed by contrast-enhanced CT.

## Discussion

Carotid artery cavernous fistulae, abnormal communications between either the internal or external carotid artery and the cavernous sinus, have been recognized since 1809 [1]. Although a variety of classifications have been used in discussing these lesions, it is our opinion that they should be grouped into two categories: (1) those between meningeal branches of either the internal or external carotid artery and the cavernous sinus—that is, "dural" fistulae, and (2) those between the internal carotid artery itself and the cavernous sinus—that is, "direct" fistulae. This classification provides the best means for describing them [2–6].

Dural fistulae usually arise spontaneously, are due to a preexisting arteriovenous fistula or malformation, are most often low-flow lesions, and commonly undergo spontaneous closure [2, 7]. These will not be discussed further in this report.

Direct fistulae are high-flow lesions that generally result from trauma that causes a tear in the cavernous segment of the internal carotid artery. These high-flow lesions usually produce striking ocular signs and symptoms and rarely close spontaneously [3, 8]. Although uncommon, direct fistulae

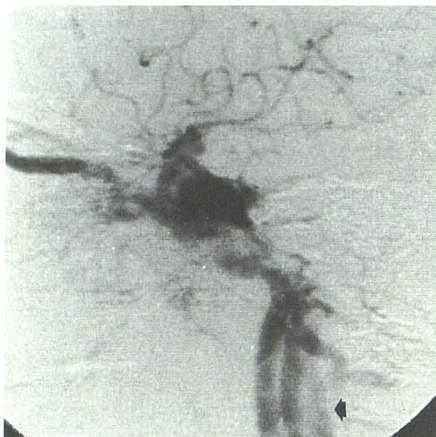
Received April 29, 1986; accepted after revision July 9, 1986.

<sup>1</sup> Department of Radiology, University of Wisconsin Health Science Center, 600 Highland Ave., Madison, WI 53792. Address reprint requests to C. M. Strother.

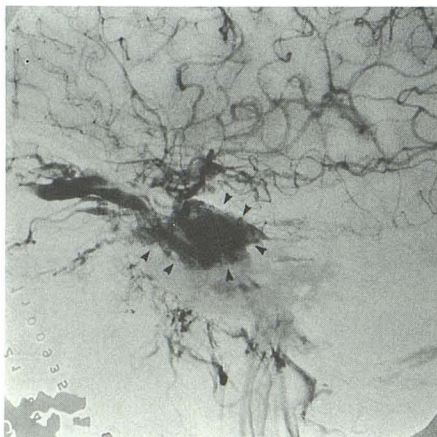
<sup>2</sup> Department of Ophthalmology, University of Wisconsin Health Science Center, Madison, WI 53792.

<sup>3</sup> Mercy Medical Center, 631 Hazel St., Oshkosh, WI 54901.





1



2

Fig. 1.—Initial digital subtraction right carotid angiogram demonstrates carotid cavernous sinus fistula with anterior drainage into ophthalmic vein and rapid shunting with opacification of jugular vein (*arrow*) during early arterial phase.

Fig. 2.—Follow-up right carotid angiogram demonstrates carotid cavernous fistula but with decreased flow, better filling of internal carotid artery circulation, and stasis of contrast medium within cavernous sinus (*arrowheads*).

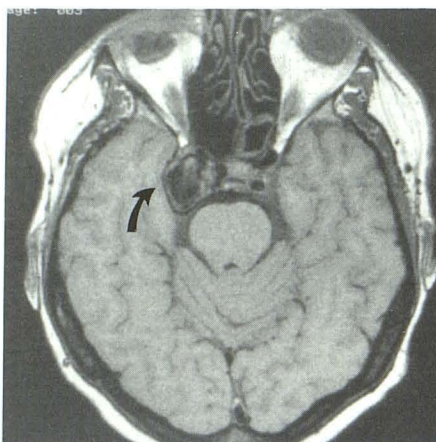


Fig. 3.—Axial MR image, 600/30, at level of cavernous sinus shows dilatation of right cavernous sinus and large area of decreased signal suggestive of flowing blood (*arrow*). Left internal carotid artery is well shown.

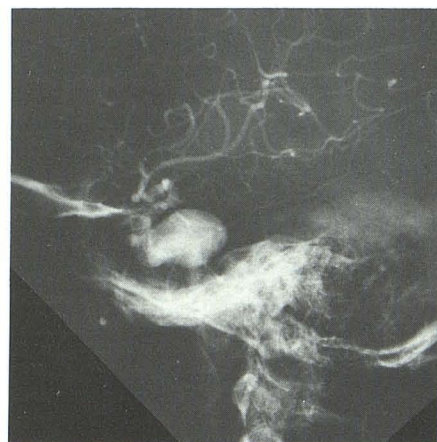


Fig. 4.—Lateral view of right carotid angiogram demonstrates giant aneurysm arising from intracavernous portion of right internal carotid artery.

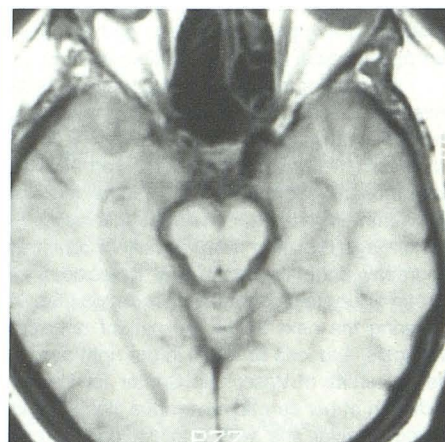


Fig. 5.—Axial MR image, 600/30, at level of cavernous sinus after occlusion of right internal carotid artery. Area of decreased signal shown in Fig. 3 now has increased signal consistent with thrombosis within giant aneurysm.

have also been reported to occur as a result of rupture of an intracavernous aneurysm or in association with osteogenesis imperfecta in the absence of trauma [9, 10].

The case reported here is to our knowledge unique in that it represents the spontaneous occurrence and closure of a direct fistula, leaving as a sequela a residual giant intracavernous carotid aneurysm. Giant intracavernous carotid aneurysms associated with carotid cavernous sinus fistulae caused by either trauma or the delayed effects of interventional treatment have been previously described; otherwise this association has not been noted [3, 4, 11–13]. The clinical presentation of our patient suggests that her fistula, shown at the time of initial angiography to be a typical high-flow lesion, resulted from the rupture of an intracavernous carotid aneurysm. Her sudden loss of vision and striking proptosis, chemosis, and conjunctival erythema were due to spontaneous thrombosis with obstruction of the venous drainage of

both the orbit and cavernous sinus, thereby producing intraocular pressures that caused irreversible ischemic damage to the globe. Over the following 8 months, the globe became atrophic. Except for this she was left without clinical evidence of a vascular abnormality. Only because of a disparity between this clinical picture and findings of an MR examination, which showed evidence of persistent dilatation and flowing blood in the cavernous sinus, was repeat angiography performed.

From the evidence available to us it is impossible to determine whether the giant aneurysm, which followed closure of this high-flow carotid cavernous sinus fistula, represented a true aneurysm (i.e., a dilatation involving all three layers of the vessel wall), a false aneurysm (i.e., a rupture involving all three layers of the vessel wall), or a mixed aneurysm (i.e., a rupture involving only the intima and media of the vessel wall) [14]. Regardless of its type, it was clinically occult. If MR had not

been done the aneurysm would have gone undetected, thereby placing the patient at risk for rupture or embolic complications. It is our recommendation that in instances of spontaneous closure of carotid cavernous fistulae, follow-up imaging should be performed to detect this uncommon but important complication.

#### REFERENCES

1. Travers B. A case of aneurysm by anastomosis in the orbit, cured by the ligation of the common carotid artery. *Med-Chir Tr* **1811**;2:1-16
2. Peters FL, Kroger R. Dural and direct cavernous sinus fistulae. *AJR* **1979**;132:599-606
3. Debrun G, Lacour P, Vinuela F, et al. Treatment of 54 traumatic carotid cavernous fistulas. *J Neurosurg* **1981**;55:678-692
4. Tsai FY, Hieshima GB, Mehringer CM, Grinnell U, Pribram HW. Delayed effects in treatment of carotid-cavernous fistulas. *AJNR* **1983**;4:357-361
5. Mullan S. Treatment of carotid-cavernous fistulas by cavernous sinus occlusion. *J Neurosurg* **1979**;50:131-144
6. Barrow DL, Spector RH, Braun IF, Lauduran J, Tindall GT. Classification and treatment of spontaneous carotid-cavernous sinus fistulae. *J Neurosurg* **1985**;62:248-256
7. Newton TH, Hoyt WF. Dural arteriovenous shunts in the region of the cavernous sinus. *Neuroradiology* **1970**;1:71-81
8. Seeger JR, Gabrielsen TO, Giannotta SL, Lotz PR. Carotid-cavernous sinus fistulas and venous thrombosis. *AJNR* **1980**;1:141-148
9. DeCampos FM, Lopez Ferro MO, Burzaco JA, et al. Spontaneous carotid cavernous fistula in osteogenesis imperfecta. Case report. *J Neurosurg* **1982**;56:590-593
10. Gerger MS, Hosobuchi Y. Cavernous sinus fistula caused by intracavernous rupture of a primitive trigeminal artery. Case report. *J Neurosurg* **1984**;61:391-395
11. Vinuela F, Fox AS, Debrun GM, Peerless SJ, Drake CG. Spontaneous carotid-cavernous fistulas: clinical radiological and therapeutic considerations. *J Neurosurg* **1984**;60:976-984
12. Lesoin F, Rousseau M, Petit H, Jomin M. Spontaneous arterial aneurysm into a carotid-cavernous fistula. Case report. *Acta Neurochir (Wien)* **1984**;70:53-58
13. Reddy SVR, Sundt TM. Giant traumatic false aneurysm of the internal carotid artery associated with a carotid-cavernous fistula. *J Neurosurg* **1981**;55:813-818
14. Marx M, Gardiner GA, Miller RH III. The truth about false aneurysms. *AJR* **1985**;145:193-194