

# A Teaching and Research Simulator for Therapeutic Embolization

C. W. Kerber<sup>1</sup>  
L. W. Flaherty<sup>1</sup>

A teaching machine that simulates intravascular conditions found during a human therapeutic embolization has been constructed. A submersible pump drives fluid through a circuit of tubing. One limb of a Y (a vascular bifurcation) located in this circuit leads to a model arteriovenous malformation. Catheters placed in this limb may introduce embolic materials by various techniques, and those techniques may be learned and practiced under safe and stress-free conditions. Loss of an embolus into the other limb which supposedly leads to normal tissues is caught and displayed by a sieve, providing immediate feedback that a technique error has occurred.

Therapeutic embolization, the deliberate embolic occlusion of the blood supply of arteriovenous malformations and other hypervascular abnormalities, is gaining wider acceptance [1-10]. However, these procedures have risk, and complications may occur when emboli introduced into pedicles feeding vascular abnormalities reflux back along the catheter and pass into vessels supplying normal tissue [11-12]. Such an error often results in an ischemic infarct, a complication disabling to the patient and distressing to the radiologist. Because these techniques should be learned under easier, safer conditions than the angiography table, we have built a therapeutic embolization teaching machine.

## Materials and Methods

To be lifelike, our analog simulator required a vessellike circuit with fluid flowing under some pressure. A catheter entry point was also required. An essential component was a vascular bifurcation (Tygon Y Connector, Fisher Scientific Co., Pittsburgh, Pa.), one limb leading to an arteriovenous malformation model (the AVM limb) and another limb supposedly leading to normal tissues (the "brain" limb) (fig. 1A). Finally, some failure indicator was needed downstream in the brain limb to show when a technique error occurred.

During a therapeutic embolization, the acceptance rate of the artery feeding the abnormality decreases and finally reaches zero as embolic material progressively occludes its vascular bed. This change was reproduced in the model by placing a disposable small blood filter (Fenwal Laboratories, Deerfield, Ill.) downstream in the arteriovenous malformation limb. As emboli are introduced, the filter becomes increasingly plugged until flow stops completely.

If more emboli are introduced past this point, they may reflux into the brain limb. A sieve (1 mm Testing Sieve, Fisher Scientific Co., Pittsburgh, Pa.) was placed downstream to catch lost emboli and provide immediate feedback when a technique error occurred (fig. 1B).

A catheter was placed into the circuit through another Y adapter located proximally. One

Received August 14, 1979; accepted after revision October 16, 1979.

Presented at the annual meeting of the American Society of Neuroradiology, Toronto, May 1979.

This work was supported in part by a grant from the W. I. Patterson Charitable Fund, Pittsburgh, PA 15222.

<sup>1</sup> Department of Radiology, Division of Neuroradiology, Presbyterian-University Hospital, DeSoto at O'Hara St., Pittsburgh, PA 15215. Address reprint requests to C. W. Kerber.

*AJNR* 1:167-169, March/April 1980  
0195-6108/80/0102-0167 \$00.00  
© American Roentgen Ray Society

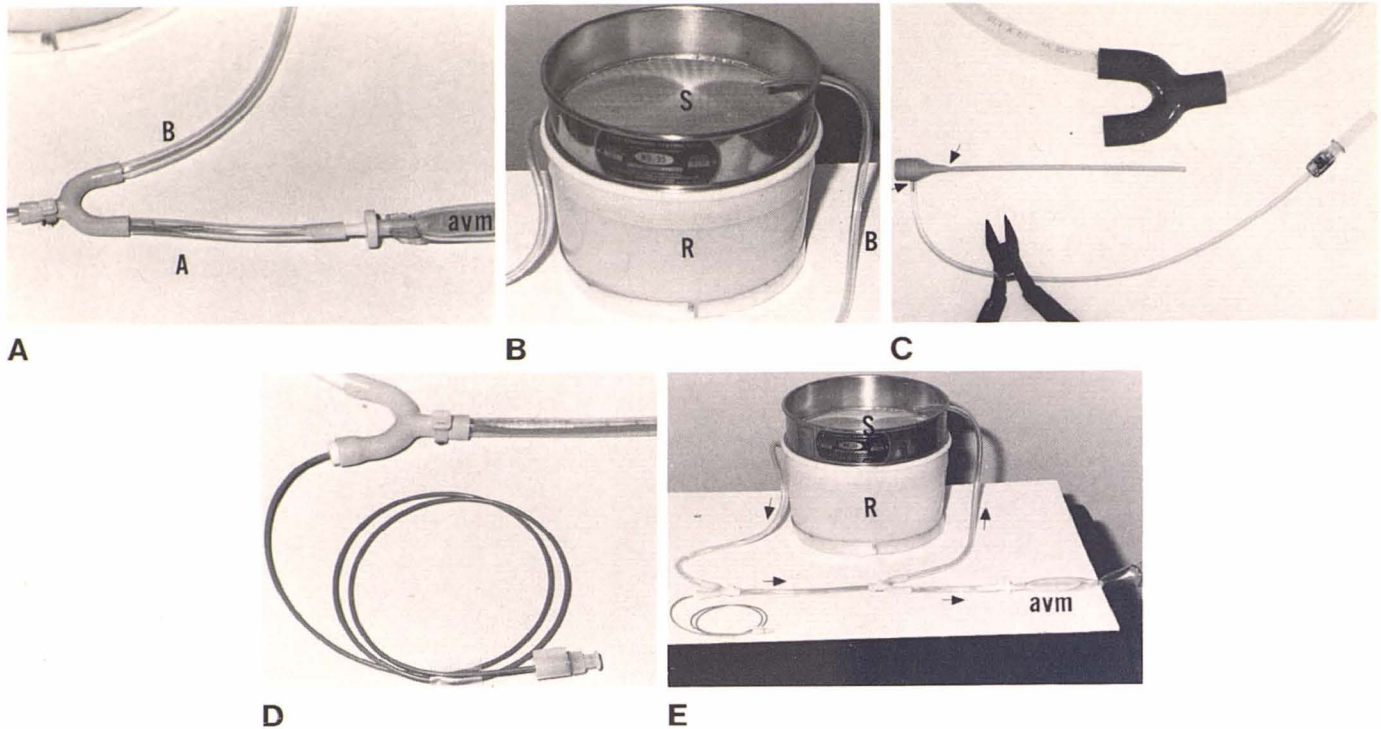


Fig. 1.—A, Fundamental elements of therapeutic embolization simulator. At model vascular bifurcation, lower arterial limb (A) leads to ersatz abnormal capillary bed (arteriovenous malformation) with disposable small blood filter as bed. "Venous" end of malformation is directed into waste receptacle, so reservoir fluid is not contaminated by small particles or dye indicator. Catheter is in arterial limb. When particles or polymer block simulated capillary bed, blood flow in arterial limb slows. This is visible through clear tubing, or under fluoroscopy if emboli are suspended in contrast agent or are sufficiently radiopaque. Inappropriate introduction of embolus will cause reflux along

catheter into upper limb (B, brain) leading to downstream failure indicator. B, Sieve (S) downstream catches particles that have refluxed into limb B. C, Leak-proof entry into system achieved with gasket part of Cordis arteriotomy sheath in Y adapter. Perfusion side arm and Teflon sleeve are removed (arrows) with wire cutter. D, With gasket in place, embolization catheter may be placed in system. E, Overview of simulator. Reservoir (R) contains submersible pump. Sieve (S) covers reservoir. Fluid flow (arrows). AVM-blood filter.

limb of the Y held the gasket part of a 6 French arteriotomy sheath (Cordis Co., Miami, Fla.) from which the side arm and Teflon sleeve were removed (fig. 1C). With this gasket in place, catheters could be introduced and manipulated without fluid leakage (fig. 1D).

The circuit was made of clear polyvinyl chloride tubing (Tygon Tubing, Fisher Scientific Co., Pittsburgh, PA 15219). Fluid flow under pressure was provided by a simple submersible pump such as an aquarium pump placed into a fluid reservoir. The sieve was conveniently placed over this reservoir. The completed model is shown in figure 1E.

## Results and Discussion

The value and effectiveness of teaching machines (analog simulators) have long been appreciated by the airline industry and military services, but perhaps because of the long history of bedside teaching, simulators have never been well accepted in medicine. However, they are of value when complex tasks must be learned which are dangerous either to operator or subject, or the cost of failure is high.

We have found this simple device reproduces the conditions during a human therapeutic embolization. One may become proficient first in manipulating the many stop cocks and tubings used to keep the embolization system free of clot. Most catheters and emboli used in patients may be

used and the necessary feel for their effective delivery appreciated. An embolus not effective with the device is silicone beads which do not plug the "blood" filter. When emboli are introduced with direct vision control, loss of an embolus and its appearance on the "brain" sieve gives the operator feedback which is direct, immediate, and creates a profound and lasting impression. After direct visualization techniques are learned, the device may be placed under a fluoroscope for the next increment of learning.

We have found the simulator of value for research also. Replacing the water with blood has allowed us to see tissue adhesive deposition in flowing blood and to assess the effects of varied delivery rates, techniques, and modified polymerization times.

## ACKNOWLEDGMENTS

We thank Gretchen Fischer for manuscript preparation and Norman Rabinovitz and Joseph Winstein for photographic assistance.

## REFERENCES

1. Djindjian R, Cophignon J, Rey A, Theron J, Merland JJ, Houdart R. Superselective arteriographic embolization by the fem-

- oral route in neuroradiology. *Neuroradiology* **1973**;6:143-152
2. Serbinenko AF. Balloon catheterization and occlusion of major cerebral vessels. *J Neurosurg* **1974**;41:125-145
  3. Debrun G, Lacour P, Caron JP, et al. Traitement de fistules arterioveineuses et d'aneurysmes par ballon gonfable et largable. *Nouv Presse Med* **1975**;4:2315-2318
  4. Kerber CW, Bank WO, Cromwell LD. Calibrated leak microcatheter: a device for arterial exploration and occlusive therapy. *AJR* **1979**;132:207-212
  5. Luessenhop AJ, Kachmann R, Shevlin W, Ferrero AA. Clinical evaluation of artificial embolization in the management of large cerebral arteriovenous malformations. *J Neurosurg* **1965**;23:400-417
  6. Boulous R, Kricheff II, Chase NE. Value of cerebral angiography in the embolization treatment of cerebral arteriovenous malformation. *Radiology* **1970**;97:65-70
  7. Newton TH, Adams JE. Angiographic demonstration and non-surgical embolization of spinal cord angioma. *Radiology* **1968**;91:873-876
  8. Hilal SK, Michelsen JW. Therapeutic percutaneous embolization for extraaxial vascular lesions of the head, neck, and spine. *J Neurosurg* **1975**;43:275-287
  9. Rösch J, Dotter CT, Brown MJ. Selective arterial embolization. A new method for control of acute gastrointestinal bleeding. *Radiology* **1972**;102:303-306
  10. Goldman ML, Land WC, Bradley EL, Anderson J. Transcatheter therapeutic embolization in the management of massive upper gastrointestinal bleeding. *Radiology* **1976**;120:513-521
  11. Woodside J, Schwarz H, Bergreen P. Peripheral embolization complicating bilateral renal infarction with Gelfoam. *AJR* **1976**;126:1033-1034
  12. Gang DL, Dole KB, Adelman LS. Spinal cord infarction following therapeutic renal artery embolization. *JAMA* **1977**;237:2841-2842