

Are your **MRI contrast agents** cost-effective?

Learn more about generic **Gadolinium-Based Contrast Agents**.



FRESENIUS
KABI

caring for life

AJNR

Radiologic Features of Septo-optic Dysplasia: de Morsier Syndrome

John Anthony O'Dwyer, Thomas H. Newton and William F. Hoyt

AJNR Am J Neuroradiol 1980, 1 (5) 443-447

<http://www.ajnr.org/content/1/5/443>

This information is current as
of May 21, 2024.

Radiologic Features of Septo-optic Dysplasia: de Morsier Syndrome

John Anthony O'Dwyer¹
 Thomas H. Newton²
 William F. Hoyt³

The clinical and neuroradiologic features in 22 patients with septo-optic dysplasia are reviewed. The most consistent abnormality seen in 15 patients was absence of the septum pellucidum and flattening of the roofs and inferior pointing of the floors of the anterior horns of the lateral ventricles. Hypoplasia of the anterior optic pathways was seen in 10 patients and a primitive optic ventricle was seen in two others. All patients had clinical optic disc hypoplasia; 12 patients had pituitary hormonal deficiencies. In most instances the diagnosis of septo-optic dysplasia can be established by physical examination but neuroradiologic study is required to document associated structural abnormalities.

In 1956, de Morsier [1] coined the term septo-optic dysplasia to describe the brain of an adult in whom hypoplasia of the optic discs was associated with agenesis of the septum pellucidum. This midline malformation of the brain includes dysplasia of the anterior third ventricle, persistence of the optic ventricle, agenesis of the septum pellucidum, and agenesis or hypoplasia of the anterior optic pathway and hypothalamus. Occasionally the chiasmatal commissure is absent. Growth retardation as well as other endocrine abnormalities are frequent associated conditions [2-9]. We review features of this syndrome which have received little attention in the radiologic literature [8, 10-13].

Materials and Methods

The records of 22 patients with septo-optic dysplasia were reviewed. The syndrome was considered present only in those patients who had both optic nerve hypoplasia and either pituitary/hypothalamic dysfunction or a structural midline brain abnormality. Patients with optic nerve hypoplasia alone were excluded. Neuroradiologic studies, performed in 19 of the 22 patients, were analyzed.

Observations

Ages of the 22 patients at presentation ranged from birth to 20 years. Most (11 cases) were seen between birth and 6 months of age. Of the remainder, two were seen between 6 and 12 months; three at ages 1-3 years; four at ages 3-10 years, and two at 10-20 years of age. Eight patients had pituitary hormone deficiency; 11, visual problems (nystagmus, blindness, esotropia, and poor vision); and three, congenital hemiparesis. Twelve patients had hormonal deficits: five, human growth hormone deficiencies; two, human growth, adrenocorticotrophic, and thyroid-stimulating hormone deficiencies; and five, anterior pituitary

Received January 14, 1980; accepted after revision March 6, 1980.

¹ Consultant Neuroradiologist, St. Laurence's Hospital, Dublin, Ireland, and Department of Radiology, University of California, School of Medicine, San Francisco, CA 94143.

² Department of Radiology, Room M-396, University of California, School of Medicine, San Francisco, CA 94143. Address reprint requests to T. H. Newton.

³ Section of Neuro-ophthalmology, University of California, School of Medicine, San Francisco, CA 94143.

AJNR 1:443-447, September/October 1980
 0195-6108/80/0104-0443 \$00.00
 © American Roentgen Ray Society

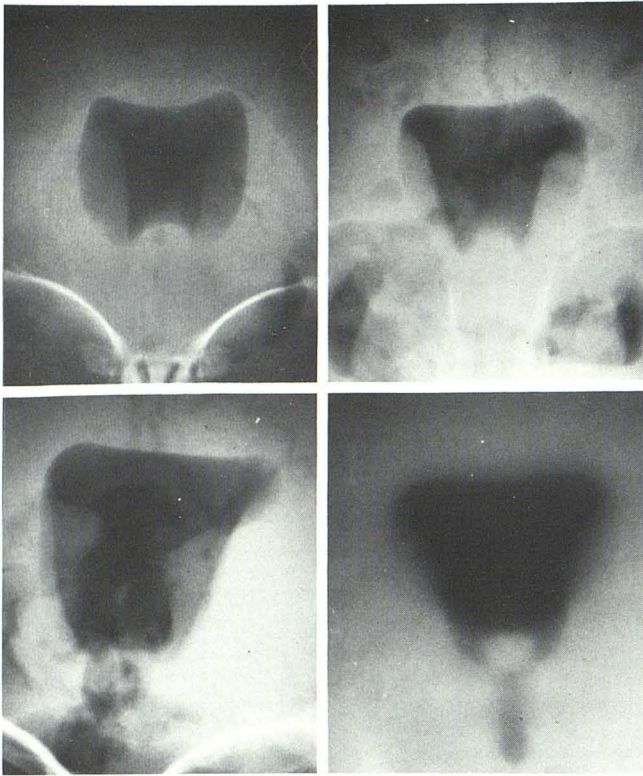


Fig. 1.—Frontal projection, brow-up pneumoencephalograms in four patients. Septum pellucidum absent; roof of lateral ventricle flattened; floor of anterior horns of lateral ventricle pointed.

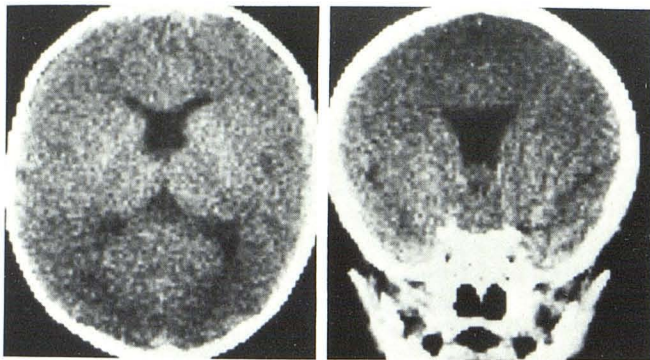


Fig. 2.—Axial (A) and coronal (B) CT scans. Roofs of anterior horns of lateral ventricle are flattened; septum pellucidum absent.

hormone deficiency and diabetes insipidus.

Neuroradiologic studies were performed in 19 patients: pneumoencephalography in 16 and computed tomography (CT) in four (one had both studies). Absence of the septum pellucidum with inferior pointing of the anteroinferior margins of the frontal horns and flattening of the roofs of the frontal horns was found in 15 of 19 cases (figs. 1 and 2). In four the septum pellucidum was present and the configuration of the lateral ventricles was normal. Mild bilateral ventricular enlargement was observed in five patients. Asymmetrical unilateral ventricular enlargement was noted in four cases, three of whom had contralateral hemiparesis (fig. 3).

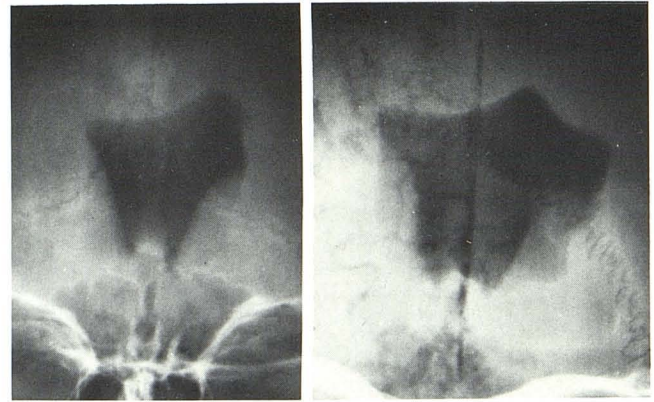


Fig. 3.—Two patients with congenital hemiplegia. Brow-up pneumoencephalograms, frontal projections. Unilateral ventricular dilatation, absence of septum pellucidum, and inferior pointing of floor.

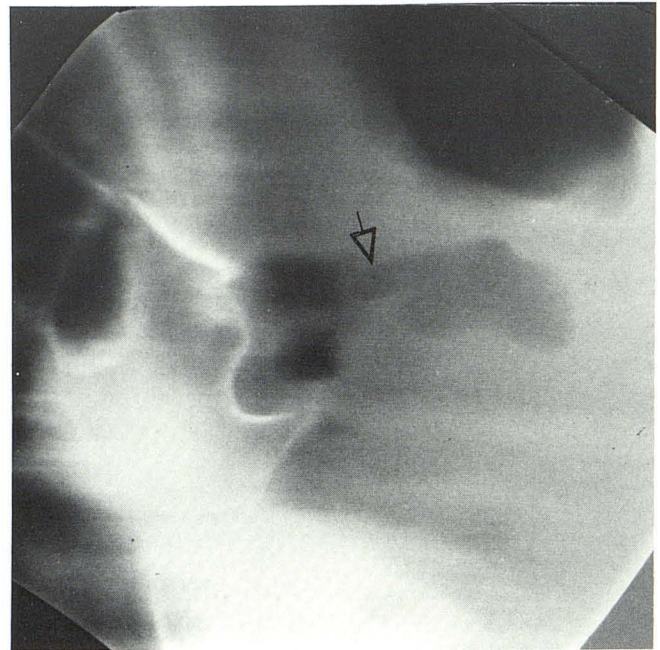


Fig. 4.—Brow-up pneumoencephalogram, lateral projection. Primitive optic ventricle (arrow).

The optic recess of the third ventricle appeared unusually prominent in eight cases and in two it resembled a primitive optic ventricle (fig. 4). The massa intermedia, as seen at pneumoencephalography in 16 patients, was large in two, average size in nine, unusually small in two, and absent in three. No accessory commissures could be identified. A small optic chiasm and proximal optic nerve could be identified in 10 of the 16 patients who underwent pneumoencephalography (fig. 5).

In the four cases on whom CT was performed, the septum pellucidum was absent in three. In one of these, agenesis of the corpus callosum was also noted. The fourth patient

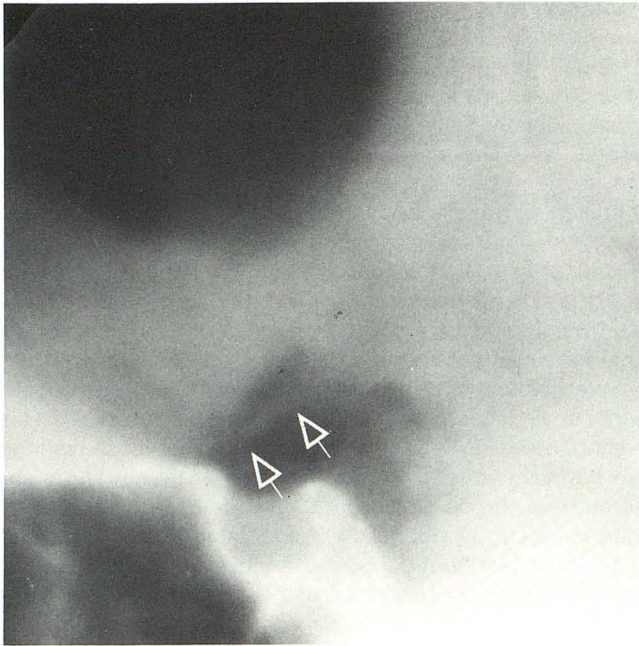


Fig. 5.—Brow-up pneumoencephalogram, lateral projection. Small optic chiasm (arrows).

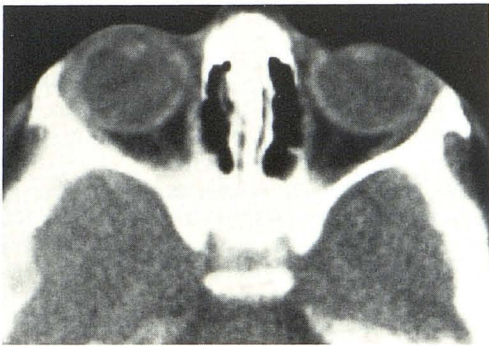


Fig. 6.—Axial orbital CT scan. Unusually small optic nerves.

showed a mild hemicerebral atrophy. The optic chiasm and orbital parts of the optic nerves appeared to be smaller than normal in two patients (fig. 6).

Radiographs of the optic canals in nine patients showed canals of normal size in four patients, bilaterally small in three, and unilaterally small in two. In the two patients with unilaterally small canals, these corresponded to clinical unilateral optic disc hypoplasia (fig. 7). The sella was normal in all patients.

Discussion

The spectrum of disorders that comprise the syndrome of septo-optic dysplasia includes patients with optic nerve hypoplasia in combination with pituitary/hypothalamic dys-

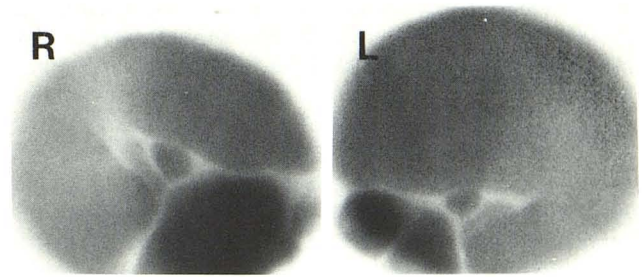


Fig. 7.—Optic canal views of patient with hypoplasia of left optic disc. Left optic canal is relatively small.

function and/or midline cerebral structural anomaly. Septo-optic dysplasia is a developmental disorder considered a mild form of holoprosencephaly in which the prosencephalic ventricle fails to expand normally into two telencephalic ventricles [3]. This maldevelopment results in a single, anterior midline ventricle with various degrees of hemispheric division.

The septum pellucidum and forebrain commissures normally develop from the lamina reuniens. The lamina reuniens in turn develops as a mesodermal thickening on the dorsal aspect of the anterior wall of the neural tube at about 6 weeks gestation. The septum pellucidum, which first appears at 18 weeks gestation, depends on the normal development of the lamina reuniens and other complex preceding events [3].

Histologic studies on the retina of these patients reveal absence of ganglion cells which normally differentiate at about 6 weeks gestation. The other layers of the retina are normal. Presumed mechanical, genetic, or environmental factors affect the normal development of the ganglion cells and the lamina reuniens in patients with septo-optic dysplasia. This abnormal development causes hypoplasia of the optic nerves and varying degrees of abnormality of the septum pellucidum and corpus callosum.

Harelip, cleft palate, anophthalmia, and absence of olfactory bulbs and tracts may be associated defects. Patel et al. [7] described a patient with septo-optic dysplasia who had hypoglycemia and bilateral optic nerve hypoplasia in the neonatal period. At autopsy, a grossly malformed microcystic brain with absence of the olfactory bulbs and tracts and partial agenesis of the corpus callosum was found. A thin septum pellucidum was present. The optic nerves and chiasm were severely atrophic. The anterior hypothalamus was distorted with small clusters of primitive cells and foci of heterotopic gray matter.

Colobomas of the optic discs and irides and hypoplasia of the optic nerves and chiasm may occasionally occur in both holoprosencephaly and septo-optic dysplasia [14–16]. Most cases of septo-optic dysplasia are sporadic and non-familial and no specific etiologic factors have been identified. Anticonvulsant drugs [17] or quinine ingestion during pregnancy [18] as well as severe maternal diabetes [19] have been implicated as causes of bilateral optic nerve hypoplasia.

The finding of pituitary hypothalamic dysfunction is prob-

ably a manifestation of a midline defect which involves the anterior hypothalamus [9, 20]. In an autopsy report, the histologic findings in the anterior hypothalamus confirmed this theory [7]. In our series, 12 of 22 patients had hormonal deficiency. Human growth hormone (HGH) alone was deficient in five of our patients, HGH in combination with adrenocorticotrophic hormone and thyroid stimulating hormone was deficient in two patients, and five patients had combinations of anterior pituitary hormonal deficiency and diabetes insipidus. Pituitary/hypothalamic dysfunction led to initial presentation of eight patients. The dysfunction was manifested by growth retardation and diabetes insipidus in three cases each, and neonatal hypoglycemia in two patients who were later shown to have HGH deficiency.

Multiple pituitary hormonal deficits have been reported in about 50% of patients with septooptic dysplasia and lack of HGH reserve was noted in more than 60% [7]. The clinical presentation of neonatal hypoglycemia in two of our patients is of interest. This finding has been previously noted and is probably due to lack of HGH and its antagonistic effect upon insulin [7]. A patient with septooptic dysplasia and sexual precocity was reported by Huseman et al. [20] who suggested that when the midline defect extends into the posterior hypothalamus and region of the mamillary bodies, sexual precocity may result.

Visual impairment due to optic nerve hypoplasia was the initial presenting manifestation in 11 patients. Optic nerve hypoplasia is frequently manifested as roving eye movements with rotating or pendular nystagmus. Other important ocular features include esotropia and temporal field defects. Eight patients had severe visual impairment in the first year of life. In these cases, the parent's suspicion that the child might be blind prompted medical investigation. The other three patients with ocular abnormalities were seen because of poor vision at age 2½ years in one, esotropia at age 5 years in one patient, and nystagmus and poor visual acuity at age 20 years in the third.

Hypoplastic optic discs were found in all 22 patients, predominantly unilateral in four and bilateral in the remainder.

Hemiparesis at birth was noted in five patients. In three cases, it caused the initial medical investigation. Neuroradiologic studies in four of these patients showed dilatation of the corresponding lateral ventricle, a finding probably representing underlying atrophy (fig. 3). The etiology of the hemiparesis is obscure. The frequency with which it occurs in this syndrome suggests an associated anomaly [21, 22].

Absence of the septum pellucidum in 15 of 19 patients with characteristic flattening of the roof and pointing of the inferior margin of the frontal horns of the lateral ventricles was the most consistent neuroradiologic finding. Absence of the septum pellucidum was initially considered an integral part of the syndrome. However, it is now apparent that this finding is not a constant feature [8, 20]. A normal septum pellucidum was present in four of our cases. Enlargement of the optic recess in six patients and persistence of a primitive optic ventricle in two (fig. 4) is of interest as this is the site of major structural abnormality. Good quality brow up lateral tomograms of the anterior third ventricle are

necessary to appreciate this anomaly. Changes in the lateral and third ventricles seen in septooptic dysplasia are similar to those noted in the Chiari type II malformation. These changes include absence of the septum pellucidum, inferomedial pointing of slightly enlarged frontal horns of the lateral ventricles and an unusually large anteriorly placed massa intermedia. An accessory anterior commissure in the third ventricle described in the Chiari malformation was not identified in our patients with septooptic dysplasia.

Unusually small optic chiasms and nerves were identified in eight patients at pneumoencephalography and in two by CT. This finding indicates the presence of hypoplasia of the anterior visual pathways.

Enlargement of the chiasmatic cisterns has been described as a feature of septooptic dysplasia [7, 9]. This finding, however, is difficult to evaluate since these cisterns are normally large in infants. The significant structural abnormalities can be shown by CT but details of the anterior third ventricle cannot yet be appreciated with this method [13]. Axial and coronal scans should be obtained when assessing patients suspected of this syndrome. Plain radiographs of the optic canals obtained in nine patients were abnormal in five but did not contribute to the diagnosis. It is of interest that unilateral optic nerve hypoplasia can be associated with unilateral small optic canals.

REFERENCES

1. de Morsier G. Etudes sur les dysraphies crânioencéphaliques. III. Agénésie du septum lucidum avec malformations du tractus optique: la dysplasie septo-optique. *Schweiz Arch Neurol Neurochir Psychiatr* 1956;77:267-292
2. Hoyt WF, Kaplan JL, Grumbach MM, Glaser JS. Septooptic dysplasia and pituitary dwarfism. *Lancet* 1970;1:893-894
3. Ellenberger C, Runyan TE. Holoprosencephaly with hypoplasia of the optic nerves, dwarfism, and agenesis of the septum pellucidum. *Am J Ophthalmol* 1970;70:960-967
4. Kaplan SL, Grumbach MM, Hoyt WF. A syndrome of hypopituitary dwarfism, hypoplasia of optic nerves and malformation of prosencephalon. *Pediatr Res* 1970;4:480-481
5. Billson F, Hopkins IJ. Optic hypoplasia and hypopituitarism. *Lancet* 1972;1:905
6. Harris RJ, Haas L. Septo-optic dysplasia with growth hormone deficiency (de Morsier syndrome). *Arch Dis Child*. 1972;47:973-976
7. Patel H, Tze WJ, Crichton JM, McCormick AQ, Robinson GC, Dolman CL. Optic nerve hypoplasia with hypopituitarism. *Am J Dis Child*. 1975;2:175-180
8. Brook CGD, Sanders MD, Hoare RD. Septo-optic dysplasia. *Br Med J* 1972;3:811-813
9. Wilson PW, Easley RB, Bolander FF, Hammond CB. Evidence for a hypothalamic defect in septo-optic dysplasia. *Arch Int Med*. 1978;138:1276-1277
10. Harwood-Nash DC, Fitz CR. *Neuroradiology in infants and children*, vols 2 and 3. St. Louis: Mosby, 1976:500-501, 1030-1031
11. Newton TH, Hoyt WE, Glaser JS. Abnormal third ventricle. In: Newton TH, Potts DG, eds. *Radiology of the skull and brain*, vol 4, *Ventricles and cisterns*. St. Louis: Mosby, 1978:3481-3482
12. Byrd SE, Harwood-Nash DC, Fitz CR, Rogovitz DM. Computed

- tomography evaluation of holoprosencephaly in infants and children. *J Comput Assist Tomogr* **1977**;1:456-463
13. Manelfe C, Rochiccioli P. CT of septo-optic dysplasia. *AJR* **1979**;133:1157-1160
 14. Yakovlev PI. Pathoarchitectonic studies of cerebral malformations III. Arrhinencephalies (holotelencephalies). *J Neuropathol Exp Neurol* **1959**;18:22-55
 15. DeMyer W, Zeman W. Alobar holoprosencephaly (arrhinencephaly) with median cleft lip and palate: clinical, electroencephalographic and nosologic considerations. *Confin Neurol* **1963**;23:1-36
 16. Miller JQ, Picard EH, Alkan MK, Warner S, Gerald PS. A specific congenital brain defect (arrhinencephaly) in 13-15 trisomy. *N Engl J Med* **1963**;268:120-124
 17. Hoyt CS, Billson FA. Maternal anticonvulsants and optic nerve hypoplasia. *Br J Ophthalmol* **1978**;62:3-6
 18. McKinna AJ. Quinine induced hypoplasia of the optic nerve. *Can J Ophthalmol* **1966**;1:261-265
 19. Petersen RA, Walton DS. Optic nerve hypoplasia with good visual acuity and visual field defects. *Arch Ophthalmol* **1977**;95:254-258
 20. Huseman CA, Kelch RP, Hopwood NJ, Zipf WB. Sexual precocity in association with septo-optic dysplasia and hypothalamic hypopituitarism. *J Pediatr* **1978**;92:748-753
 21. de Morsier G. Median cranioencephalic dysraphias and olfactogenital dysplasia. *World Neurol* **1962**;3:485-504
 22. Rush JA, Bajandas FJ. Septo-optic dysplasia (de Morsier syndrome). *Am J Ophthalmol* **1978**;86:202-205