

**Are your MRI contrast agents cost-effective?**  
Learn more about generic Gadolinium-Based Contrast Agents.



**AJNR**

**MR findings in eclampsia.**

I Dierckx and B Appel

*AJNR Am J Neuroradiol* 1989, 10 (2) 445  
<http://www.ajnr.org/content/10/2/445.citation>

This information is current as  
of April 30, 2024.

## MR Findings in Eclampsia

Although several CT studies of patients with eclampsia have been published [1–7], as far as we know, the MR findings have not. Eclampsia is a syndrome of pregnancy [6] characterized by arterial hypertension and proteinuria and resulting in generalized edema and convulsions that occur in 95% of cases after the 32nd week of gestation. The exact cause is unknown.

### Case Report

A 29-year-old woman, gravida 2, para 1, in the 39th week of gestation (by dates) was admitted for labor. She had no history of arterial hypertension, renal disease, or toxemia. During this pregnancy, an increase in blood pressure had been noted three times as well as a proteinuria of 3 g/l. Two healthy female infants were delivered by cesarean. Three hours after delivery, the patient had a grand mal seizure. Systolic blood pressure was 167 mm Hg. Two hours later, she had three episodes of grand mal seizures over a period of 7 hr. Subsequently, she went into coma with signs of decerebration and a left flaccid hemiparesis without upturning toes on the left. Funduscopic examination showed bilateral peripapillary hemorrhages and papilledema.

EEG showed diffuse slow waves. A CT scan was performed (Fig. 1). An MR examination performed with T2-weighted images confirmed the CT findings.

A diagnosis of eclampsia was made on the basis of the clinical findings and on the distribution of the cerebral lesions. Symptomatic treatment resulted in a rapid neurologic recovery.

Follow-up MR on day 12 showed gradual resorption of the lesions. Only a high signal at the level of the superior colliculus, site of the right oculomotor nucleus, remained, which correlated perfectly with the remaining neurologic status.

### Discussion

The physiopathologic mechanisms of CNS dysfunction in eclampsia are poorly understood. Possibilities include arteriolar vasospasm with retention of water and sodium, excessive vasodilatation with damage to the blood-brain barrier, and cerebral hyperemia or an immunologic disturbance [6].

Abnormal CT findings in a series of 15 eclamptic patients [1–7] included edema of the white matter in 50% and hemorrhage or ischemic lesions in 30%. Normal CT findings were reported in 22 patients, even when lesions were clinically expected [3, 8], and in one patient who had angiographically proved, isolated cerebral angiitis [9].

The anatomopathologic findings [10] are similar if not identical to those described for hypertensive encephalopathy. Microscopic changes include fibrinoid necrosis of the walls of the arterioles and small arteries. Macroscopic changes, similar to the findings on CT, can be classified into three major groups: (1) diffuse cerebral edema of the vasogenic type, (2) small areas of ischemic softening or hemorrhage of different size and location, and (3) no abnormality at all [11, 12].

The discrepancy between antemortem CT findings and postmortem anatomopathologic lesions can be ascribed to a difference in prognosis: Almost all patients who die have cerebral hemorrhage or circulatory collapse; almost all patients who have brain edema, even with severe neurologic signs, recover without neurologic deficit if adequate therapy is given. In brain edema, the expected clinical evolution toward recovery is short. CT findings normalize parallel to the clinical course in 2–6 weeks.

However, some patients have had persisting neurologic deficits and normalized CT findings [4]. In these cases MR probably would have shown the remaining lesions because of its better tissue discrimination. For this reason, the follow-up of our patient was performed with MR, and a close cliniconeurologic correlation was shown.

Inge Dierckx  
Brigitte Appel  
AZ Middelheim  
Antwerp, Belgium

### REFERENCES

1. Beck DW, Menezes AH. Intracerebral hemorrhage in a patient with eclampsia. *JAMA* 1981;246:1442–1443
2. Beeson JH, Duda EE. Computer axial tomography scan demonstration of cerebral edema in eclampsia preceded by blindness. *Obstet Gynecol* 1982;60:529–532
3. Dunn R, Wesley L. Evaluation by computerized axial tomography of eclamptic women with seizures refractory to magnesium sulfate therapy. *Am J Obstet Gynecol* 1986;155:267–268
4. Gaitz JP, Ramford CR. Unusual computed tomographic scan in eclampsia. *Arch Neurol* 1982;39:66
5. Kirby JC, Jeffry JJ. Cerebral CT findings in toxemia of pregnancy. *Radiology* 1984;151:114
6. Naheedy MH, Biller J, Schiffer M. Toxemia of pregnancy: cerebral CT findings. *J Comput Assist Tomogr* 1985;9:497–501
7. Waldron RL II, Abbott DC, Vellody D. Computed tomography in preeclampsia-eclampsia syndrome. *AJNR* 1985;6:442–443
8. Sibai BM, Spinnato JA, Watson DL, Lewis JA, Anderson GD. Eclampsia: neurological findings and future outcome. *Am J Obstet Gynecol* 1985;152:184–188
9. Farine D, Andreyko J, Lykiewicz A, Simha S, Addison A. Isolated angiitis of brain in pregnancy and puerperium. *Obstet Gynecol* 1984;63:586–588
10. Rail LR, Perkin GD. Computerized tomographic appearance of hypertensive encephalopathy. *Arch Neurol* 1980;37:310–311

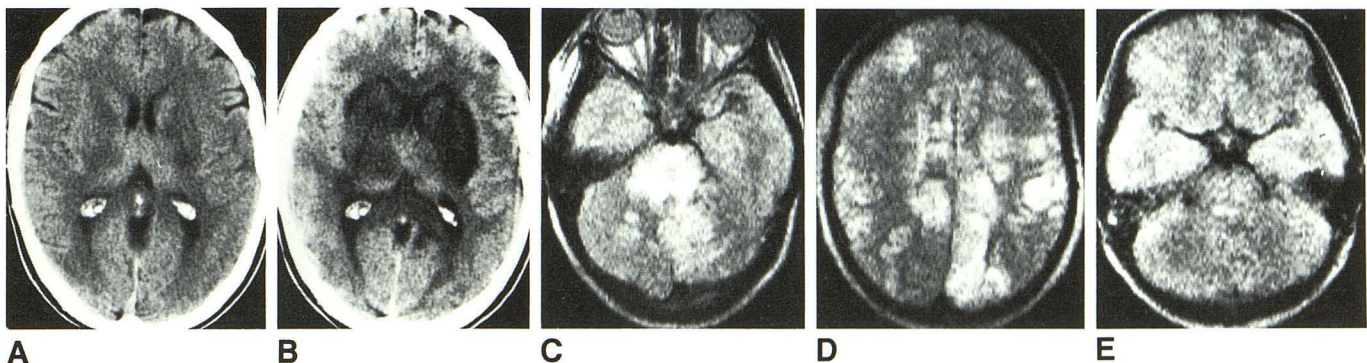


Fig. 1.—Eclampsia in a 29-year-old woman.

A, CT scan on day 1 shows hypodensities in basal ganglia and capsula externa and barely seen low densities scattered throughout white matter consistent with edema.

B, CT scan on day 2 shows more pronounced lesions.

C and D, MR images on day 2 confirm CT findings and show several areas of hemispheric and cerebellar high signal intensity.

E, T2-weighted MR image on day 12 shows remaining area of high signal intensity in right superior colliculus.