AJNR

Stereotactic third ventriculostomy: assessment of patency with MR imaging.

C R Jack, Jr and P J Kelly

AJNR Am J Neuroradiol 1989, 10 (3) 515-522
http://www.ajnr.org/content/10/3/515

Stereotactic Third Ventriculostomy: Assessment of Patency with MR Imaging

Clifford R. Jack, Jr.[1]
Patrick J. Kelly[2]

Ventricular CSF signal-intensity characteristics indicative of flowing CSF on MR images (CSF flow void) were analyzed in 20 patients who underwent a CT-based stereotactic third ventriculostomy for presumed internal obstructive hydrocephalus between October 1985 and June 1988. The status of all ventriculostomies was assessed postoperatively by radionuclide ventriculography. Postoperative MR and ventriculographic findings were correlated with the patients' subsequent clinical course. A CSF flow void in the anterior and inferior third ventricle, which seems to indicate vigorous pulsatile CSF flow through a functioning ventriculostomy, was present in all 19 patients who were clinically improved after ventriculostomy. In all 19 of these patients the radionuclide ventriculogram demonstrated normal CSF dynamics. One of the 20 patients did not improve postoperatively. The ventriculogram in this patient revealed delayed ventricular clearing and impaired CSF resorption, and the postoperative MR image did not demonstrate an anterior/inferior third ventricular CSF flow void. Eight of these patients were evaluated preoperatively by MR; one of these eight was the single nonimproved individual. None of the eight preoperative MR studies demonstrated a CSF flow void in the anterior/inferior third ventricle; however, this finding was present in seven of seven postoperative MR studies in clinically improved patients.

We conclude that the presence of a CSF flow void in the anterior/inferior third ventricle on a postoperative MR examination is sufficient to document patency of a third ventriculostomy. The absence of this finding may be due to a nonpatent ventriculostomy or perhaps an extraventricular CSF obstruction. The more invasive ventriculogram may be reserved for this situation to distinguish between these latter two possibilities.

Stereotactic third ventriculostomy is a useful therapeutic alternative to external ventricular drainage in certain patients with internal obstructive hydrocephalus [1–6]. Third ventriculostomy offers significant advantages over mechanical shunts, which are often plagued by the following problems: shunt malfunction, migration, infection, and displacement. Low-pressure syndromes can also occur. A significant morbidity accompanies multiple shunt revisions, particularly in patients with conditions that require lifetime ventricular drainage [1–6]. Freehand techniques for producing a third ventriculostomy have been used since the 1920s [1–5]. The advantage of the technique described in this report is a more precise instrument-guided placement of the leukotome with a CT-based stereotactic reference system, which should minimize the potential for damage to the hypothalamus, optic nerves, or basilar or posterior cerebral artery [1]. At our institution, this technique has become the procedure of choice for the treatment of patients who require long-term ventricular drainage. A significant portion of the stereotactic third ventriculostomies performed here are in patients with mechanical shunt failure after multiple prior revisions. Stereotactic third ventriculostomies should be performed more often as familiarity with CT- or MR-based stereotactic surgical techniques becomes more widespread in the neurosurgical community [7, 8].

We report an analysis of CSF circulatory dynamics in a group of patients who underwent CT-based stereotactic third ventriculostomies. This analysis is based

Received August 12, 1988; accepted after revision November 18, 1988.

[1] Department of Diagnostic Radiology, Mayo Clinic and Mayo Foundation, 200 First St. S.W., Rochester, MN 55905. Address reprint requests to C. R. Jack, Jr.

[2] Department of Neurologic Surgery, Mayo Clinic and Mayo Foundation, Rochester, MN 55905.

AJNR **10:515–522, May/June 1989**
0195–6108/89/1003–0515

on identifying the presence or absence of ventricular CSF flow void, which has been identified as an indicator of CSF flow on spin-echo MR images [9–16].

Materials and Methods

Patients

Twenty patients had both a CT-based stereotactic third ventriculostomy and a postoperative MR study at this institution between October 1985 and June 1988. The 11 males and nine females were 7–78 years old (mean, 25 years). The indication for third ventriculostomy in all patients was presumed internal obstructive hydrocephalus on the basis of clinical symptoms and preoperative CT scans demonstrating ventricular dilatation. Preoperative symptoms were primarily related to obstructive hydrocephalus and included headache (80%), diplopia (25%), decreased mentation (25%), nausea and vomiting (20%), and gait ataxia (15%). Causes of ventricular obstruction are listed in Table 1. Patients with aqueductal stenosis were referred for mechanical shunt failure after multiple previous shunt revisions.

TABLE 1: Correlation Between Clinical Outcome, Postoperative MR CSF Flow-Void Pattern, and Ventriculogram Studies[a]

Surgical Outcome/ Case No.	Follow-up (months)	MR Flow Void					Indication for Surgery
		Foramen of Monro	Third Ventricle	Interpeduncular/ Prepontine Cistern	Aqueduct	Fourth Ventricle	
Asymptomatic/improved							
1	24	Present	Present	Present	Not seen	Present	Pineal tumor; unknown histology
2	28	Present	Present	Present	Absent	Absent	Aqueductal stenosis with shunt infection
3	8	Absent	Present	Present	Absent	Absent	Aqueductal stenosis with shunt malfunction
4	7	Present	Present	Present	Absent	Absent	Pineal tumor; unknown histology
5	12	Absent	Present	Present	Absent	Absent	Aqueductal stenosis with shunt malfunction
6	5	Present	Present	Present	Absent	Absent	Aqueductal stenosis with shunt malfunction
7	5	Present	Present	Present	Absent	Absent	Aqueductal stenosis with shunt malfunction
8	7	Absent	Present	Present	Not seen	Absent	Pineal region germinoma
9	28	Present	Present	Present	Present	Absent	Pineal region germinoma
10	9	Absent	Present	Present	Present	Present	Benign pineal cyst
11	8	Present	Present	Present	Present	Present	Pineal region germinoma
12	11	Present	Present	Absent	Present	Present	Ependymoma, fourth ventricle
13	3	Absent	Present	Present	Not seen	Not seen	Cerebellar astrocytoma
14	1	Present	Present	Present	Absent	Absent	Pineocytoma/shunt failure
15	7	Present	Present	Present	Absent	Absent	Midbrain tumor; unknown histology
16	3	Present	Present	Present	Absent	Absent	Collicular plate astrocytoma
Total	10.4	69%	100%	94%	31%	20%	
Transient improvement postoperatively, but unchanged or worse in follow-up							
17	18	Present	Present	Present	Absent	Absent	Pineal endodermal sinus tumor
18	5	Present	Present	Present	Not seen	Not seen	Cerebellar/brainstem astrocytoma
19	17	Present	Present	Present	Not seen	Absent	Thalamic/midbrain astrocytoma
Total	13.3	100%	100%	100%	0%	0%	
No change on follow-up							
20	16	Absent	Absent	Absent	Not seen	Absent	Collicular plate mass; unknown histology
Total	16	0%	0%	0%	Not seen	0%	

Note.—"Not seen" under MR flow void means that the structure was not seen. "Total" entries provide average follow-up period and percentages of patients in whom that structure was visualized on MR with a flow void present.

[a] The ventriculogram was abnormal in case 20 only; in all other patients the ventriculogram study was normal.

Surgery

Patients underwent preoperative contrast-enhanced CT with a stereotactic head frame in place [1]. CT sections 1.5-mm thick were obtained through the foramen of Monro and the interpeduncular cistern. Two points were localized in stereotactic space: one point midway between the dorsum sellae and basilar artery in the interpeduncular cistern and the second point the foramen of Monro on the right. A computer program calculated mechanical adjustments of the stereotactic instrument* to access the target point in the interpeduncular cistern, and collar settings were adjusted to direct the instrument through the foramen of Monro on the right. Through a right frontal burr hole a ventriculoscopic cannula was passed into the right lateral ventricle. The ventriculoscope was inserted into the cannula and both were advanced through the foramen of Monro into the third ventricle. Locations of the cannula and endoscope in the midline and directed behind the dorsum sellae were confirmed with anteroposterior and lateral skull films. The endoscope was withdrawn and a leukotome was passed into the cannula through the floor of the third ventricle anterior to the mamillary bodies, creating the ventriculostomy (Fig. 1). The ventriculoscope was then reinserted to inspect the third ventricle, ventriculostomy, interpeduncular cistern, and basilar artery for evidence of hemorrhage (although none was found in any of these cases).

Radionuclide Ventriculogram

All patients underwent a postoperative radionuclide ventriculogram an average of 3 days after surgery (range, 1–10 days) to document patency of the ventriculostomy.

Technique.—Through the right frontal burr hole the right ventricle was cannulated percutaneously with an 18-gauge ventricular needle. Then, 500 μCi (18.5 Bq) ^{169}Yb-DTPA or ^{111}In-DTPA in 1.25 ml normal saline was injected. The patients were imaged with a gamma camera† at 1, 6, and 24 hr (and later if necessary) after injection of the isotope.

Evaluation.—Findings consistent with a functioning ventriculostomy and therefore "normal" CSF circulatory dynamics consist of prompt appearance of the isotope in the basal cisterns at 1 and 6 hr and emptying of the ventricles with uniform distribution of activity over the convexities at 24 hr [1, 17]. Delay in ventricular emptying or asymmetric hemispheric distribution of activity was evidence of abnormal CSF circulatory dynamics.

MR

A total of 28 pre- and postoperative MR studies were analyzed. All 20 patients had postoperative MR, while cases 1, 7, 8, 13–16, and 20 (Tables 1 and 2) also underwent a preoperative MR study. Preoperative MR studies were done an average of 3.4 days (range, 0–7 days) before surgery, while postoperative MR studies were done an average of 4 months after surgery (range, 1 day to 24 months).

The postoperative MR studies in the first nine patients were performed solely for the purpose of anatomic evaluation and therefore were examined retrospectively for ventricular CSF circulatory dynamics. Studies in the remaining 11 patients were performed specifically for the purpose of evaluating ventricular CSF flow, and therefore could be considered prospective in nature.

All studies were performed on a 1.5-T imager‡ with the following parameters: spin-echo pulse sequences 2000/20–40,70–100/2 (TR/ranges of TEs/excitations); 24-cm field of

* Stereotactic Medical Systems, New Hartford, NY.

† Siemens Orsiter, Des Plaines, IL.
‡ General Electric, Milwaukee, WI.

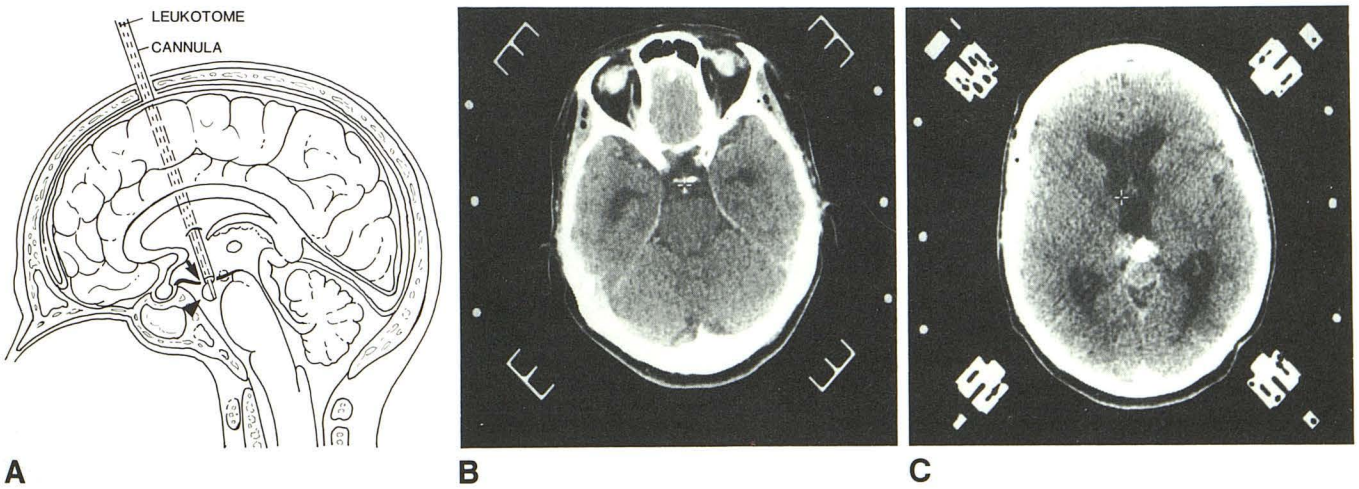

Fig. 1.—Stereotactic third ventriculostomy.
***A*, Artist's conception, lateral view. Cannula is advanced through right foramen of Monro to floor of enlarged third ventricle (*arrow*). Leukotome is then advanced through floor of third ventricle with wire loop (*arrowhead*) directed anteriorly, creating ventriculostomy.**
***B* and *C*, Axial CT sections with head frame in place. Cross hairs demarcate two target points: interpeduncular cistern (*B*) and right foramen of Monro (*C*).**

TABLE 2: Comparison of Pre- and Postoperative MR of CSF Flow-Void Patterns

Case No.	Interval		Presence of Flow Void Before/After Surgery				
	Preoperative MR to Surgery	Surgery to Postoperative MR	Foramen of Monro	Third Ventricle	Interpeduncular/ Prepontine Cistern	Aqueduct	Fourth Ventricle
1	5 days	2 months	–/Yes	No/Yes	–/Yes	–/–	No/No
7	3 days	2 weeks	No/Yes	No/Yes	No/Yes	No/No	No/No
8	Same day	1 day	No/No	No/Yes	No/Yes	–/–	No/No
13	1 day	2 days	No/No	No/Yes	No/Yes	–/–	–/–
14	7 days	6 days	No/Yes	No/Yes	No/Yes	No/No	No/No
15	1 day	1 day	No/Yes	No/Yes	No/Yes	No/No	No/No
16	5 days	1 day	No/Yes	No/Yes	No/Yes	No/No	No/No
20	7 days	4 months	No/No	No/No	No/No	No/–	No/No

Note.—A dash (–) means the structure was not visualized.

view; 128, 192, or 256 phase-encoding views; and 5-mm section thickness in a standard 30-cm head coil. Both symmetric and asymmetric second echoes were used, the former in some patients studied retrospectively and the latter in those studied prospectively. These sequences were performed in the axial plane only in 14 studies, axial and sagittal in 11, sagittal in two, and axial and coronal in one. All MR studies used for CSF flow analysis were performed without motion-compensation techniques, that is, without cardiac gating or gradient moment nulling.

Analysis.—CSF flow void is defined as signal loss in areas of flowing CSF relative to CSF in the lateral ventricles [9] and was graded as present, absent, or not evaluable at five sites: foramen of Monro, third ventricle, interpeduncular and pontine cistern, aqueduct of Sylvius, and fourth ventricle. Both the first and second echoes of the previously described spin-echo pulse sequences were evaluated and both planes were analyzed in patients imaged in two planes. Signal loss on either echo or imaging plane was considered positive evidence of CSF flow for any given site. In general, the first echo of a symmetric and the second echo of an asymmetric echo train were evaluated for CSF flow void. Even in patients studied retrospectively with symmetric second echoes, flow voids should have been visualized on the first echo.

Results

Surgery

Patency of all third ventriculostomies was confirmed during surgery by ventriculoscopy. In every case CSF flowed copiously out of the ventriculoscope cannula when the lateral ventricle was entered, indicating that the ventricular system was under pressure. No perioperative complications were encountered.

Radionuclide Ventriculogram

The ventriculogram demonstrated normal CSF circulatory dynamics in all patients except one (case 20) (Table 1). This patient had ventriculograms 2 and 10 days after surgery; both studies demonstrated activity in the basal cisterns at 6 hr, indicating ventriculostomy patency. However, 24- and 48-hr images showed marked retention of ventricular activity with nonhomogeneous and delayed ascent of activity over the convexities. These findings were interpreted as indicative of impaired CSF resorption by the arachnoid villi and arachnoiditis.

MR

Comparison of pre- and postoperative CSF flow-void patterns in cases 1, 7, 8, and 13–16 demonstrated no flow void in any of the five sites evaluated on the preoperative study (Table 2). Postoperatively, all had a flow void in the anterior/inferior third ventricle, with no flow void in the aqueduct (when visible) or fourth ventricle (Fig. 2). No flow void was present at any site on either the pre- or postoperative study in case 20.

Cases 1, 4, 19, and 20 had more than one postoperative MR study but only the first was analyzed in this study. However, no change from the first postoperative MR in the CSF flow-void patterns was noted on subsequent MR examinations.

Correlation

Patients were divided into three groups on the basis of surgical outcome: cases 1–16 were asymptomatic or improved, cases 17–19 were transiently improved in the immediate postoperative period but ultimately deteriorated during follow-up due to progression of tumor (case 17 died 18 months after surgery), and case 20 was unchanged postoperatively (Table 1). Patients are not listed chronologically, but are grouped according to surgical outcome in Table 1. Table 1 correlates surgical outcome, postoperative CSF circulation by MR, and ventriculography.

The MR findings in cases 1–8 and 13–16 suggest that the third ventriculostomy was the only site of CSF egress from the ventricular system into the subarachnoid space (Table 1). A flow void was present through the anterior/inferior third ventricle but absent in the aqueduct (when visualized) and fourth ventricle (Fig. 3). A different CSF flow pattern was present in cases 9–12 consisting of prominent anterior third ventricular flow void, with a less prominent flow void in the aqueduct (Fig. 4). In these four patients the original obstructing lesion was completely or partially removed, either surgically or by radiation therapy after the ventriculostomy had been performed. Restoration of at least some CSF flow

A B C

Fig. 2.—Case 8: Pre- and postoperative MR.

A, Axial second-echo MR image (2000/20,80/2) without motion compensation several hours before third ventriculostomy. No flow void in third ventricle (*straight arrow*). Pineal region germinoma (*curved arrow*) plus surrounding edema obstructed aqueduct.

B, Axial second-echo MR image (2000/20,80/2) without motion compensation 24 hr after third ventriculostomy shows prominent flow void in third ventricle (*arrow*).

C, Second-echo sagittal image, same study as *B*. Flow void in anterior third ventricle (*straight arrow*) through ventriculostomy (*curved arrow*) is continuous with flow void in pontine and interpeduncular cisterns. Small area of nonhomogeneous signal in pineal tumor bed is probably hemorrhage at biopsy site. By using an angulated instrument, biopsy was performed through same stereotactic trajectory after third ventriculostomy.

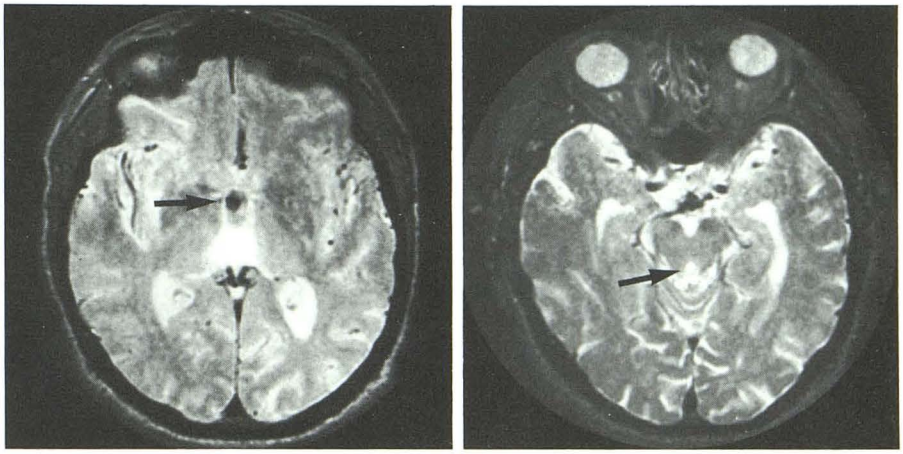

A B

Fig. 3.—Case 4: MR 3 months after third ventriculostomy in patient with pineal tumor is consistent with egress of CSF exclusively through ventriculostomy.

A, Axial second-echo image (2000/30,80/2) without motion compensation shows prominent flow void in anterior third ventricle (*arrow*).

B, Lower section, same pulse sequence. No flow void is seen in aqueduct (*arrow*).

through the aqueduct would account for the CSF flow-void pattern in these four patients.

The MR, ventriculogram, and immediate postoperative clinical course in cases 17–19 are consistent with functioning ventriculostomies. However, these patients ultimately deteriorated due to local tumor progression.

The last patient (case 20) did not improve symptomatically after the ventriculostomy and was the only patient without an anterior/inferior third ventricular flow void on postoperative MR. The ventriculogram in this patient was consistent with a patent ventriculostomy but impaired CSF resorptive capacity [17]. Retrospectively, it would appear that this patient probably had two abnormalities preoperatively, a collicular plate mass plus an extraventricular CSF obstruction. We speculate that her symptoms were primarily due to the latter because, despite successful "bypassing" of the ventricular obstructive lesion (the collicular plate mass), she did not improve clinically. In a sense, the MR and ventriculogram findings concur. Delayed ventricular emptying on the ventriculogram would indicate sluggish CSF flow through the ventriculostomy, which in turn was manifested on MR by a lack of an anterior/inferior third ventricular flow void (Fig. 5).

Discussion

The CSF flow void has been described as loss of signal intensity in moving CSF in comparison with relatively stationary CSF (such as that in the lateral ventricles) from both dephasing and washout of the moving spins [9, 10]. This is due to the cardiac-driven pulsatile nature of CSF circulation and is most pronounced in areas of the ventricular system in which CSF velocity and turbulence are greatest [9, 13–15]. In individuals with unaltered CSF circulation these are the foramen of Monro, aqueduct of Sylvius, and foramen of

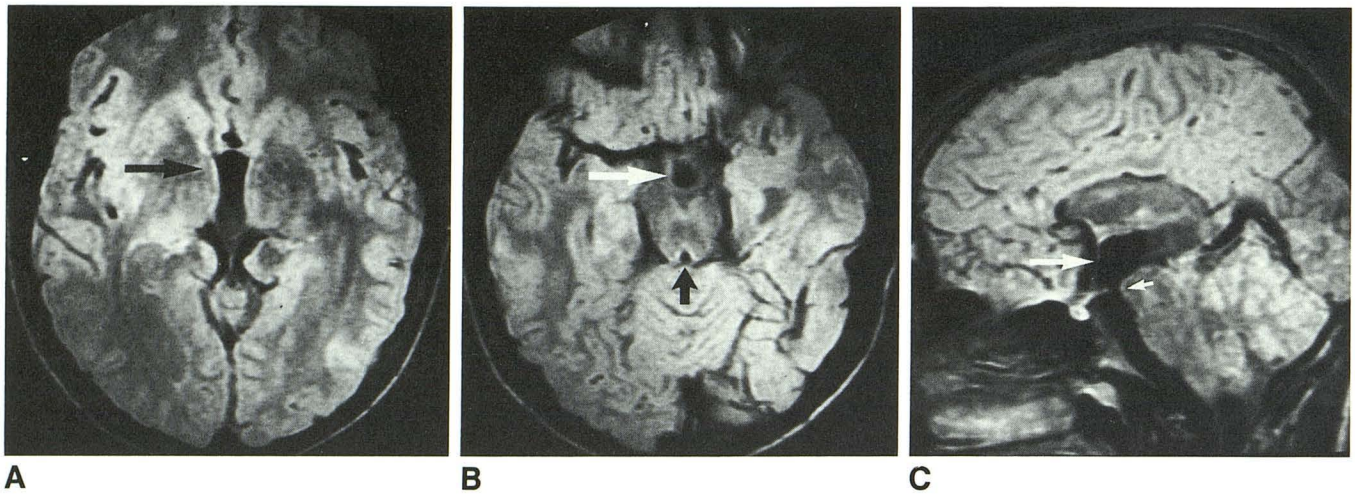

Fig. 4.—Case 11: MR 4 months after third ventriculostomy in patient with pineal germinoma.

A, Axial first-echo image (2000/30,80/2) without motion compensation shows prominent flow void in third ventricle (*arrow*) indicating functioning ventriculostomy.

B, Same pulse sequence, two sections lower. Flow void in aqueduct (*black arrow*) indicates that it is patent. Flow void is present also in inferior aspect of third ventricle (*white arrow*).

C, Sagittal first-echo image (2000/30,80/2) without motion compensation. Note paucity of flow void in posterior compared with anterior (*large arrow*) third ventricle (same finding is present on axial image, *A*). Ventriculostomy (*small arrow*). This is not a perfectly midline sagittal section, and as a result the prominent aqueductal flow void is not visualized, as in *B*.

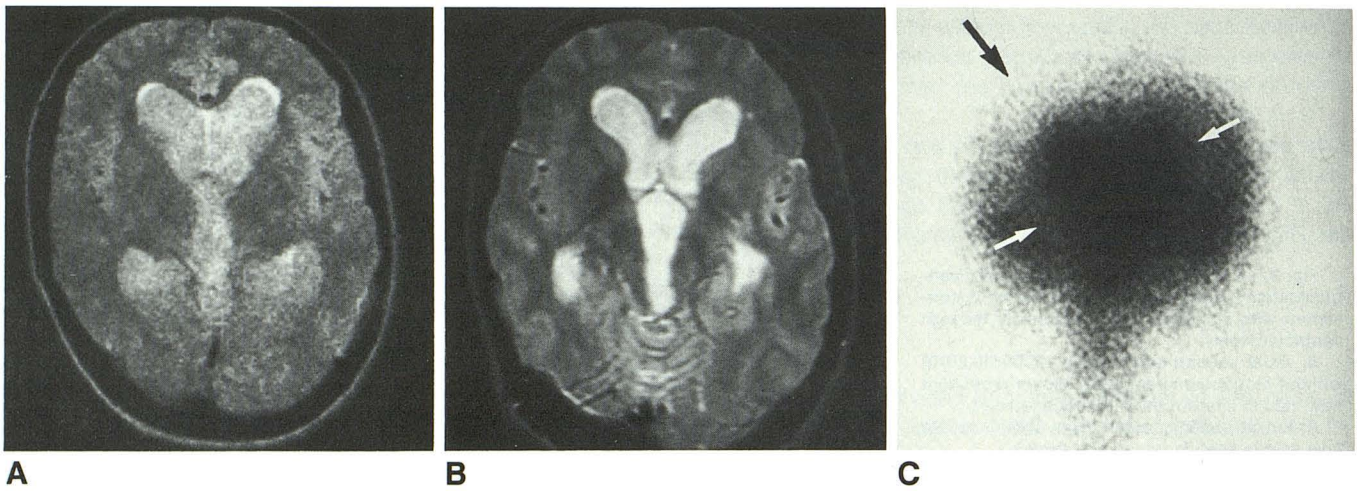

Fig. 5.—Case 20: Imaging studies in patient with impaired CSF resorption.

A, Axial image (1700/100/2) without motion compensation on 0.5-T imager from an outside institution. Preoperative MR shows no third ventricular CSF flow void. (Courtesy of J. J. Golnick, Papillon, NE.)

B, Axial second-echo image (2000/20,80/2) without motion compensation 4 months after ventriculostomy. Lack of third ventricular flow void is unchanged from preoperative study.

C, Anteroposterior ventriculogram at 24 hr 10 days after surgery. Delayed ventricular clearing with considerable retained intraventricular activity (*white arrows*). Abnormal distribution of isotope over convexities with paucity of activity over right convexity (*black arrow*).

Magendie, where CSF is propelled from a larger through a smaller channel. The presence of a CSF flow void has been suggested as a useful indicator of patency of that portion of the ventricular pathway, and its absence at a site where it is normally found may indicate obstruction [11].

When a third ventriculostomy is performed, a new pathway for CSF flow is created from the foramen of Monro, through the anterior third ventricle and the ventriculostomy, and into the pontine and interpeduncular cisterns. This altered pathway of CSF flow should also be demarcated by a CSF flow void, and because of this, MR might be preferable to ventriculography to document ventriculostomy patency. Changes between the pre- and postoperative MR appearances in cases 1, 7, 8, and 13–16 support the former contention. Preoperatively, no flow void was present at any of the five sites evaluated. Postoperative CSF flow void precisely outlined the expected route of CSF flow through the ventriculostomy, while persistent absence of flow void in the fourth ventricle or aqueduct (when visible) indicated continued obstruction to this route of CSF egress (Fig. 6).

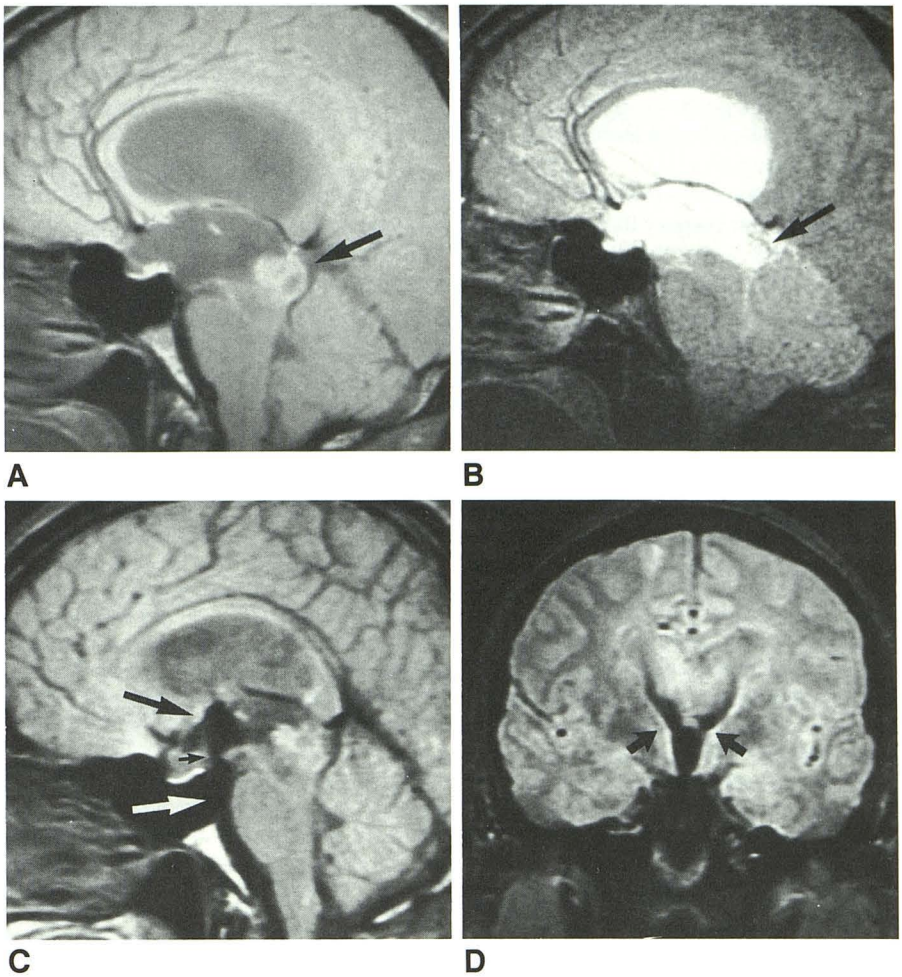

Fig. 6.—Case 1: Pre- and serial postoperative MR studies.

***A* and *B*, Sagittal first-echo (*A*) and second-echo (*B*) images (2000/20,100/2) without motion compensation 5 days before third ventriculostomy. Ventricular dilatation is due to aqueductal obstruction by pineal tumor (*arrows*). No flow void in third or fourth ventricle. Aqueduct not visible. Note ventricular anatomy is seen more clearly on first- than on second-echo image.**

***C*, Sagittal first-echo image (2000/30,80/2) without motion compensation 6 months after ventriculostomy. Flow void in anterior third ventricle (*large black arrow*) is continuous with flow void in pontine and interpeduncular cisterns (*white arrow*). Ventriculostomy defect in floor of third ventricle (*small black arrow*). Flow void is present in foramen of Magendie.**

***D*, Coronal second-echo image (2000/20,70/2) without motion compensation 19 months after ventriculostomy. Flow void in both foramina of Monro (*arrows*) and third ventricle indicates long-term ventriculostomy patency.**

As illustrated in Table 1, there is excellent correlation between postsurgical outcome, ventriculography, and postoperative MR as to evidence of ventriculostomy function. The postsurgical outcome and ventriculogram data indicate that functional decompression of the ventricular system through the ventriculostomy was achieved in cases 1–19. One hundred percent of these patients had a CSF flow void in the anterior and inferior third ventricle; this would appear to be the most reliable MR indicator of adequate third ventriculostomy function. Interestingly, this pattern differs from that found in individuals with CSF egress through the aqueduct. In a group of 35 normal volunteers, Mark et al. [14] found that the flow void in the third ventricle was most prominent posteriorly, at the junction of the third ventricle and aqueduct. After a ventriculostomy, flow is directed through the floor of the anterior third ventricle, accounting for the shift of maximum third ventricular flow from posterior to anterior. In cases 1–19, flow void in the foramen of Monro and pontine/interpeduncular cisterns was seen in 74% and 95%, respectively. The presence of a flow void in these locations would appear to be supporting evidence of a functioning ventriculostomy, but their absence would not exclude adequate function. A flow void in the pontine cistern in the absence of a flow void in the anterior third ventricle does not imply ventriculostomy patency, as basilar artery pulsations may create a flow void in this region in persons with unaltered CSF circulation [14]. However, a prominent pontine cistern flow void in direct continuity with that in the third ventricle is most likely due at least in part to CSF flow through the third ventriculostomy (Figs. 2C, 4C, and 6C).

In patients with impaired CSF resorption (case 20), treatment with an external ventricular drain is preferable to a ventriculostomy because the latter is dependent for function on unimpeded CSF flow in the basal and hemispheric subarachnoid spaces and adequate resorptive capacity of the arachnoid villi. The preoperative MR findings in case 20 were essentially the same as those in the patients with preoperative MR who did improve (cases 1, 7, 8, and 13–16), that is, who had no evidence of ventricular CSF flow. Therefore, these preliminary results, while based on only a few cases, would seem to indicate that MR may not offer information that would permit accurate preoperative identification of patients who would respond to ventriculostomy. During the review process it was pointed out that a preoperative radionuclide study via a lumbar route should be helpful in this regard. If ascent of activity over the convexities was normal, then one could exclude an extraventricular obstruction to CSF flow and proceed confidently to stereotactic ventriculostomy. If CSF flow

over the convexities was abnormal, however, a shunt would be the treatment of choice. This approach would be helpful in those patients without acute obstructive hydrocephalus (i.e., elective ventriculostomy for chronic shunt failure), as a lumbar puncture would be contraindicated in patients with obstructive hydrocephalus.

In this report, there is an obvious discrepancy between the mean time after surgery that ventriculography was performed (3 days) and when the first MR study was performed (4 months). This is due to the partially retrospective nature of this study. Nevertheless, the validity of directly comparing the MR and ventriculographic findings is supported by the fact that in the four patients with more than one postoperative MR study, the flow-void patterns were not changed on serial MR studies.

Our current MR protocol for evaluating CSF circulatory dynamics before and after third ventriculostomy consists of axial and sagittal spin-echo pulse sequences without motion-compensation techniques. Ventricular CSF flow void is seen in all three orthogonal imaging planes, but is more conveniently displayed in a single image sagittally. Also, the continuity between the third ventricular and prepontine "jet" of dephased spins is displayed optimally in the sagittal plane. The disadvantage of imaging in the sagittal plane is that because CSF motion-compensation techniques are not used, phase-shift artifacts from CSF pulsation can be distracting. Therefore, we also use an axial spin-echo sequence, which offers the following advantages: greater familiarity with axial anatomy; less prominent phase-shift artifacts across the ventricular system; and readily identifiable areas of flow void, albeit on different images. We use an asymmetric second echo (TE = 30, 80) to avoid even-echo rephasing at the second echo, which would diminish the degree of flowing CSF signal loss [10, 15, 16]. Both echoes were evaluated in this partially retrospective study because some patients were imaged with a symmetric and some with an asymmetric echo train. Signal loss due to flowing CSF should be more pronounced at the first echo with the former technique and at the second echo with the latter [16]. Alternatively, spin-echo sequences could be replaced with gradient-refocused pulse sequences, preferably with a short TR/TE and large nutation angle [18]. These pulse sequences may be more sensitive to CSF flow; on the other hand, they may be unsatisfactory in the inferior third ventricle due to artifacts from magnetic-susceptibility effects at the skull base. This approach is currently being evaluated. It is important to emphasize that motion-compensation techniques (gradient moment nulling and/or cardiac gating), which are routinely used in nearly all long TR/TE neuroimaging pulse sequences, should not be used when evaluating CSF flow. Although the resulting phase-shift artifacts may be distracting without motion compensation, information about CSF flow may be lost when techniques are used [19].

We conclude that a vigorous pulsatile egress of CSF through the third ventriculostomy is necessary to visualize an anterior/inferior third ventricular flow void, which in turn is indicative of a functioning third ventriculostomy. The presence of this finding on a postoperative MR examination should be sufficient to document third ventriculostomy patency. The absence of this finding may be due to a nonpatent ventriculostomy, or, as we speculated in case 20, an extraventricular CSF obstruction. In this situation, the more invasive ventriculogram may be obtained to differentiate between these latter two possibilities. In addition, with MR, both CSF circulatory dynamics and the status of an obstructing lesion may be evaluated concurrently by the same imaging study. The issue of long-term third ventriculostomy patency is ideally and noninvasively assessed by serial MR studies (Fig. 6).

ACKNOWLEDGMENTS

We thank Brenda L. Maxwell for typing the manuscript and O. Wayne Houser, Hillier L. Baker, Jr., and Manuel L. Brown for critical review.

REFERENCES

1. Kelly PJ, Goerss S, Kall MS, Kispert DB. Computed tomography-based stereotactic third ventriculostomy: technical note. *Neurosurgery* **1986**; 18:791–794
2. Mixter WJ. Ventriculoscopy and puncture of the floor of the third ventricle. *Bost Med Surg J* **1923**;188:277–278
3. Vries JK. An endoscopic technique for third ventriculostomy. *Surg Neurol* **1978**;9:165–168
4. Hoffman JH, Harwood-Nash D, Gilday DL. Percutaneous third ventriculostomy in the management of noncommunicating hydrocephalus. *Neurosurgery* **1980**;7:313–321
5. Sayers MP, Kosnik EJ. Percutaneous third ventriculostomy: experience and technique. *Childs Nerv Syst* **1976**;2:24–30
6. Mealey J Jr, Gilmor RL, Bubb MP. The prognosis of hydrocephalus overt at birth. *J Neurosurg* **1973**;39:348–355
7. Kelly PJ, Kall BA, Goerss S, Cascino TL. Results of computer-assisted stereotactic laser resection of deep-seated intracranial lesions. *Mayo Clin Proc* **1986**;61:20–27
8. Apuzzo MLJ, Chandrasoma PT, Zelman V, Giannotta SL, Weiss MH. Computed tomographic guidance stereotaxis in the management of lesions of the third ventricular region. *Neurosurgery* **1984**;15:502–508
9. Sherman JL, Citrin CM. Magnetic resonance demonstration of normal CSF flow. *AJNR* **1986**;7:3–6
10. Bradley WG, Kortman KE, Burgoyne DE. Flowing cerebrospinal fluid in normal and hydrocephalic states: appearance on MR images. *Radiology* **1986**;159:611–616
11. Sherman JL, Citrin CM, Bowen BJ, Gangarosa RE. MR demonstration of altered cerebrospinal fluid flow by obstructive lesions. *AJNR* **1986**;7: 571–579
12. Sherman JL, Citrin CM, Gangarosa RE, Bowen BJ. The MR appearance of CSF flow in patients with ventriculomegaly. *AJNR* **1986**;7:1025–1031
13. Citrin CM, Sherman JL, Gangarosa RE, Scanlon D. Physiology of the CSF flow-void sign: modification by cardiac gating. *AJNR* **1986**;7:1021–1024
14. Mark AS, Feinberg DA, Brant-Zawadzki MN. Changes in size and magnetic resonance signal intensity of the cerebral CSF spaces during the cardiac cycle as studied by gated, high-resolution magnetic resonance imaging. *Invest Radiol* **1987**;22:290–297
15. Rubin JB, Wright A, Enzmann DR. Lumbar spine: motion compensation for cerebrospinal fluid on MR imaging. *Radiology* **1988**;166:225–231
16. Malko JA, Hoffman JC Jr, McClees EC, Davis PC, Braun IF. A phantom study of intracranial CSF signal loss due to pulsatile motion. *AJNR* **1988**;9:83–89
17. Schlesinger EB, Bailey S, Groover R. Patterns of central nervous system pathology as depicted by isotope encephalography. *Trans Am Neurol Assoc* **1965**;90:292–294
18. Needell WM, Maravilla KR. MR flow imaging in vascular malformations using gradient recalled acquisition. *AJNR* **1988**;9:637–642
19. Quencer RM, Hinks SR, Pattany PH. Improved MR imaging of the brain by using compensating gradients to suppress motion-induced artifacts. *AJNR* **1988**;9:431–438