AJNR

This information is current as of October 11, 2024.

Wallerian degeneration and inflammation in rat peripheral nerve detected by in vivo MR imaging.

D S Titelbaum, J L Frazier, R I Grossman, P M Joseph, L T Yu, E A Kassab, W F Hickey, D LaRossa and M J Brown

AJNR Am J Neuroradiol 1989, 10 (4) 741-746
http://www.ajnr.org/content/10/4/741

Wallerian Degeneration and Inflammation in Rat Peripheral Nerve Detected by in Vivo MR Imaging

David S. Titelbaum[1]
Joel L. Frazier[2]
Robert I. Grossman[1]
Peter M. Joseph[1]
Leonard T. Yu[2]
Eleanor A. Kassab[1]
William F. Hickey[3]
Don LaRossa[2]
Mark J. Brown[4]

To investigate the role of MR imaging in wallerian degeneration, a series of animal models of increasingly complex peripheral nerve injury were studied by in vivo MR. Proximal tibial nerves in brown Norway rats were either crushed, transected (neurotomy), or transected and grafted with Lewis rat (allograft) or brown Norway (isograft) donor nerves. The nerves distal to the site of injury were imaged at intervals of 0–54 days after surgery. Subsequent histologic analysis was obtained and correlated with MR findings. Crush injury, neurotomy, and nerve grafting all resulted in high signal intensity along the course of the nerve observed on long TR/TE sequences, corresponding to edema and myelin breakdown from wallerian degeneration. The abnormal signal intensity resolved by 30 days after crush injury and by 45–54 days after neurotomy, when the active changes of wallerian degeneration had subsided. These changes were not seen in sham-operated rats.

Our findings suggest that MR is capable of identifying traumatic neuropathy in a peripheral nerve undergoing active wallerian degeneration. The severity of injury may be reflected by the corresponding duration of signal abnormality. With the present methods, MR did not distinguish inflammatory from simple posttraumatic neuropathy.

Wallerian degeneration is the axonal degeneration and loss of myelin that occurs when an axon is separated from its cell body. In vitro studies have shown an increased T2 relaxation time and increased water content in peripheral nerves undergoing wallerian degeneration [1]. We developed a series of models of peripheral nerve injury with the use of the rat tibial nerve to determine whether injured nerves can be identified in vivo. The tibial nerve was selected because its longitudinal course was favorable for surgical manipulation and imaging. Because of current interest in peripheral nerve grafting, we also sought to determine whether nerve rejection could be distinguished from simple wallerian degeneration by MR imaging.

Materials and Methods

Seventeen brown Norway rats (weight range, 275–325 g) were divided into five groups (Table 1). Crush injury consisted of the blunt compression of the proximal tibial nerve by using a standard crush of 5 sec with a #5 forceps, thereby maintaining epineurial continuity. Neurotomy was accomplished by the transection and partial resection of the proximal 3 mm of the tibial nerve.

The nerve graft procedure for both allograft and isograft groups is schematically illustrated in Figure 1. To place the nerve grafts beneath the posterior muscle compartment, a tendon retriever was tunneled beneath the posterior compartment from an incision just above the ankle to an incision in the mid thigh. The nerve graft was then retracted from the thigh incision and delivered distally into the ankle incision. Donor sciatic-tibial nerves of approximately 4 cm in length were then microsurgically anastomosed with 10-0 nylon suture to the recipient nerve at proximal and distal transection sites located just below the sciatic nerve trifurcation and just above the ankle. One centimeter of the remaining native nerve was resected just below the proximal and just above the distal anastomosis sites to prevent regeneration along the

Received October 6, 1988; revision requested November 30, 1988; revision received December 20, 1988; accepted January 5, 1989.

Presented at the annual meeting of the American Society of Neuroradiology, Chicago, May 1988.

This work was supported in part by U.S. Public Health Service grant NS08075 and by the Muscular Dystrophy Association.

[1] Department of Radiology, Hospital of the University of Pennsylvania, 3400 Spruce St., Philadelphia, PA 19104. Address reprint requests to R. I. Grossman.

[2] Department of Surgery, Hospital of the University of Pennsylvania, Philadelphia, PA 19104.

[3] Department of Pathology, Division of Neuropathology, Washington University School of Medicine, 660 S. Euclid Ave., St. Louis, MO 63110.

[4] Department of Neurology, Hospital of the University of Pennsylvania, Philadelphia, PA 19104.

AJNR **10:741–746, July/August 1989**
0195–6108/89/1004–0741
© American Society of Neuroradiology

TABLE 1: Types of Nerve Injury Induced in Brown Norway Rats Studied by MR

Group	No. of Rats	Postsurgery Imaging Times (days)
Crush	2	0, 15, 30
Neurotomy	2	0, 4, 8, 15, 22, 30, 37, 45, 54
Isograft	5	0, 15 ($n = 3$) 0, 4, 8, 15, 22, 30 ($n = 2$)
Allograft	5	0, 15 ($n = 3$) 0, 4, 8, 15, 22, 30 ($n = 2$)
Sham operation	3	0, 15 ($n = 1$) 0, 4, 8, 15, 22, 30 ($n = 2$)

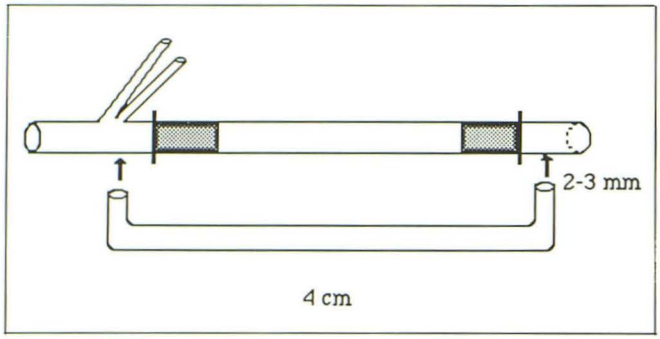

Fig. 1.—Grafting procedure. Schematic of grafting procedure shows transection sites (*vertical bars*) just below sciatic trifurcation (*left arrow*) and just above ankle (*right arrow*). Nerve grafts measuring 4 cm in length and 2–3 mm in diameter are anastomosed to transection sites. Approximately 1 cm of native nerve is resected adjacent to each transection site (*shaded areas*).

native nerve. Allograft recipients received grafts from major histocompatibility complex-incompatible donors (Lewis rats); isograft recipients received grafts from genetically inbred donors (brown Norway rats), thereby serving as a control for rejection.

The sham operation involved only nerve mobilization without nerve transection or crush, and served as a surgical control for the grafting procedure. Healing of the wound was satisfactory in all animals.

MR was performed at varying time intervals of 0–54 days after the procedure (see Table 1). By using a 1.9-T 31-cm-bore research scanner, rats were imaged in the prone position with a 5-cm-diameter cylindrical coil centered at the popliteal fossa. Sagittal and axial spin-echo short TR, 400/15 (TR/TE), and long TR, 2000/95, sequences were performed at each imaging session using the spin-echo technique, two excitations, 128 × 128 matrix, and either single or multislice acquisitions. Sagittal images were obtained with a 3.3-cm field of view (FOV) and 2.5-cm slice thickness, and axial images with a 2.5-cm FOV and 3-mm thickness. Average pixel length was 0.3 mm, allowing visualization of the nerve, which is 2–3 mm in diameter.

In the untraumatized leg, the normal tibial nerve cannot be identified (Fig. 2A). To demonstrate the course of the native nerve, we sutured 0.038-French tubing along the entire course of the nerve (Fig. 2B) and then imaged the tube filled with both air and 2 mmol/l copper sulfate solution, using a 400/20 sequence (Fig. 2C).

After sacrifice, nerves were either formalin-fixed and paraffin-embedded or glutaraldehyde-fixed and plastic-embedded, stained with either hematoxylin and eosin or trichrome, and viewed with light microscopy. Pathologic specimens were correlated with MR findings.

Results

Normal Nerves

The sciatic nerve trifurcates just above the popliteal fossa into the tibial nerve, the longest branch, and the smaller peroneal and sural nerves. The tibial nerve passes through the popliteal fossa, along the anterior aspect of a large fat pad. The nerve then runs down the leg deep to the lateral third of the posterior muscle compartment.

In the untraumatized leg, the normal nerves were not identified, except for a linear high-signal structure occasionally seen in the region of the popliteal fossa, possibly representing epineurial fat.

Histologically, plastic-embedded sections allowed the axons and their surrounding myelin sheaths to be well seen (Fig. 2D) within the endoneurium without significant adjacent cellularity.

The imaging and pathologic results of the five operated animal groups are summarized in Table 2.

Nerve Trauma

Crushed nerves.—Crush injury–related high-signal changes peaked at day 15 (Fig. 3A), appeared less prominent compared with the signal change seen in transected nerves, and resolved by 30 days (Fig. 3B). Pathologic examination at 30 days showed myelin debris adjacent to normal-appearing axons and a rim of subperineurial endoneurial edema (Fig. 3C).

Transected nerves.—Neurotomy rats showed a high-signal abnormality along the course of the tibial nerve, similar in appearance to the abnormality seen in grafted nerves. The high-signal abnormality reached a maximum around day 21 (Fig. 4A) and returned to normal by 45–54 days (Fig. 4B), when a quiescent degenerated nerve was seen at pathology (Fig. 4C). Neuroma formation was also present at the transection site.

Grafted nerves.—Both allografts and isografts showed indistinguishable high signal intensity on long TR sequences along the course of the tibial nerve beginning 4–8 days after grafting and continuing to at least day 30 (our last imaging day) (Figs. 5A and 5B). No appreciable signal change was seen on the short TR sequence. Pathologically, allografts and isografts showed axonal degeneration, demyelination, edema, and extensive Schwann cell proliferation. Allografts were distinguished by additional intense inflammatory reaction (Figs. 5C and 5D).

Sham injuries showed minimal early changes, but were normal on MR by day 15 (Fig. 6A); normal nerves were seen at pathology (Fig. 6B).

Discussion

Simplified, our results show that peripheral nerves demonstrate high signal intensity on long TR/TE sequences, corresponding to pathologic changes of wallerian degeneration. The signal abnormality of the injured nerve appears to persist longer after transection than after crush injury. It is our

Fig. 2.—Normal tibial nerve identification.

***A*, Sagittal MR image (2000/95) through lateral third of leg from just above knee to mid calf. Tibial epiphysis (*arrow*). (Rat is lying prone so that anterior surface of leg is at lower portion of image.) No nerve can be identified.**

***B*, Intraoperative photograph shows 0.038-French tubing sutured along course of native sciatic-tibial nerve (*arrows*).**

***C*, Sagittal MR images (400/15) show air-filled (*top*) and 2 mmol/l copper sulfate solution–filled tube (*bottom*) corresponding to course of normal tibial nerve. Note nerve is adjacent to fat pad (*arrow*) at inferior popliteal fossa, and then passes distally to lie within calf.**

***D*, Plastic-embedded trichrome-stained histologic cross section through proximal tibial nerve endoneurium shows lucent axons surrounded by black halos of myelin within endoneurium. Note that axons virtually fill endoneurium without significant cellular component. Perineurium (*thick arrow*) lies at periphery. Scattered blood vessels (*thin arrows*) run through endoneurium.**

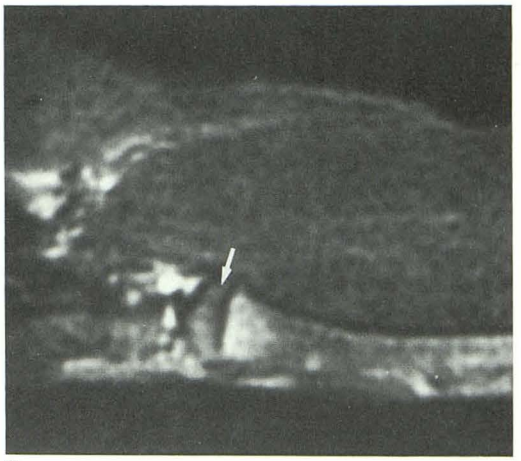

A

B

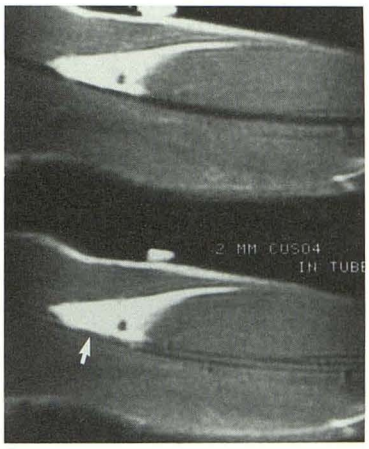

C

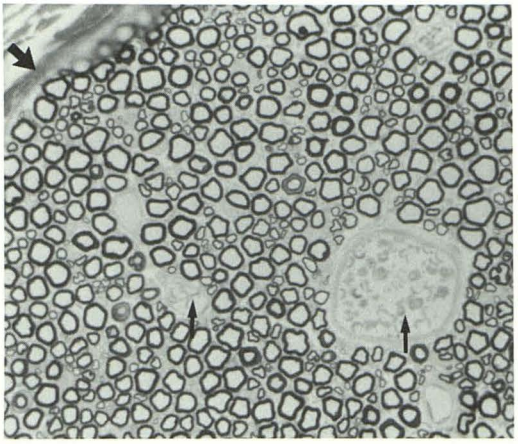

D

TABLE 2: Sequential MR Findings in Brown Norway Rats After Induced Nerve Injury

Group	Nerve Intensity			Histopathology
	15 Days	30 Days	45–54 Days[a]	
Crush	High	Isointense	–	WD
Neurotomy	High	High	Isointense	WD, SCP
Isograft	High	High	–	WD, SCP
Allograft	High	High	–	WD, SCP, inflammation
Sham operation	Isointense[b]	Isointense	–	Normal

Note.—WD = Wallerian degeneration; SCP = Schwann cell proliferation.
[a] Only rats in the neurotomy group were studied after 30 days.
[b] Relative to muscle.

hypothesis that the observed findings on MR are due, in large part, to increased water content from increased endoneurial cellularity that ensues from traumatic injury.

The response of peripheral nerve to traumatic injury has been well characterized. Vasogenic endoneurial edema accumulation begins within 24 hr after axonal separation from its cell body, caused by either transection or crush injury [2]. Subsequent breakdown begins at approximately 36 hr [3]. By 6 days, myelin debris and possibly bare axons stimulate marked Schwann cell proliferation and phagocytic activity [3, 4]. Schwann cell mitoses form longitudinal columns, directing growth of regenerating axons from the proximal stump. Crush injury retains the greatest degree of neural architectural continuity across the point of injury, thus allowing the greatest degree of successfully directed axonal sprouting from the stump, along the course of the disrupted nerve [3, 4]. Complete transection causes greater architectural disruption, so that some regenerating axons are misrouted, failing to regain their former terminations, and instead form small neuromas around the transection site [4, 5]. Large gaps between the transected ends, or resection of a portion of nerve, provide greater impediment to nerve regeneration.

In vitro proton MR spectroscopic studies of the rat sciatic nerve by Jolesz et al. [1] demonstrated increased T1 and T2 relaxation times and increased water content 15 days after nerve transection. The relaxation times increased by nearly a factor of 2, corresponding to a nearly 25% increase in nerve water content, and the authors predicted that a peripheral nerve undergoing wallerian degeneration should be detectable by in vivo MR imaging. Our findings confirm this prediction.

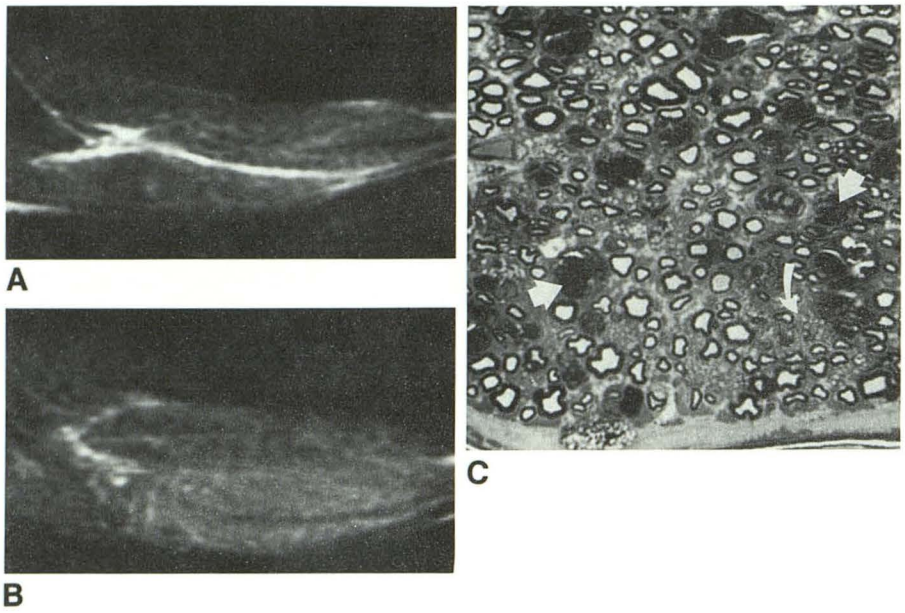

Fig. 3.—Crush-injury rats.
***A*, Sagittal MR image (2000/95) 15 days after crush shows high signal along course of tibial nerve.**
***B*, Sagittal image at 30 days shows resolution of high signal.**
***C*, Plastic-embedded trichrome-stained cross section below site of crush at 30 days shows myelin debris (*straight arrows*) interspersed between normal-appearing axons—evidence of prior demyelination. Note normal nonmyelinated pain and temperature axons (*curved arrow*).**

Fig. 4.—Neurotomy-operated rats.
***A*, Sagittal MR image (2000/95) 22 days after neurotomy procedure shows high signal intensity along course of tibial nerve.**
***B*, Sagittal MR image on day 45 reveals resolution of high signal.**
***C*, Plastic-embedded trichrome-stained cross section of tibial nerve after sacrifice on day 45 shows absence of axons, scattered myelin debris in endoneurium (*long arrows*), mild endoneurial cellularity, and some endoneurial edema just beneath perineurium (*short arrows*).**

In the current study, the observed increase in signal on long TR/long TE sequences suggests increased T2 relaxation time in the injured nerve, presumably representing increased water content. Studies by Vasilescu et al. [6] suggest that water compartmentalization in peripheral nerves may be separable by mathematical analysis of spectroscopically determined T2 relaxation times. The source of increased neural water content may be extracellular due to vasogenic edema resulting from increased vascular permeability of the vasa nervorum [2]. On pathologic examination we observed a rim of subperineurial endoneurial edema in transected nerves. However, this rim of edema was also seen in crush-injured nerves at day 30 when the signal abnormality had resolved. Alternatively, increased intracellular water content may be responsible for the observed signal abnormality. Endoneurial Schwann cell proliferation was a constant finding, greater in transected than in crushed nerves, thus appearing to correlate with the degree and duration of signal abnormality.

These findings support our hypothesis that increased intracellular water from increased cellularity within the endoneurial compartment may be responsible for the observed signal changes occurring in traumatic neuropathy. The time course of signal change in crush-injured nerves also correlates well with autoradiographic thymidine-labeling studies, which have shown approximately 50–90% increases in Schwann cells within nerves 3–15 days after trauma [7]. This could be evaluated further by the techniques used by Vasilescu et al. [6].

Other changes occurring in wallerian degeneration include myelin glycoprotein breakdown, esterification of cholesterol, and breakdown of phospholipids and sphingomyelins [8–10]. These changes were not visually detectable on MR, but could

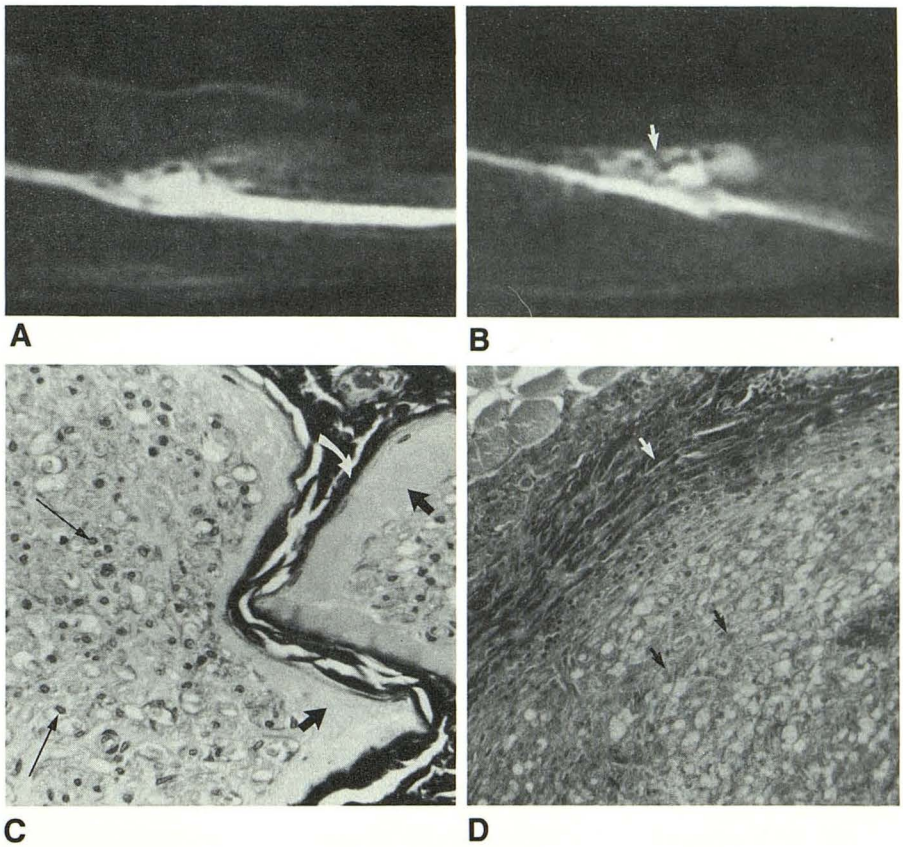

Fig. 5.—Allografted and isografted rats.

***A*, Sagittal MR image (2000/95) 22 days after isograft procedure shows high signal along nerve, similar to allografts.**

***B*, Sagittal MR image (2000/95) 22 days after allograft procedure shows high signal intensity along course of tibial nerve. Lymphadenopathy is presumed to be present in popliteal fossa (*arrow*), in region of fat pad.**

***C*, Paraffin section of isograft recipient sacrificed at 15 days shows absence of axons and myelin, extensive Schwann cell proliferation (*long black arrows*), and mild endoneurial edema (*short black arrows*) lying beneath mildly thickened perineurium (*white arrow*). Note absence of the marked perineurial inflammatory process seen in allograft specimen (*D*).**

***D*, Paraffin-embedded trichrome-stained pathologic cross section of tibial nerve from allograft recipient sacrificed at 15 days shows absence of axons and myelin, extensive Schwann cell proliferation within endoneurium (*black arrows*), and perineurial inflammation and collagen deposition (*white arrow*).**

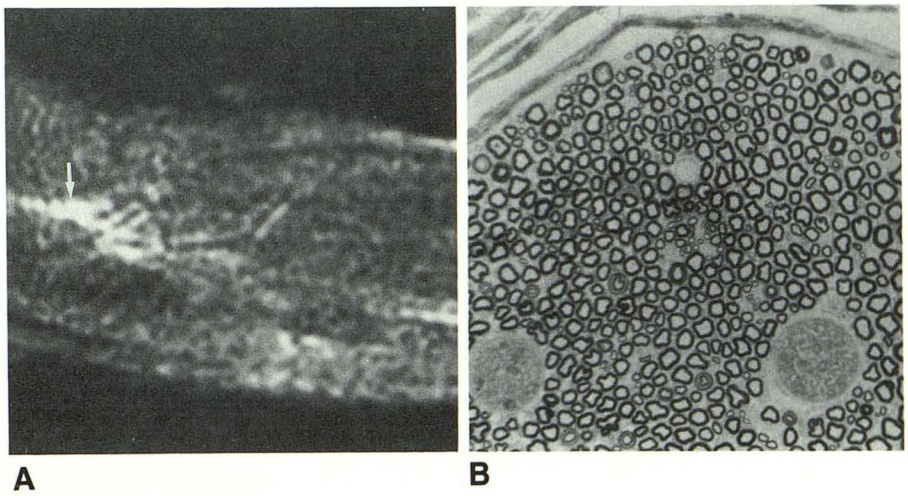

Fig. 6.—Sham-operated rats.

***A*, Sagittal MR image (2000/95) 15 days after sham operation shows no evidence of nerve signal abnormality. Thin, linear, high-signal structure (*arrow*) at popliteal fossa represents normal anatomy, possibly representing epineurial fat, and was seen prior to surgery (not shown).**

***B*, Plastic-embedded trichrome cross section of tibial nerve shows normally myelinated axons within endoneurium.**

be evaluated by spectroscopic or chemical-shift techniques [11].

The allograft rejection process is known to incite an epineurial and endoneurial inflammatory reaction producing mononuclear cellular infiltration and eventual perineurial and endoneurial scarring [12, 13]. The inflammatory reaction has been shown to peak around 8–15 days after grafting, and can be suppressed with cyclosporin A [14, 15]. Only minimal changes have been observed in isografts [14, 15]. Because allografts undergo rejection and wallerian degeneration, whereas isografts undergo only wallerian degeneration, it was anticipated that allografts would be distinguishable from isografts by MR imaging on the basis of increased water content in allografts. Despite definite pathologic differences, allografts and isografts appeared essentially indistinguishable on MR.

Although this study provides information regarding a fundamental neurophysiologic and neuropathologic process, the applicability in detecting wallerian degeneration in the CNS is uncertain. Physiologically, the rates of degeneration and cellular influx in the CNS are much slower than in the peripheral

nervous system [16]. In addition, in the CNS, clearing of myelin debris is slow [5], and axonal elongation does not occur beyond a few millimeters [3, 5].

In conclusion, traumatic peripheral neuropathy can be identified by MR and distinguished from normal on the basis of prolongation of T2 properties of the nerve. Transient injury may be followed to resolution of the T2 abnormality over time. The nature of the nerve abnormality cannot, at present, be subcategorized by origin on the basis of the high-signal abnormality.

ACKNOWLEDGMENTS

We thank Valerie Tsafos for manuscript preparation and Bruce Cairns for assistance in our initial pilot study.

REFERENCES

1. Jolesz FA, Polak JF, Ruenzel PW, Adams DF. Wallerian degeneration demonstrated by magnetic resonance: spectroscopic measurements on peripheral nerve. *Radiology* **1984**;152:85–87
2. Olsson Y. Vascular permeability in the peripheral nervous system. In: Dyck PJ, Thomas PK, Lambert EH, Bunge R, eds. *Peripheral neuropathy*, vol. 1, 2nd ed. Philadelphia: Saunders, **1984**:579–597
3. Dyck PJ, Karnes J, Lais A, Lofgren EP, Stevens JC. Pathologic alterations of the peripheral nervous system of humans. In: Dyck PJ, Thomas PK, Lambert EH, Bunge R, eds. *Peripheral neuropathy*, vol. 1, 2nd ed. Philadelphia: Saunders, **1984**:760–870
4. Thomas PK. Nerve injury. In: Bellairs R, Gray EG, eds. *Essays on the nervous system*. London: Oxford University Press, **1974**:44–70
5. Aguayo AJ, Bray GM. Cell interactions studied in the peripheral nerves of experimental animals. In: Dyck PJ, Thomas PK, Lambert EH, Bunge R, eds. *Peripheral neuropathy*, vol. 1, 2nd ed. Philadelphia: Saunders, **1984**: 360–377
6. Vasilescu V, Katona E, Simplaceanu V, Demco D. Water compartments in the myelinated nerve. III. Pulsed NMR results. *Experimentia* **1978**;34: 1443–1444
7. Friede RL, Johnstone MA. Responses of thymidine labelling of nuclei in gray matter and nerve following sciatic transection. *Acta Neuropathol* (Berl) **1967**;7:218–231
8. Johnson AC, McNabb AR, Rossiter RJ. Chemical studies of peripheral nerve during wallerian degeneration. 1. Lipids. *Biochem J* **1949**;45: 500–508
9. Mannell WA. Wallerian degeneration in the rat: a chemical study. *Can J Med Sci* **1952**;30:173–179
10. Wood JG, Dawson RMC. Lipid and protein changes in sciatic nerve during wallerian degeneration. *J Neurochem* **1974**;22:631–635
11. Listerud J, Axel L, Lenkinski RE. ^{1}H ultrathin phase encoded spectroscopy (HUPSPEC). Presented at the annual meeting of the Society of Magnetic Resonance in Medicine, San Francisco, August **1988**
12. Hirasawa Y, Tamai K, Katsumi Y, Sakakida K. Experimental study of nerve allografts: especially on the influence of histocompatibility in fresh nerve grafting. *Transplant Proc* **1984**;16:1694–1699
13. Mackinnon S, Hudson A, Falk R, Bilbao J, Kline D, Hunter D. Nerve allograft response: a quantitative immunological study. *Neurosurgery* **1982**;10:61–69
14. Yu LT, Hickey WF, Silvers WS, Larossa D, Rostami AM. Expression of class II antigens on peripheral nerve allografts (abstr). *Ann NY Acad Sci* **1988**;540:472–474
15. Yu LT, England J, Hickey WF, et al. Survival and function of peripheral nerve allografts after cessation of long term cyclosporin immunosuppression in rats. *Transplant Proc* **1989**;21:3178–3180
16. McCaman RE, Robins E. Quantitative biochemical studies of wallerian degeneration in the peripheral and central nervous systems—I. *J Neurochem* **1959**;5:18–31